

## Case Report

# Palmaris Profundus as the Cause of Carpal Tunnel Syndrome

Ahmadreza Afshar MD\*

This report presents a palmaris profundus tendon anomaly in the carpal tunnel. The case was a 19-year-old female who underwent carpal tunnel surgery. After dividing the transverse carpal ligament, the palmaris profundus tendon was discovered. The abnormal tendon was within the carpal tunnel, laying over the investing tissue of the median nerve, and inserted deeply into the palmar aponeurosis. A segment of the abnormal tendon was excised and the patient's symptoms resolved completely.

*Archives of Iranian Medicine, Volume 12, Number 4, 2009: 415 – 416.*

**Keywords:** Anatomic variation • carpal tunnel surgery • carpal tunnel syndrome • palmaris profundus tendon

### Introduction

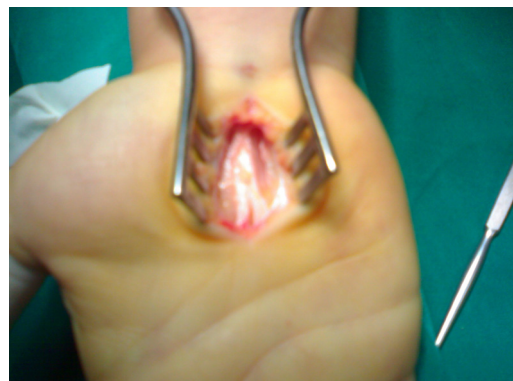Carpal tunnel syndrome (CTS) is the most peripheral compression neuropathy. Anatomic variations may be encountered during carpal tunnel surgery.<sup>1-3</sup> Variations have included aberrations of the median nerve itself and its branches, anomalies of muscles and tendons, and persistence of the median artery.<sup>1-12</sup> Anatomic variations are of interest to anatomists and surgeons. Some of the anatomic variations may be the cause of CTS.<sup>4-11</sup>

This report presents a rare palmaris profundus anomaly which produced CTS.

### Case Report

The patient was a 19-year-old female who had suffered from paresthesia, and numbness in the median nerve territory of the right hand for several years. Her symptoms were aggravated by exercise. Tinel's sign and Phalen test were positive. There was no evidence of thenar atrophy. The clinical diagnosis of CTS was confirmed by

electrophysiologic examination. Under local anesthesia, carpal tunnel release was performed through the classic interthenar incision. After dividing the transverse carpal ligament, an aberrant tendon was discovered on the anterior surface of the median nerve within its investing tissue (Figure 1). The tendon was inserted deeply into the palmar aponeurosis (Figure 2). There was no median artery. The median nerve was congested but otherwise normal. The palmaris longus tendon was palpable above the wrist crease. I believe there was a palmaris profundus tendon. Traction applied to the abnormal tendon caused excursion of the median nerve but no movement of the palmaris longus. The tendon detached distally and a 3-cm segment of the aberrant tendon excised. Further



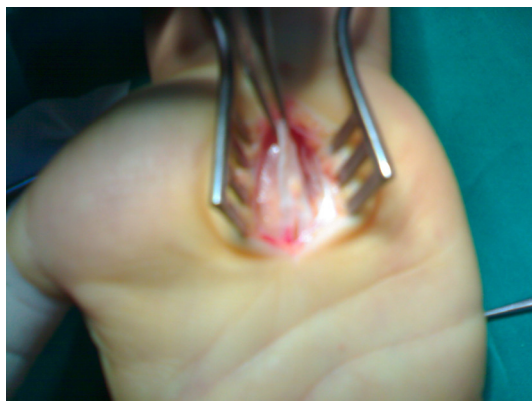
**Figure 1.** Palmaris profundus tendon within the carpal tunnel, lying over the investing tissue of the right median nerve.

**Author's affiliation:** \*Department of Orthopedics, Imam Khomeini Hospital, Modarress St., Ershad Blvd., Urmia, Iran.

**Corresponding author and reprints:** Ahmadreza Afshar MD, \*Department of Orthopedics, Imam Khomeini Hospital, Modarress St., Ershad Blvd., Urmia, Iran.  
Fax: +98-441-346-9939

E-mail: afshar\_ah@yahoo.com

Accepted for publication: 15 July 2008



**Figure 2.** The abnormal tendon was inserted deeply to the palmar aponeurosis.

exploration above the wrist was not indicated clinically and the origin of the palmaris profundus was not established. Histopathologically, the tendon was normal. After a few weeks the patient's symptoms resolved completely.

### Discussion

Facing anatomic anomalies during carpal tunnel surgery is not uncommon. In a study of 382 patients, Tountas et al. reported that 38 hands had an anomalous anatomy.<sup>2</sup>

The muscle anomalies within the carpal tunnel that may cause median nerve compression include variants of palmaris longus (duplicated, reversed, bifid reversed, and triplicated),<sup>4,10</sup> an accessory first lumbrical tendinous origin,<sup>5</sup> a flexor digitorum superficialis muscle to the middle finger<sup>11</sup> and palmaris profundus.<sup>6-9</sup> Palmaris profundus is a rare variation of muscle that has been found compressing the median nerve at the time of carpal tunnel surgery.<sup>1,6-9</sup>

Lindly and Kleinert found 30 (5.7%) anomalies in 526 CTS surgeries and there was one palmaris profundus anomaly in their experience.<sup>1</sup>

Palmaris profundus was first described in 1908.<sup>7</sup> Reimann et al. found one example in 530 cadaver arms.<sup>3</sup> It arises as a separate muscle in the middle third of the forearm, deep to the superficialis muscles. Its tendon courses deep into the carpal tunnel as a tenth tendon that may stray from a dorsal to palmar position within the canal, inserting into the palmar aponeurosis.<sup>1</sup>

The palmaris profundus is not a variation of the

palmaris longus. Several reports indicate that the palmaris longus coexists with palmaris profundus.<sup>6-9</sup>

A thorough knowledge of every possible anatomic variation is indispensable to surgeons who perform CTS surgery, as appreciation of the possibilities increases the safety of the procedure. An anatomic anomaly may be the etiology of the CTS and failure to address it results in the persistence to the symptoms and ends in failure to the treatment.<sup>9</sup> In this patient, resolution of symptoms after excision of the aberrant palmaris profundus tendon implicates that the palmaris profundus tendon was the cause of CTS.

### References

- 1 Lindley SG, Kleinert JM. Prevalence of anatomic variations encountered in elective carpal tunnel release. *J Hand Surg*. 2003; **28**: 849 – 855.
- 2 Tountas CP, MacDonald CJ, Bihrl DM. Carpal tunnel syndrome. A review of 507 patients. *Minn Med*. 1983; **66**: 479 – 482.
- 3 Reimann AF, Daseler ED, Anson BJ, Beaton LE. The palmaris longus muscle and tendon. A study of 1600 extremities. *Anat Rec*. 1944; **89**: 495 – 505.
- 4 Brones MF, Wilgis EFS. Anatomic variations of the palmaris longus, causing carpal tunnel syndrome. *Plast Reconstr Surg*. 1978; **62**: 798 – 800.
- 5 Butler B Jr, Bigley EC Jr. Aberrant index (first) lumbrical tendinous origin associated with carpal tunnel syndrome. A case report. *J Bone Joint Surg Am*. 1971; **53**: 160 – 162.
- 6 Dyreby JR, Engber WD. Palmaris profundus--rare anomalous muscle. *J Hand Surg [Am]*. 1982; **7**: 513 – 514.
- 7 Fatah MF. Palmaris profundus of Frohse and Fränkel in association with carpal tunnel syndrome. *J Hand Surg [Br]*. 1984; **9**: 142 – 144.
- 8 Floyd T, Burger RS, Sciaroni CA. Bilateral palmaris profundus causing bilateral carpal tunnel syndrome. *J Hand Surg [Am]*. 1990; **15**: 364 – 366.
- 9 Gwynne-Jones DP, Penny ID, Sewell SA, Hughes TH. Basal thumb metacarpal osteotomy for trapeziometacarpal osteoarthritis. *J Orthop Surg (Hong Kong)*. 2006; **14**: 58 – 63.
- 10 Sánchez- Lorenzo J, Cañada M, Díaz L, Sarasúa G. Compression of the median nerve by an anomalous palmaris longus tendon: a case report. *J Hand Surg [Am]*. 1996; **21**: 858 – 860.
- 11 Smith RJ. Anomalous muscle belly of the flexor digitorum superficialis causing carpal tunnel syndrome. Report of a case. *J Bone Joint Surg Am*. 1971; **53**: 1215 – 1216.
- 12 Lanz U. Anatomic variations of the median nerve in the carpal tunnel. *J Hand Surgery*. 1977; **2**: 23 – 31.