

# Concurrent Oncocytoma and Two Angiomyolipomas in a Diabetic Kidney: A Very Rare Condition

Fariba Abbasi<sup>1</sup>, Ata Abbasi<sup>2</sup>, Mansour Alizadeh<sup>3</sup>, and Parisa Modarresi<sup>2</sup>

<sup>1</sup> Department of Pathology, Solid Tumor Research Center, Urmia University of Medical Sciences, Urmia, Iran

<sup>2</sup> Department of Pathology, School of Medicine, Urmia University of Medical Sciences, Urmia, Iran

<sup>3</sup> Department of Urology, Urmia Urology and Nephrology Research Center, Urmia University of Medical Sciences, Urmia, Iran

Received: 14 Nov. 2015; Received in revised form: 10 Sep. 2016; Accepted: 14 Sep. 2016

**Abstract-** Angiomyolipoma (AML) and oncocytoma are uncommon benign neoplasms of the kidney which their simultaneous occurrence in the same kidney is extremely rare. This study reports a 60-year-old diabetic woman with the rare simultaneous occurrence of three renal masses. Histologic evaluation revealed two angiomyolipomas and one oncocytoma within the same kidney, in a background of histologic features of diabetic nephropathy. Renal angiomyolipoma and oncocytoma are uncommon neoplasms, and their simultaneous occurrence in the same kidney is extremely rare.

© 2017 Tehran University of Medical Sciences. All rights reserved.

*Acta Med Iran* 2017;55(7):470-473.

**Keywords:** Angiomyolipoma; Oncocytoma; Diabetic nephropathy; Simultaneous occurrence

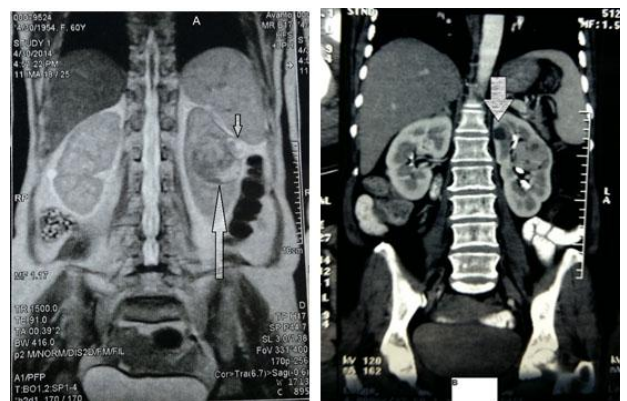
## Introduction

Renal angiomyolipoma (AML) and oncocytoma are uncommon neoplasms, and their simultaneous occurrence in the same kidney is extremely rare (1). Oncocytoma is a relatively large and benign epithelial tumor, originating from renal tubular cells, which accounts for almost 5% of surgically removed renal tumors in adults (2,3). They are usually asymptomatic and found accidentally (3,4). A minority of cases is symptomatic, and patients present with flank pain, hematuria or a palpable mass (3). Renal AMLs are also benign tumors, originating from embryonal cells which represent less than 3% of surgically resected kidney tumors (1,2). They are the most common mesenchymal tumors of the kidney. Clinically, fifty to seventy percent of AMLs occur sporadically, and the remaining are associated with tuberous sclerosis (TS) complex (2,5).

## Case Report

The patient was a 60-year-old diabetic woman who was admitted to Imam Khomeini medical hospital, Urmia Iran, with left flank pain. There was no history of seizure or mental retardation. Except for serum FBS and BS levels (170 mg/dl, 488 mg/dl, respectively), other laboratory routine tests were normal.

Ultrasonography revealed three masses in upper and middle poles of the left kidney. Computed tomography (CT) scan with contrast enhancement confirmed these findings and showed three masses in the left kidney measuring 5 and 1.5 cm in diameters at the middle pole and 1cm in diameter at the upper pole of the left kidney (Figure 1A and B).



**Figure 1.** A) CT scan: A larger tumor of 5 cm in diameter (large arrow) and a smaller one of 1 cm (small arrow) in middle portion. B) CT scan: A tumor of 1.5 cm in diameter (arrow) in the upper pole

## Macroscopic evaluation

The specimen received in pathology department consisted of kidney and adrenal gland. The kidney measured 11.5\*7\*4.5 cm. On cut surface, three masses

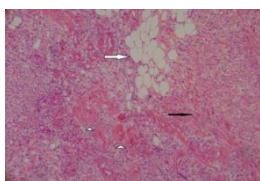
**Corresponding Author:** A. Abbasi

Department of Pathology, School of Medicine, Urmia University of Medical Sciences, Urmia, Iran  
Tel: +98 912 4397395, Fax: +98 44 33469939, E-mail address: aabbasi@alumnus.tums.ac.ir

were identified as follows: 2 well circumscribed soft yellowish-brown solid masses at middle and upper poles of the kidney measuring 6 and 1 cm in largest diameter, respectively and one well circumscribed fleshy brown mass measuring 1.5 cm in greatest diameter at the middle portion.

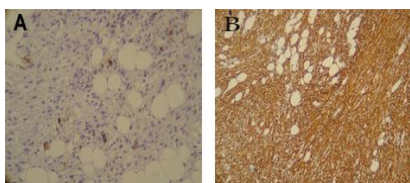
### Microscopic and immunohistochemical findings

Microscopic examination of the largest and smallest tumors exhibited mature adipose tissue, thick walled blood vessels and spindle shaped smooth muscle bundles (Figure 2).



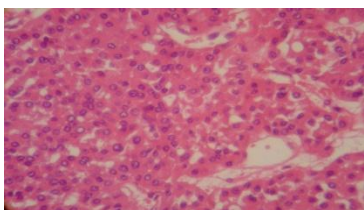
**Figure 2.** Angiomyolipoma: Admixture of mature fat (large arrow), spindle shaped smooth muscle fibers (small arrow), and thick walled blood vessels (arrowhead, H and E,  $\times 400$ ).

Focally, epithelioid cells with pale to eosinophilic cytoplasm, mildly pleomorphic and occasional hyperchromatic nuclei, but no mitotic figure were present. Necrosis was not identified. Immunohistochemical (IHC) staining showed reactivity for SMA and HMB45 (Figure 3a and b).



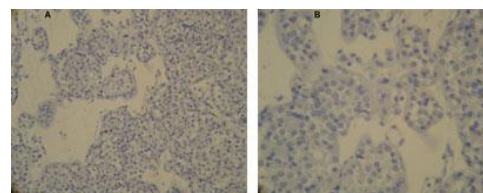
**Figure 3.** Angiomyolipoma: A): Scattered cells showing immunoreactivity with HMB-45 ( $\times 200$ ). B) Spindle shaped cells showing diffuse immunoreactivity with SMA ( $\times 400$ ).

These features were consistent with the diagnosis of AML. Sections from the third tumor showed neoplastic cells with abundant eosinophilic granular cytoplasm arranged in nests (Figure 4).



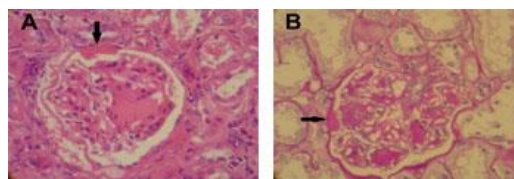
**Figure 4.** Oncocytoma: Tumoral cells with abundant eosinophilic granular cytoplasm and monomorphic nuclei (H and E,  $\times 400$ ).

No pleomorphism, mitosis or necrosis was seen. IHC staining result showed non-reactivity for CK20 and CK7 (Figure 5). These features were consistent with the diagnosis of oncocytoma.



**Figure 5.** Oncocytoma: A): Tumoral cells showing no immunoreactivity with CK7 ( $\times 400$ ). B): Tumoral cells showing no immunoreactivity with CK20 ( $\times 400$ ).

Sections from non-neoplastic areas showed diffuse mesangial hypercellularity and multiple nodules of mesangial matrix surrounded by a small rim of intact capillaries. The glomerular basement membrane was prominent. In some glomeruli, mesangiolysis with foam cells, loss of matrix and broken capillary loop were seen (Figure 6). In some areas, arteriolar hyalinization of both the afferent and the efferent arterioles and sclerotic glomeruli were also present.



**Figure 6.** Non- tumoral kidney showing features of diabetic nephropathy including hyaline globule deposition: A) Capsular drop (arrow, H and E,  $\times 400$ ), B) Capsular drop (arrow, PAS stain,  $\times 400$ ).

### Discussion

Renal AMLs are benign uncommon tumors (1). Microscopically, they are composed of a variable mixture of vascular, fat and muscular tissue. Angiomyolipomas are the most common mesenchymal tumors of the kidney and are derived from perivascular epithelioid cells which are mostly positive for IHC marker HMB45 (6). As previously mentioned, these tumors can be associated with tuberous sclerosis (TS)-an autosomal dominant disorder characterized by seizure, mental retardation, skin lesions and hamartomatous lesions of other organs (1) -but they are usually sporadic, large, single and unilateral. Clinical features of the tumor differ depending on the presence or absence of TS. In TS patients, AMLs are asymptomatic and found in younger age, but in sporadic cases, they tend to be symptomatic and present with flank pain, hematuria or

mass and are seen in older age compared to TS patients (5). Rarely, AMLs are seen in association with Von-Hippel Lindau disease, Von Recklinghausen syndrome, and polycystic kidney disease (1).

Renal oncocytomas are also benign tumors which usually occur in men as a single and unilateral mass (7). Microscopic characteristics of oncocytomas are the presence of large cells with dense eosinophilic granular cytoplasm and round uniform nuclei. The granularity of the cytoplasm is due to the presence of abundant mitochondria (7).

Although the simultaneous occurrence of renal oncocytoma and renal cell carcinoma within the same kidney is well recognized (8,9), the co-existence of AML and oncocytoma is very rare (1,10,11). In previous studies of concurrent AML with other kidney neoplasms, the average size of the tumor was about 0.5 cm in sporadic and about 3 cm in complex settings (e.g., tuberous sclerosis patients) (11) with mean age of 53 and 59 years, respectively (11). Our patient was a 60-year-old woman with two AMLs measuring 6 and 1 cm in greatest dimensions. Another important point is to distinguish atypical AML (including epithelioid and oncocytoma like variants) from oncocytomas (12,13). They usually have some similar morphologic features and can cause misdiagnosis. But epithelioid or oncocytoma like AMLs are positive for HMB 45 marker in IHC staining, but oncocytomas are not. In our study, the AMLs were both positive, and the oncocytoma was negative for HMB45 in IHC staining.

In this study, we reported two AMLs in one kidney, but the case was considered as sporadic form of angiomyolipoma because no signs or symptoms of tuberous sclerosis were found in our patient. Multiple AMLs are one of the signs of TS syndrome, and although we found no evidence of TS in our patient, it is recommended to retrospectively exclude TS in patients with multiple AMLs (7).

The most interesting aspect of our report is simultaneous occurrence of three masses, two AMLs and one oncocytoma in one kidney with no history of TS in a diabetic patient. According to literature, there are less than 20 reports of synchronous AML and oncocytomas (10). Additionally, distinct morphologic features of diabetic nephropathy were also present in this case and to the best of our knowledge, there is no report of triple kidney neoplasms including two AMLs and one oncocytoma in a diabetic patient in literature.

### Acknowledgment

We are grateful to Mr. Ali Jafari, technician of pathology for his assistance in processing and staining of the specimens.

### References

1. Teodosiosis S, Yiallourou A, Kyriazi M, Anastasopoulos G, Kairi-Vassilatou E, Dafnios N, Vassiliou I. Unilateral simultaneous renal oncocytoma and angiomyolipoma: case report. *Cases J* 2009;2:9093.
2. Al-Thani H, El-Menyar A, Al-Sulaiti M, El-Mabrok J, Hajaji K, Elgohary H, et al. Clinical Presentation, Management, and Outcome of Patients with Incidental Renal Angiomyolipoma in Qatar. *Oman Med J* 2014;29:419-24.
3. Perez-Ordóñez B, Hamed G, Campbell S, Erlandson RA, Russo P, Gaudin PB, et al. Renal Oncocytoma: A Clinicopathologic Study of 70 Cases. *Am J surg pathol* 1997;21:871-83.
4. Fairchild TN, Dail DH, Brannen GE. Renal oncocytoma. Bilateral, multifocal. *Urology* 1983;22:355-59.
5. Tamboli P, Ro JY, Amin MB, Ligato S, Ayala AG. Benign tumors and tumor-like lesions of the adult kidney. Part II: Benign mesenchymal and mixed neoplasms, and tumor-like lesions. *Adv Anat Pathol* 2000;7:47-66.
6. Ashfaq R, Weinberg AG, Albores-Saavedra J. Renal angiomyolipomas and HMB-45 reactivity. *Cancer* 1993;71:3091-97.
7. Pillay K, Lazarus J, Wainwright HC. Association of angiomyolipoma and oncocytoma of the kidney: a case report and review of the literature. *J Clin Pathol* 2003;56:544-47.
8. Davis Jr CJ, Sesterhenn IA, Mostofi FK. Renal oncocytoma: clinicopathological study of 166 patients. *J Urogenit Pathol* 1991;1:41-52.
9. Amin MB, Tickoo SK, Crotty TB, Farrow GM. Concurrent renal oncocytoma and renal cell carcinoma within the same kidney: diagnostic implications. *Am J Surg Pathol* 1998;22:510.
10. Bahrami A, Schwartz NR, Ayala AG, Goldfarb RA, Brady JR, Takei H, et al. Concurrent angiomyolipoma and two oncocytomas in the same kidney. *Ann Diagn Pathol* 2007;11:132-36.
11. Jimenez RE, Eble JN, Reuter VE, Epstein JI, Folpe AL, de Peralta-Venturina M, et al. Concurrent angiomyolipoma and renal cell neoplasia: a study of 36 cases. *Mod Pathol* 2001;14:157-63.
12. Delgado R, de Leon Bojorge B, Albores-Saavedra J. Atypical angiomyolipoma of the kidney: a distinct morphologic variant that is easily confused with a variety of malignant neoplasms. *Cancer* 1998;83:1581-92.

13. Martignoni G, Pea M, Bonetti F, Brunelli M, Eble JN. Oncocytoma-like angiomyolipoma: a clinicopathologic and immunohistochemical study of 2 cases. Arch Pathol Lab Med 2002;126:610-2.