

Immunohistochemical Profile of Uterine Leiomyoma with Bizarre Nuclei; Comparison With Conventional Leiomyoma, Smooth Muscle Tumors of Uncertain Malignant Potential and Leiomyosarcoma

Ali Dastranj Tabrizi¹, Morteza Ghojzadeh^{2*}, Hanieh Thagizadeh Anvar¹, Amir Vahedi¹, Siamak Naji³, Elmira Mostafidi¹, Siamak Berenjjan¹

¹ Women's Reproductive Health Research Center, Tabriz University of Medical Sciences, Tabriz, Iran.

² Liver and Gastrointestinal Disease Research Center, Tabriz University of Medical Sciences, Tabriz, Iran.

³ Pathology Department, Urmieh University of Medical Sciences, Urmieh, Iran.

Article info

Article History:

Received: 3 April 2014
Revised: 30 July 2014
Accepted: 2 August 2014
ePublished: 31 December 2015

Keywords:

- Leiomyoma
- Leiomyosarcoma
- Smooth muscle tumors
- P53 gene

Abstract

Purpose: To assess the immunohistochemical profile of the atypical nuclei in leiomyoma with bizarre nuclei and compare with benign and malignant counterparts.

Methods: 26 cases of uterine smooth muscle tumors including 12 leiomyosarcoma(LMS), 10 leiomyoma with bizarre nuclei (LBN) and 4 smooth muscle tumor with uncertain malignant potential (STUMP) were selected using whole tissue sections for this study and analysis. Six cases of ordinary leiomyoma were included as benign control group. All representative section were stained for P53, Ki67, estrogen receptor and progesterone receptor. Analysis was carried out using SPSS 16.0 for windows software.

Results: Six out of 12 cases of LMS showed strong and diffuse nuclear staining with p53 antibody (50%). In contrast none of STUMPs and only one case of LBN cases showed focal positive reaction with P53. Percentage of positive cells for ki67 in LMS was 14.92 while only 0.85% of cells in LBNs was labeled with Ki67 proliferative marker. (P<0.001). Regarding steroid hormone receptors a significant losing trend was found in these receptors from benign toward malignant tumors through LBN and STUMP cases.

Conclusion: Loss of inhibitory function of wild type P53 gene in leiomyosarcoma is an essential event that discriminate frankly malignant tumors from STUMP and atypical leiomyoma.

Introduction

Uterine smooth muscle tumors are extremely common and most of them are benign. Histologically almost all leiomyomas are easily recognized for being of smooth muscle origin and also as a benign tumor.¹ These tumors are the most common uterine neoplasms whereas the malignant counterpart constitutes approximately 1% of uterine malignancies.^{2,3}

Leiomyoma with bizarre nuclei is a term that has been used for smooth muscle tumors with focal or diffusely distributed multinucleated giant cells in which no coagulative tumor cell necrosis and no increased mitotic activity is seen⁴ (Figure 1 C&F). Przybora introduced the term "leiomyosarcoma in situ" for these neoplasms in 1961 for being considerable concern about the giant cell component,⁵ however, "Symplastic" and "atypical" leiomyoma are frequently used synonyms for these type of tumors.

Although results of numerous studies with long time follow up indicate for uneventful clinical course for leiomyoma with bizarre nuclei,⁶⁻⁸ in a more recent study, the Stanford investigators reported 46 additional cases of atypical leiomyomas, which 4 of them recurred.⁹

Likewise considerable controversy has surrounded the nature of atypical nuclei in LBNs. For example some investigators consider these nuclei "malignant" whereas the other consider as a "degenerative change" occurred in benign cells.¹⁰ In fact it is extremely difficult to distinguish the degenerative nuclei from truly atypical and malignant cells with confidence on light microscopic examination.¹¹

This study is conducted for identifying of immunohistochemical profile of the atypical nuclei in LBN and compares them with benign and malignant counterparts. In addition we identified the immunohistochemical differences between various types of uterine smooth muscle tumors and tried to clarify to how degree the current terminologies and classifications are supported by molecular findings.

Materials and Methods

After approval from the institutional review board and ethical committee at Tabriz University of Medical Sciences (Tabriz, Iran), 32 cases of uterine smooth muscle tumors were selected for this study and analysis.

*Corresponding author: Morteza Ghojzadeh, Telefax: +98 411 3373741, Email: Ghojzadehm@hotmail.com

All cases with diagnosis of leiomyoma with bizarre nuclei-LBN (10 cases), smooth muscle tumor of uncertain malignant potential-STUMP (4 cases) and leiomyosarcoma- LMS (12 cases) were identified from pathology file of Tabriz Alzahra and Urmieh Mothhari

hospitals between 2007-2012 and their diagnosis were confirmed by a gynecological pathologist (DT. A). Six cases of ordinary leiomyoma were included as benign control group.

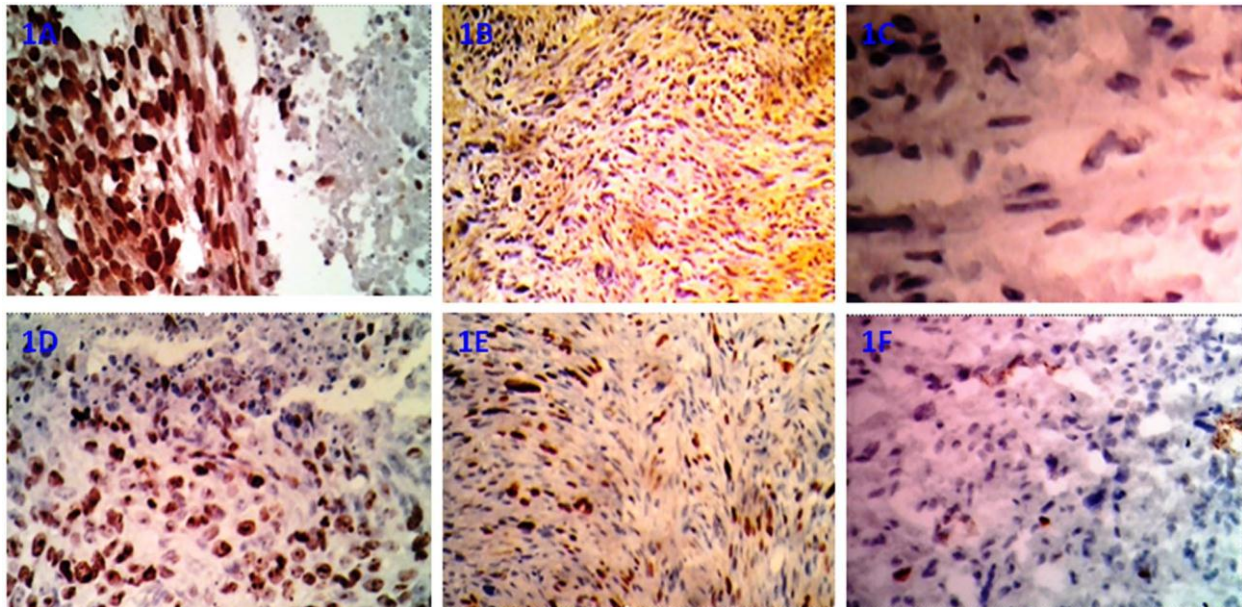


Figure 1. P53 and Ki67 immunostaining in uterine smooth muscle tumors. 1A: Leiomyosarcoma; In this case nearly all of the tumoral cells showing strong and diffuse P53 positivity. Coagulative tumor cell necrosis (CTCN) is seen in upper right side of the figure. 1B: Negative P53 in smooth muscle tumors of undetermined malignant potential. 1C: Negative reaction for P53 in leiomyoma with bizarre nuclei. 1D and 1E: High percentage of Ki67 positivity in tumoral cells in leiomyosarcoma and smooth muscle tumors of undetermined malignant potential respectively. 1F: Very low percentage of Ki67 positivity in nuclei of Leiomyoma with bizarre nuclei.

Diagnosis of LMS, STUMP, LBN and conventional leiomyoma was based on criteria published earlier.^{12,13} Briefly coagulative tumor cell necrosis, mitotic count more than 10 / 10 HPF and nuclear atypia were used as essential histologic criteria for diagnosis and classifying uterine smooth muscle tumors. A tumor with 2 of these 3 criteria is often a malignant tumor to warrant a diagnosis of leiomyosarcoma. STUMP was used in any condition in which we encountered with unusual combination of these histologic criteria that didn't fit for diagnosis of leiomyosarcoma.¹¹ Similarly we used leiomyoma with bizarre nuclei in cases with focal or multifocal collections of atypical cells showing large, bizarre and multilobulated nuclei in association with hyperchromasia. The mitotic count should be on average less than 2-3 /10 HPF.

A representative block was selected from each case. Briefly we used MIB1 (Dako, Copenhagen, Denmark), P53 monoclonal antibody (clone DO-7, ready to use-Dako), Estrogen Receptor a monoclonal antibody (clone1D5, Ready to use-Dako) and Progesterone Receptor monoclonal antibody (PgR 636, Ready to use-Dako) for detecting of Ki 67 antigen, P53, ER and PR respectively.

Only nuclear staining was considered as positive in all marker staining. For P53, diffuse (>75% of cell population) and strong nuclear staining was considered as positive. Ki 67 score was counted on minimum 500

cells at HPF which containing representative sections of tumor and calculated as fraction of positive cells to total number of cells in percentage. ER and PR positivity was scored using the so-called "Allred Score".¹⁴

Data analysis was performed using SPSS 16.0/_{win} for windows computer program. Chi-square or Fishers Exact test were used to compare the qualitative variables when appropriate. Statistical significance level was considered at $P < 0.05$.

Results

6 out of 12 cases of LMS showed strong and diffuse nuclear staining with p53 antibody (50%) while only 1 case of LBNs (11%) and none of STUMPs and leiomyomas was positive for p53 (Table 1). The percentage of positive nuclei in ki67 stained slides was 0.85% in LBNs and 7% in STUMPs while 14.92% of nuclei in leiomyosarcomas showed positive nuclear staining with Ki67 ($P < 0.001$). None of cells in 6 ordinary leiomyoms showed positive reaction for this marker (Table 1). Regard to steroid hormone receptors a significant losing trend was found in these receptors from benign toward malignant tumors through LBN and STUMP cases (Table 1). It should be mentioned that some differences regard to number of cases in tables are related to missing of representative foci in repeated microscopic section in process of IHC staining.

Table 1. Immunohistochemical profile of examined cases regard to p53, Ki67, Estrogen Receptor(ER) and Progesterone Receptor(PR).

| Cases | P53 (%) | Ki67 (%) | ER (%) | PR (%) |
|--------------|----------|----------|----------|----------|
| LMS* (n=12) | 6 (50%) | 14.92 % | 0 (0. %) | 0 (0.0%) |
| STUMP† (n=4) | 0 (0.0%) | 7.0 % | 0 (0%) | 3 (75%) |
| LBN‡ (n=10) | 1 (10%) | 0.85 % | 4 (40%) | 9 (90%) |
| LM§ (n=6) | 0 (0.0%) | 0.00 % | 6 (60%) | 6 (100%) |

Leiomyosarcoma

† Smooth muscle tumors with undetermined malignant potential

‡ Leiomyoma with bizarre nuclei

§ Conventional leiomyoma

Discussion

Leiomyoma with bizarre nuclei are rare which defined as a variant of leiomyoma (atypical leiomyoma) and characterized by presence of cells with bizarre, multiple, multilobulated and hyperchromatic nuclei usually with smudged chromatin distributed in focal or multifocal pattern.¹¹ Multinucleated tumor giant cells have been found in 65-80 % of uterine leiomyosarcoma in some studies^{15,16} and presence of these cells has provoked considerable concern among pathologists in some of the otherwise conventional leiomyomas. Regard to biologic behavior, in a large comprehensive series studied by Downes and Hart,¹² none of their 24 cases showed recurrence or metastasis in long term follow up although only four of the 24 cases treated with myomectomy. In contrast in another study 4 of 46 leiomyoma with bizarre nuclei recurred and none of them including the recurrent cases showed mitotic rate above 3/10 HPF.⁹ For resolving this dilemma some molecular studies tried to declare the biologic nature of these atypical cells and compare the immunohistochemical findings between malignant, atypical and benign smooth muscle cells. For example in a study on nine cases of symplastic uterine

leiomyomas, Sun and Mittal found no significant difference in expression of P53, ER and PR immunostaining between atypical and non-atypical cells except for Ki67 which significantly was higher in atypical cells.¹⁰ In contrast Sung et al. found p53 expression in 5 of 13 cases of leiomyoma with bizarre nuclei and ki67 expression in less than 5% of atypical nuclei with one recurrent case.⁷

In contrast with the last study our results revealed a distinctive difference between malignant cells in leiomyosarcoma and other groups regard to expression of p53 (Figure 1A-C). Six cases from 12 leiomyosarcoma (50%) in this study showed positive immunoreactivity, while none of our STUMPs and only one case of LBNs showed positive reaction. These results are in line with recently published series of nine LBNs in which no statistically significant difference was found between non-atypical and atypical cells in relation to p53 staining.¹⁰ Likewise our findings are in line with O'Neil et al. in which expression of p53 was found in only 3/11 symplastic leiomyoma.¹⁷

The significant difference in number of Ki-67 positive cells between leiomyosarcoma cases as a group and STUMP, LBN and leiomyoma as another group ($P < 0.05$) and increasing rate of Ki-67 positivity (Figure 1D-F) from conventional leiomyoma to frankly malignant leiomyosarcoma through LBN and STUMP in our study may indicate for a biologic potential of recurrence in LBN and STUMP cases which has been found in some of the follow up studies although the proliferative index in our LBNs was lower than the other reports.¹³ Likewise, increasing loss of ER and PR receptors in STUPM and LBN groups in our results (Figure 2A-F) may show some similarities in loss of steroid receptors between these tumors and leiomyosarcoma.

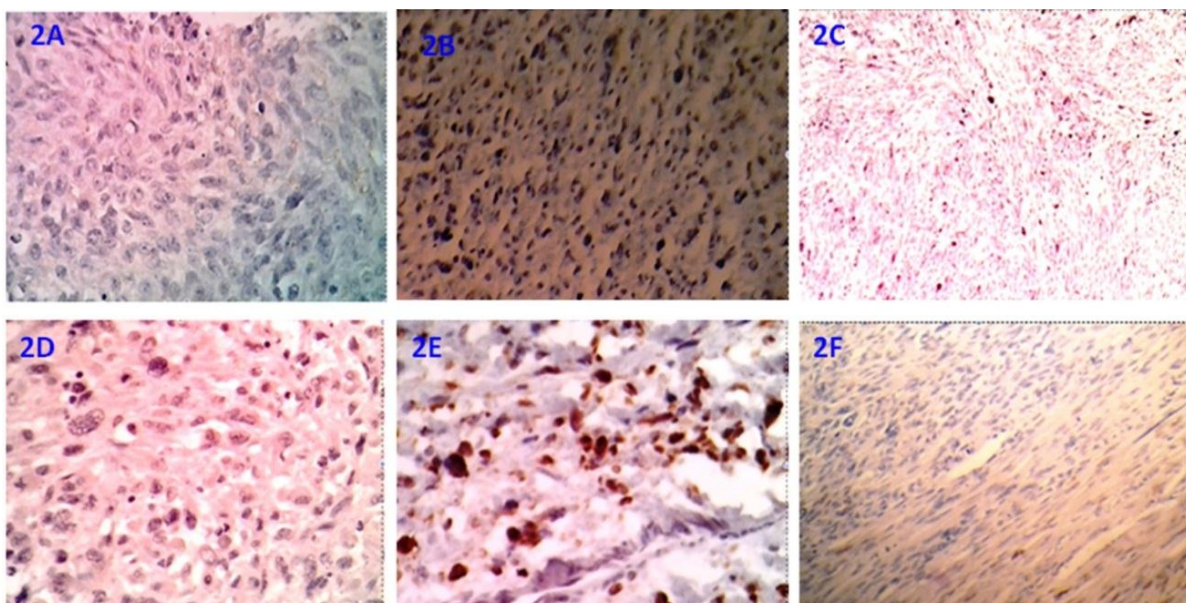


Figure 2. ER and PR immunostaining in uterine smooth muscle tumors. 2(A&D): Complete negative reaction for ER and PR in leiomyosarcoma respectively. 2(B&E): Large number of tumoral cells showing positive reaction for ER and PR in STUMP respectively. 2(C&F): Positive nuclear reactivity for ER and PR in LBN respectively.

Our immunohistochemical findings indicate that the application of current microscopic criteria for diagnosis and nomenclature of these tumors is useful although the number of cases were relatively limited in this study. Other limitations in our research was absence of follow up results because many cases were new patients. Other investigations with higher number of cases with diagnostic value instruction and follow up studies may be useful for achievement of more significant results.

Conclusion

In conclusion our molecular findings showed that P53 immunostaining as a part of IHC panel may be used for histopathologic diagnosis of problematic uterine smooth muscle tumors and probably loss of inhibitory function of wild type p53 gene in leiomyosarcoma is an essential event that does not occur in atypical leiomyomas. In addition presence of higher proliferative index in leiomyosarcoma cases may be indicative for biologic mechanism of highly aggressive clinical course that seen in this group of uterine smooth muscle tumors.

Acknowledgments

The authors thank the women's reproductive health research center- Tabriz university of medical sciences- Iran for financial support of this work.

Ethical Issues

Not applicable.

Conflict of Interest

None declared.

References

- Zaloudek CH, Hendrickson M. In: Kurman RJ, editor. Blaustein's pathology of the female genital tract. New York: Springer; 2002. P. 562-3.
- Laughlin SK, Schroeder JC, Baird DD. New directions in the epidemiology of uterine fibroids. *Semin Reprod Med* 2010;28(3):204-17. doi: 10.1055/s-0030-1251477
- Saldana TM, Moshesh M, Baird DD. Self-reported family history of leiomyoma: not a reliable marker of high risk. *Ann Epidemiol* 2013;23(5):286-90. doi: 10.1016/j.annepidem.2013.03.003
- Ly A, Mills AM, Mckenney JK, Balzer BL, Kempson RL, Hendrickson MR, et al. Atypical leiomyomas of the uterus: a clinicopathologic study of 51 cases. *Am J Surg Pathol* 2013;37(5):643-9. doi: 10.1097/PAS.0b013e3182893f36
- Przybora LA. Leiomyosarcoma in situ of the uterus. *Cancer* 1961;14:483-92. doi: 10.1002/1097-0142(199005/06)14:3<483::aid-cncr2820140305>3.0.co;2-2
- Deodhar KK, Goyal P, Rekhi B, Menon S, Maheshwari A, Kerkar R, et al. Uterine smooth muscle tumors of uncertain malignant potential and atypical leiomyoma: a morphological study of these grey zones with clinical correlation. *Indian J Pathol Microbiol* 2011;54(4):706-11. doi: 10.4103/0377-4929.91500
- Sung CO, Ahn G, Song SY, Choi YL, Bae DS. Atypical leiomyomas of the uterus with long-term follow-up after myomectomy with immunohistochemical analysis for p16INK4A, p53, Ki-67, estrogen receptors, and progesterone receptors. *Int J Gynecol Pathol* 2009;28(6):529-34. doi: 10.1097/pgp.0b013e3181a2b8d3
- Mills AM, Ly A, Balzer BL, Hendrickson MR, Kempson RL, Mckenney JK, et al. Cell cycle regulatory markers in uterine atypical leiomyoma and leiomyosarcoma: immunohistochemical study of 68 cases with clinical follow-up. *Am J Surg Pathol* 2013;37(5):634-42. doi: 10.1097/pas.0b013e318287779c
- Ly A, McKenney JK, Longacre TA. Atypical leiomyoma of the uterus: a clinicopathologic study of 46 cases. *Mod Pathol* 2009;22:225A.
- Sun X, Mittal K. MIB-1 (Ki-67), estrogen receptor, progesterone receptor, and p53 expression in atypical cells in uterine symplastic leiomyomas. *Int J Gynecol Pathol* 2010;29(1):51-4. doi: 10.1097/pgp.0b013e3181b0259b
- Ip PP, Tse KY, Tam KF. Uterine smooth muscle tumors other than the ordinary leiomyomas and leiomyosarcomas: a review of selected variants with emphasis on recent advances and unusual morphology that may cause concern for malignancy. *Adv Anat Pathol* 2010;17(2):91-112. doi: 10.1097/pap.0b013e3181cfb901
- Downes KA, Hart WR. Bizarre leiomyomas of the uterus: a comprehensive pathologic study of 24 cases with long-term follow-up. *Am J Surg Pathol* 1997;21(11):1261-70. doi: 10.1097/00000478-199711000-00001
- Evans HL, Chawla SP, Simpson C, Finn KP. Smooth muscle neoplasms of the uterus other than ordinary leiomyoma. A study of 46 cases, with emphasis on diagnostic criteria and prognostic factors. *Cancer* 1988;62(10):2239-47. doi: 10.1002/1097-0142(19881115)62:10<2239::aid-cncr2820621028>3.0.co;2-y
- Mohsin SK, Weiss H, Havighurst T, Clark GM, Berardo M, Roanh Le D, et al. Progesterone receptor by immunohistochemistry and clinical outcome in breast cancer: a validation study. *Mod Pathol* 2004;17(12):1545-54. doi: 10.1038/modpathol.3800229
- Van Meurs HS, Dieles JJ, Stel HV. A uterine leiomyoma in which a leiomyosarcoma with osteoclast-like giant cells and a metastasis of a ductal breast carcinoma are present. *Ann Diagn Pathol* 2012;16(1):67-70. doi: 10.1016/j.anndiagpath.2010.11.010
- Li L, Othman M, Rashid A, Wang H, Li Z, Katz MH, et al. Solid pseudopapillary neoplasm of the pancreas with prominent atypical multinucleated giant tumour

- cells. *Histopathology* 2013;62(3):465-71. doi: 10.1111/his.12023
17. O'Neill CJ, McBride HA, Connolly LE, McCluggage WG. Uterine leiomyosarcomas are characterized by high p16, p53 and mib1 expression in comparison with usual leiomyomas, leiomyoma variants and smooth muscle tumours of uncertain malignant potential. *Histopathology* 2007;50(7):851-8. doi: 10.1111/j.1365-2559.2007.02699.x