



## Case Report

# Adrenocortical Carcinoma With Renal Vein Thrombus Extended to Inferior Vena Cava: A Case Report

Mohsen Ayati<sup>1</sup>, Jafar Shahbazi<sup>1</sup>, Ali Tehranchi<sup>2</sup>, Elnaz Ayati<sup>1</sup>, Yousef Rezaei<sup>3</sup>

<sup>1</sup>*Uro-Oncology Research Center, Tehran University of Medical Sciences, Tehran, Iran*

<sup>2</sup>*Urmia Urology and Nephrology Research Center, Urmia University of Medical Sciences Urmia, Iran*

<sup>3</sup>*Seyyed-al-Shohada Heart Center, Urmia University of Medical Sciences, Urmia, Iran*

**?** Adrenocortical carcinoma (ACC) is a rare aggressive tumor. Renal vein and inferior vena cava (IVC) thrombi have been found as uncommon presentations of ACC; however, the implementation of comprehensive therapy has remained controversial in such cases. We report a case of a 46-year-old woman with a large ACC associated with the invasion of tumor to IVC confirmed by imaging and immunohistochemistry examinations. The patient was treated successfully using aggressive surgery, including adrenalectomy and thrombectomy adjunct to an adrenocorticolytic agent. However, she died of metastasis complications at 3-month follow-up period. ACC is a rare malignancy, mostly presenting in advanced stages with poor prognosis. Implementing aggressive surgical therapy might be effective for the management of such cases; however, the short survival duration in our case underscores the need for defining the precise therapy of metastatic ACC associated with venous invasion.

*Key words:* Adrenocortical carcinoma – Inferior vena cava thrombus – Distant metastasis – Adrenalectomy

Adrenocortical carcinoma (ACC) is a rare aggressive malignancy and naturally has a poor prognosis. The annual incidence of ACC has been reported as approximately 1 to 2 per million among the US population.<sup>1</sup> Patients with active endocrine adrenal tumors are often diagnosed with Cushing's syndrome associated with virilizing features; however, patients with nonfunctional tumors may pre-

---

Corresponding author: Yousef Rezaei, Seyyed-al-Shohada Heart Center, Urmia University of Medical Sciences, Urmia, Iran.

Tel.: +98 912 623 1864; Fax: +98 441 237 5907; E-mail: yousefrezaei1986@gmail.com

sent with symptoms consistent with a mass-occupying lesion such as abdominal or flank pain.<sup>2</sup> Surgery has long been considered as the only curative therapy, in which the overall 5-year survival of patients undergoing a complete resection has been found to be approximately 32% to 48%.<sup>3</sup> Although renal vein and inferior vena cava (IVC) involvements are common problems in renal cell carcinoma, those are uncommon presentations of ACC and make surgery difficult. The involvement of IVC is a main obstacle to surgical therapy in patients with ACC.<sup>4</sup> Herein, we report a case of a large ACC tumor associated with thrombus extension to both the renal vein and IVC, which was treated using aggressive surgery and resulted in short-term survival. This report assesses the previously reported ACC cases with venous thrombosis extending to IVC.

### Case Report

A 46-year-old woman presented to our hospital with a complaint of left flank pain of 5-month duration. She had a history of hepatobiliary carcinoma in her mother diagnosed 20 years ago as well as a history of cerebral glioblastoma in her brother detected 2 years ago. Physical examination revealed a hard mass in the left upper quadrant of her abdomen. Routine laboratory tests were in normal limits except for liver function tests, which showed in the upper limit of normal values, including alanine transaminase and aspartate aminotransferase tests, 65 and 74 U/L, respectively. Ultrasound investigation showed a huge mass in the upper pole of her left kidney associated with multiple liver metastases consistent with the primary diagnosis of metastatic renal cell carcinoma or adrenal tumor. The imaging of her abdomen by computed tomography (CT) scan showed a large retroperitoneal mass in the upper pole of the left kidney displacing her left kidney downwards. The functional tests of the adrenal gland were in normal range, as well. Magnetic resonance imaging (MRI) showed a solid mass lesion (12×12×10 cm) associated with heterogeneous signal intensity and enhancement after contrast injection at the left side of the abdominal cavity, which seemed to originate from the upper pole of the left kidney with pressure effect resulting in a downward displacement of the kidney along with multiple liver and lung metastases (Fig. 1). Thereafter, a CT-guided abdominal mass biopsy was also performed, and the diagnosis of ACC was consequently confirmed on the basis of pathology and

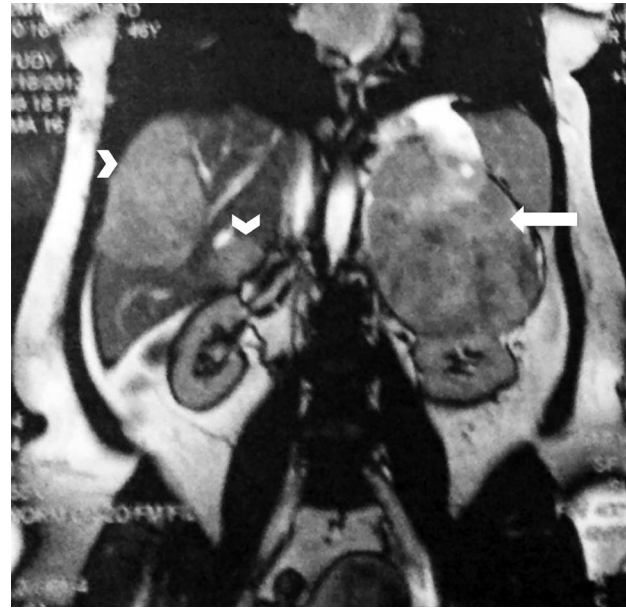


Fig. 1 MRI showing adrenal tumor (arrow) and liver metastasis (arrowheads).

immunohistochemistry examinations. The immunohistochemistry test was positive for Melan-A, vimentin, Ki67 20%, and synaptophysin, and also showed negative results for endomysial antibody, creatine kinase, HepPar, calretinin, and chromogranin.

?2

After the completion of all diagnostic examinations, given the efficacy of surgical therapies to improve survival even in metastatic ACC cases,<sup>5</sup> a laparotomy was performed with chevron incision. During the operation, we noticed a hypervascular mass in the upper pole of the left kidney with renal hilum involvement along with a venous thrombus extending to both the left renal vein and IVC. Consequently, we completed surgery, performing adrenalectomy, left nephrectomy, para-aortic lymphadenectomy, and thrombectomy using the temporary ligation of both proximal and distal parts of IVC thrombus. The pathology report of the liver biopsy revealed an ACC, 16.5-cm in size, associated with multifocal vascular invasion, extensive necrosis, invasion to perirenal fat and renal hilum veins, and metastasis to hilar lymph nodes and the liver. The patient was referred to an oncologist to undergo chemotherapy with a regimen of Mitotane, as an adrenocorticolytic agent. However, she died of metastasis complication and diagnosing at advanced stages after 3-month follow-up.

## Discussion

ACC is a rare and typically aggressive tumor, in which approximately 60% of cases present with the symptoms and signs of adrenal steroid hormone elevation that are similar to our case and are associated with female predominance (female to male ratio, 2.5).<sup>6</sup> Some cases have previously been reported; therefore we conducted a MEDLINE literature search over a 32-year period and found 44 cases of ACC with tumor thrombus extending to the IVC).<sup>1-4,7-20</sup> There were 18 nonfunctioning tumors and 26 functioning tumors, predominantly right-sided (32 right-sides versus 12 left-sides) and measuring 18 to 255 mm (median, 110 mm). Fifteen patients (34.1%) presented with distant metastases. Half of the cases were men with a median age of 51 years (range, 1-84 years). Clinical manifestations in functional tumors consisted of virilizing,<sup>10</sup> heterosexual pseudoprecocious puberty,<sup>11</sup> and Cushing's syndrome<sup>3</sup>; and in nonfunctional tumors, comprised flank mass,<sup>1</sup> varicocele,<sup>2</sup> hemoptysis,<sup>12</sup> and dyspnea.<sup>14</sup> The upper limit of thrombus extension was infrahepatic IVC in 22 cases, retrohepatic IVC in 7 cases, and suprahepatic IVC in 16 cases, including 12 with extension into the right atrium. In addition, median survival duration has been reported to be 8 months (range, 2-61 months).

Although invasive surgery is the only therapeutic option, Kim *et al* reported a case of a large ACC with thrombus extension to the right atrium in which, despite the patient's refusal to undergo surgery, the tumor regressed spontaneously during follow-up.<sup>14</sup> Some investigations found that the survival and quality of life of such cases improved after radical surgery.<sup>19,20</sup> In fact, in metastatic cases, even after radical surgery, 5-year survival has been shown to be 24%<sup>13</sup>; in another report, 5-year survival has been 7%, although in this case, surgery improved survival).<sup>5</sup> According to our literature review, the median survival for metastatic and nonmetastatic cases was 8 months, and given the 3-month survival in our case and those of previously reported cases, it seems that we need further large-scale study.

Regarding the management of atrial thrombus, several reports have suggested that the complete surgical removal of primary tumor with cavoatrial mass using cardiopulmonary bypass is the treatment of choice.<sup>3</sup> Similarly, in the cases we found in MEDLINE, 12 patients had been diagnosed with atrial thrombus, and most of them had successfully undergone cardiopulmonary bypass surgery. No clinical trial has been performed comparing the

difference between other modalities such as interventional procedures with open heart surgery.

ACC is often diagnosed after a great delay in an advanced stage, as shown in the present case. The only potential curative treatment for ACC has been postulated to be repeated surgical resection,<sup>15</sup> which is technically possible in most patients. The most important predictor of survival in patients with adrenal cancer is the adequacy of resection. In a case series of ACC with thrombus, all patients underwent complete resection of venous thrombus and had 5-year survival rates ranging from 32% to 48%, while the median survival was less than 1 year in patients undergoing incomplete excision. Other treatment options include Mitotane, adjuvant chemotherapy, and palliative irradiation.<sup>9</sup> The treatment of advanced ACC cases basically consists of surgical resection and Mitotane- or Cisplatin-based chemotherapy.<sup>21</sup> Some studies investigating the Mitotane alone in metastatic, unresectable, or incomplete resection cases have demonstrated a response rate of 19% to 33% associated with 9-month survival in largest one.<sup>22-24</sup> In the previously reported cases, as stated in this report, postoperative Mitotane was administered in 29 patients. Given these findings and the short survival of our case, it seems that the aggressive surgery associated with adjuvant chemotherapy may not be considered as the treatment of choice for such cases, although it may be associated with increasing the survival rate.

In conclusion, ACC is a rare malignancy mostly presenting in advanced stages with poor prognosis. Our findings demonstrate that the aggressive surgical treatment might be effective for the management of ACC cases associated with thrombus extension to the IVC. Yet, the short survival duration in our case underscores the need for a large-scale clinical trial to find the precise therapy for metastatic ACC cases associated with venous invasion.

## References

1. Patel VV, Shah DS, Raychaudhari CR, Patel KB. Giant non-functioning adrenocortical carcinoma: a rare childhood tumor. *Indian J Med Paediatr Oncol* 2010;**31**(2):65-68
2. Cheungpasitporn W, Horne JM, Howarth CB. Adrenocortical carcinoma presenting as varicocele and renal vein thrombosis: a case report. *J Med Case Rep* 2011;**5**(XX):337
3. Kumar S, Choudhary GR, Pushkarna A. Functioning adrenocortical carcinoma with extension upto the right atrium producing Cushing's syndrome. *J Clin Imaging Sci* 2013;**3**(XX):32

4. Nakanoma T, Ueno M, Nonaka S, Tsukamoto T, Deguchi N. Left adrenocortical cancer with inferior vena cava tumor thrombus—a case report [in Japanese]. *Nihon Hinyokika Gakkai Zasshi* 2001;**92**(1):34–37
5. Livhits M, Li N, Yeh MW, Harari A. Surgery is associated with improved survival for adrenocortical cancer, even in metastatic disease. *Surgery* 2014;**156**(6):1531–1541
6. Luton JP, Cerdas S, Billaud L, Thomas G, Guillaume B, Bertagna X *et al*. Clinical features of adrenocortical carcinoma, prognostic factors, and the effect of mitotane therapy. *N Engl J Med* 1990;**322**(17):1195–1201
7. Carbonnel F, Valla D, Menu Y, Lecompte Y, Belghiti J, Rueff B *et al*. Acute Budd-Chiari syndrome as first manifestation of adrenocortical carcinoma. *J Clin Gastroenterol* 1988;**10**(4):441–444
8. Chiche L, Dousset B, Kieffer E, Chapuis Y. Adrenocortical carcinoma extending into the inferior vena cava: presentation of a 15-patient series and review of the literature. *Surgery* 2006;**139**(1):15–27
9. Figueroa AJ, Stein JP, Lieskovsky G, Skinner DG. Adrenal cortical carcinoma associated with venous tumour thrombus extension. *Br J Urol* 1997;**80**(3):397–400
10. Gahan J, Shirodkar SP, Gorin MA, Salerno TA, Ciancio G. Surgical resection of a virilizing adrenal mass with extensive tumor thrombus. *Can J Urol* 2011;**18**(3):5735–5738
11. Ghazizadeh F, Ebadi M, Alavi S, Arzanian M, Shamsian B, Jadali F. Adrenocortical carcinoma presenting with heterosexual pseudoprecocious puberty shortly after birth: case report and review. *Ecancermedicalscience* 2013;**7**:289
12. Huguet C, Caporossi M, Gavelli A, Harb J, McNamara M. Neoplastic thrombosis of the inferior vena cava involving the right atrium caused by adrenal cortical carcinoma. A new indication for vascular exclusion of the liver [in French]. *Ann Chir* 1994;**48**(4):364–369
13. Icard P, Goudet P, Charpenay C, Andreassian B, Carnaille B, Chapuis Y *et al*. Adrenocortical carcinomas: surgical trends and results of a 253-patient series from the French Association of Endocrine Surgeons study group. *World J Surg* 2001;**25**(7):891–897
14. Kim KH, Park JC, Lim SY, Sohn IS, Yun KH, Cho SH *et al*. A case of non-functioning huge adrenocortical carcinoma extending into inferior vena cava and right atrium. *J Korean Med Sci* 2006;**21**(3):572–576
15. Kopf D, Goretzki PE, Lehnert H. Clinical management of malignant adrenal tumors. *J Cancer Res Clin Oncol* 2001;**127**(3):143–155
16. Meniconi RL, Caronna R, Schiratti M, Dinatale G, Russillo GC, Liguori A *et al*. Adrenocortical carcinoma extending into the inferior vena cava in a patient with right kidney agenesis: surgical approach and review of literature. *Int J Surg Case Rep* 2012;**3**(7):302–304
17. Mihai R, Iacobone M, Makay O, Moreno P, Frilling A, Kraimps JL *et al*. Outcome of operation in patients with adrenocortical cancer invading the inferior vena cava—a European Society of Endocrine Surgeons (ESES) survey. *Langenbecks Arch Surg* 2012;**397**(2):225–231
18. Pritchett TR, Raval JK, Benson RC, Lieskovsky G, Colletti PM, Boswell WD Jr *et al*. Preoperative magnetic resonance imaging of vena caval tumor thrombi: experience with 5 cases. *J Urol* 1987;**138**(5):1220–1222
19. Swan RZ, Hanna EM, Sindram D, Iannitti DA, Martinie JB. Adrenocortical carcinoma with intracaval extension to the right atrium: resection on cardiopulmonary bypass. *Ann Surg Oncol* 2012;**19**(4):1275
20. Virseda Rodriguez JA, Martinez Martin M, Hernandez Millan I, Canamares Pabolaza L. Adrenocortical carcinoma with inferior vena cava thrombosis [in Spanish]. *Actas Urol Esp* 1994;**18**(1):51–54
21. Ribeiro RC, Pinto EM, Zambetti GP, Rodriguez-Galindo C. The International Pediatric Adrenocortical Tumor Registry initiative: contributions to clinical, biological, and treatment advances in pediatric adrenocortical tumors. *Mol Cell Endocrinol* 2012;**351**(1):37–43
22. Baudin E, Pellegriti G, Bonnay M, Penfornis A, Laplanche A, Vassal G *et al*. Impact of monitoring plasma 1,1-dichlorodiphenildichloroethane (o,p'DDD) levels on the treatment of patients with adrenocortical carcinoma. *Cancer* 2001;**92**(6):1385–1392
23. Gonzalez RJ, Tamm EP, Ng C, Phan AT, Vassilopoulou-Sellin R, Perrier ND *et al*. Response to mitotane predicts outcome in patients with recurrent adrenal cortical carcinoma. *Surgery* 2007;**142**(6):867–875
24. Haak HR, Hermans J, van de Velde CJ, Lentjes EG, Goslings BM, Fleuren GJ *et al*. Optimal treatment of adrenocortical carcinoma with mitotane: results in a consecutive series of 96 patients. *Br J Cancer* 1994;**69**(5):947–951

**Queries for insu-101-06-10**

1. Author: This article has been lightly edited for grammar, style, and usage. Please compare it with your original document and make changes on these pages. Please limit your corrections to substantive changes that affect meaning. If no change is required in response to a question, please write "OK as set" in the margin. Copy editor
2. Author. Case Report, paragraph 1, last sentence. Should "HepPar" be "HepPar 1"? Copy editor
3. Author. Discussion, paragraph 1, sentence 2. Should the specific range of years be included? Copy editor
4. Author. Discussion, paragraph 1, sentence beginning "There were 18." Please ensure edit to the units in parentheses is correct. Copy editor
5. Author. Discussion, paragraph 2, sentence beginning "In fact." Please ensure edits have not changed meaning. Copy editor
6. Author. Discussion, paragraph 3, last sentence. Please ensure edits have not changed meaning. Copy editor
7. Author. Discussion, paragraph 4, sentence beginning "Some studies." Please clarify what is referred to as the "largest one." Is it the largest study? Copy editor
8. Author. Discussion, paragraph 5, last sentence. Please ensure edits have not changed meaning. Copy editor
9. Author. References 2, 3, 11, and 19. If this reference is an Abstract, please insert "[abstract]" immediately following the title, before the period. Also, in References 2 and 3. Please insert the issue in place of the XX's if available. Copy editor