

# Artificial Cells, Nanomedicine, and Biotechnology

## An International Journal

ISSN: 2169-1401 (Print) 2169-141X (Online) Journal homepage: <https://www.tandfonline.com/loi/ianb20>

## The use of stromal vascular fraction (SVF), platelet-rich plasma (PRP) and stem cells in the treatment of osteoarthritis: an overview of clinical trials

Sahar Mehranfar, Isa Abdi Rad, Ebrahim Mostafavi & Abolfazl Akbarzadeh

To cite this article: Sahar Mehranfar, Isa Abdi Rad, Ebrahim Mostafavi & Abolfazl Akbarzadeh (2019) The use of stromal vascular fraction (SVF), platelet-rich plasma (PRP) and stem cells in the treatment of osteoarthritis: an overview of clinical trials, *Artificial Cells, Nanomedicine, and Biotechnology*, 47:1, 882-890, DOI: [10.1080/21691401.2019.1576710](https://doi.org/10.1080/21691401.2019.1576710)

To link to this article: <https://doi.org/10.1080/21691401.2019.1576710>



© 2019 The Author(s). Published by Informa UK Limited, trading as Taylor & Francis Group.



Published online: 19 Mar 2019.



Submit your article to this journal [↗](#)



Article views: 407



View Crossmark data [↗](#)

## The use of stromal vascular fraction (SVF), platelet-rich plasma (PRP) and stem cells in the treatment of osteoarthritis: an overview of clinical trials

Sahar Mehranfar<sup>a,b</sup>, Isa Abdi Rad<sup>a,b</sup>, Ebrahim Mostafavi<sup>c</sup> and Abolfazl Akbarzadeh<sup>d,e</sup>

<sup>a</sup>Department of Genetics and Immunology, Faculty of Medicine, Urmia University of Medical Sciences, Urmia, Iran; <sup>b</sup>Cellular and Molecular Research Center, Urmia University of Medical Sciences, Urmia, Iran; <sup>c</sup>Department of Chemical Engineering, Northeastern University, Boston, MA, USA; <sup>d</sup>Drug Applied Research Center, Tabriz University of Medical Sciences, Tabriz, Iran; <sup>e</sup>Department of Medical Nanotechnology, Faculty of Advanced Medical Sciences, Tabriz University of Medical Sciences, Tabriz, Iran;

### ABSTRACT

Osteoarthritis (OA) is a major cause of disability across the world, which its prevalence is relatively high in elder population. Current accepted therapies such as exercise, anti-inflammatory drugs and intra-articular inoculation of corticosteroids are aimed at controlling symptoms in the affected patients. Surgical options including arthroplasty, osteotomy and joint replacement are other choices of treatment, which are invasive and can be applied in case of failure of conventional therapies. In the last few decades, efforts to treat musculoskeletal diseases are being increasingly focused on regenerative cellular therapies. Stromal vascular fraction (SVF), which obtained from adipose tissue, contains a variety of cells include mesenchymal stem cells (MSCs) and has shown to be effective in cartilage repair. Autologous blood products such as platelet-rich plasma (PRP) act as an adjuvant of surgical treatment and its intra-articular delivery has shown beneficial effects for OA treatment. Given the efficacy of such treatment approaches in OA, this paper discusses both preclinical and clinical evidence with major focus on clinical trials.

### ARTICLE HISTORY

Received 23 October 2018  
Accepted 16 January 2019

### KEYWORDS

Clinical trial; osteoarthritis; stem cell; platelet-rich plasma; stromal vascular fraction

### Introduction

Osteoarthritis (OA) is the most prevalent degenerative joint disease, which mostly impairs mobility and subsequent quality of life in elder individuals. Patients experience signs of pain, morning stiffness and a grating sound during joint motion known as crepitus. Although the pathogenesis of OA has been poorly understood, it has often defined with changes in articular cartilage. Tissue fluid, proteoglycans and type 2 collagen form the main structure of cartilage. Furthermore, chondrocytes, as the main cell type found in this area, can generate and maintain the extracellular environment. It has been reported that chondrocytes have no mitotic and regenerating capacities under physiologic condition. These cells can maintain the minimal turnover of collagens to make permanent structures in front of mechanical forces exerted on the joints. However, any mechanical stress or injury can stimulate chondrocytes to proliferate and increase their ability to synthesize the extracellular matrix as part of the repair process. The subsequent changes in matrix composition can induce chondrocytes to release catabolic factors leading to cartilage degradation. This can cause friction between bones and make pain and immobility in the affected patients [1].

Several risk factors include genetic, ageing, obesity and low-grade systemic inflammation have been described and

are being the subject of ongoing research in OA [2]. Data from twin and familial aggregation studies have estimated 40–65% genetic risk for OA. The strongest genetic association has been reported with growth differentiation factor 5 (*GDF5*) gene, which originally identified with candidate gene-based approach. Moreover, during the last 10 years, genome-wide association studies (GWAS) have established the remaining association with 21 genetic loci. These associated loci include genes that are involved in pathways related to cell signalling, apoptosis, mitochondrial damage and extracellular matrix remodelling. Although each individual allele exerts moderate to small risk in OA pathogenesis, their identification helps to discover the whole mechanism of the disease. In addition, it helps to find biomarkers to detect high-risk individuals or improve disease outcomes in the affected patients [3].

Among several aforementioned risk factors of OA, the most prevalent one is ageing. Evidence has shown that OA and ageing are two linked but independent processes. To date, several mechanisms have been proposed to declare how the ageing-associated changes promote OA development [4]. The low-grade systemic inflammation, as one of the OA risk factors, is created when the mass of muscle decreased and the fat mass increased in the body. This metabolic condition, as seen in obesity, can change mechanical loading, which further increases adipokines and cytokines in the joint space [5]. Other mechanisms include mitochondrial

dysfunction [6], oxidative stress [7], and reduced autophagy in chondrocytes [8], which increase the production of catabolic over anabolic factors. A kind of senescence has also been observed in chondrocytes that results in reduced sensitivity to different growth factors [9]. This phenomenon can increase inflammatory mediators as well as matrix-degrading enzymes in the joints. Moreover, senescence can cause telomere shortening as the much probable mechanism in cartilage damage [10]. Strategies for killing or modulating immune response in these senescence cells can be used as treatment options in OA.

Although OA is a very common illness, the existence of similar signs with other arthritis conditions makes it a difficult disease to diagnose. To date, no precise blood test has been recognized for OA diagnosis. However, imaging aids rheumatologists and radiologists for both diagnosis and longitudinal evaluation of the disease. In this regard, basic radiographs have been considered as the gold standard diagnostic tool in OA. In case of diagnostic uncertainty, other imaging techniques such as magnetic resonance imaging (MRI) and multidetector computed tomography (MDCT) can be used [11]. It has been reported that the structural changes of the joints can be seen with MRI, especially in early stages of the disease [12]. Computed tomography (CT)-based methods include four dimensional (4D)- and cone beam (CB)-CT can evaluate kinematic and weight-bearing characteristics of the joints. All the aforementioned techniques are cross-sectional and any changes in metabolic activities during synovial inflammation can be revealed through positron emission tomography (PET)-based analyses [13]. Moreover, recent research has reported that non-invasive detection of infiltrated innate immune cells can help to identify high-risk individuals [14].

## Treatment approaches

Many experiments in pathogenesis have revealed that OA is a generalized disease that affects different cells and tissues in the body. Therefore, a wider treatment approach is needed to target all the affected regions in the disease [15]. The goal of treatment in patients with OA is to reduce pain and stiffness, maintain the functional capacities as well as improving quality of life [16]. After diagnosis, physicians advise the patients to have low-impact aerobic exercise [17], lose their weight [18] and use nutraceuticals such as glucosamine and chondroitin sulfate [19]. Exercise helps to strengthen the muscle around the affected joints, which, in turn, reduces pain and instability in patients. There is also some evidence that patients can benefit from knee braces and shoe orthotics [20]. Aside from these non-pharmacological suggestions, patients may benefit from nonsteroidal anti-inflammatory drugs (NSAIDs) as well as intra-articular inoculations of corticosteroids and hyaluronic acid (HA) [21,22]. HA is a natural glycosaminoglycan, which provides lubricating and shock-absorbing capacities through acting as an osmotic buffer in the joints [23]. Some patients are advised to use fluoroscopic- and ultrasound-guided neural blockade [24,25]. These kinds of treatments can help to relieve symptoms and pain as well as preventing cartilage destruction in OA patients.

Surgical strategies in symptomatic patients are also beneficial for the management of OA in different types of tissues such as knee, hip and hands. These strategies can be conservative, in which the damaged cartilage is left in place, or radical such as arthroplasty, in which the total joint is replaced with an artificial prosthesis [26]. Arthroplasty has shown promising results in patients who have unsuccessful or contraindicated treatment modalities. However, like other treatment approaches, it has little but serious complications [27]. It should be noted that physicians should never prescribe arthroplasty for individuals younger than 60 years. These approaches are limited to focal lesions and may not be suitable in the field of OA, where the volume of cartilage loss is more generalized [28].

Limitations of previous treatment strategies include poor cell viability, limited supply and adverse effects on joint congruency have encouraged researchers to focus on regeneration rather than replacement of the affected tissues [29]. Progenitor cells are able to regenerate any damaged region in articular cartilage. However, the lack of vascularity in cartilage space prevents the infiltration of these cells [30]. Therefore, regenerative medicine helps to achieve this aim through the application of stromal vascular fraction (SVF), platelet-rich plasma (PRP) and stem cells in orthopaedics. Here, in this review, we aimed to discuss recent attempts about the use of SVF, PRP and stem cells in OA with a specific focus on clinical trial studies.

## *Stromal vascular fraction*

The ability of MSCs to differentiate into several cell lines such as chondrocytes makes them alternative treatment options in OA. Moreover, the anti-inflammatory effect of soluble factors released from these cells can halt cartilage destruction, a process that is created as the result of inflammation [31]. Those MSCs derived from adipose tissue (known as ADSC) gain several advantages over other tissue sources include abundance, the ease of harvest and stable phenotype after many culture passages [32]. Animal studies have proved the efficacy of ADSCs as a treatment option in OA and other related diseases.

The stromal vascular fraction (SVF), which is obtained after enzymatic digestion of adipose tissue, acts as a treatment choice and contains heterogeneous population of stem, progenitor and adult cells [33]. Those ADSCs available in SVF secrete several soluble factors with anti-inflammatory, immunomodulatory and analgesic effects. There are two approaches for delivery of SVF; intra-articular injection of cells suspended in platelet-rich plasma (PRP) and surgical implantation. In this regard, PRP has two advantages as an adjuvant. On the one hand, it provides growth factors to help better proliferation of stem cells, however, on the other hand, acts as scaffold for attaching cells to the site of cartilage damage. It has been reported that injection has several advantages over implantation including less invasiveness, better patient compliance and lower costs [34]. SVF has also its own advantages including the abundant stem cells it has, ease of extraction, availability of tissue supply and minimal invasiveness of the harvest procedure [15]. Nowadays, only one

randomized clinical trial is available for the application of SVF in orthopaedic situations [35]. Therefore, unlike successful results were achieved in many studies, no one can recognize SVF as a conventional treatment.

Almost all the studies evaluate the effect of SVF treatment on knee OA. A 3–36 months follow-up has shown improvements in pain and functional scores in all investigations. In 2011, Pak et al. conducted the first case-series that reported the efficacy of autologous SVF in OA patients. The visual analogue score (VAS), functional rating index (FRI) and range of motion (ROM) improved after three months, which is in line with cartilage regeneration [36]. In a retrospective cohort study, Pak and his colleagues injected SVF with PRP and HA into the knee, hip and femoral joints of patients with OA and observed the 50–60% improvement in ROM and VAS scores. Moreover, MRI has confirmed significant regeneration of cartilage defects. Similar efficacy of this combination has been reported at 3-month follow-up in this study. Some serious side effects such as swelling and tendonitis may somehow limit the SVF use in patients [37]. Kim et al. conducted another retrospective cohort study and found that SVF injection enhanced the efficacy of osteotomy regarding clinical outcomes. In some studies, the cartilage thickness increased as observed in MRI analysis [36,38,39]. Aside from injection approach, SVF implantation has been evaluated through second-look arthroscopy in different studies [40]. Again, all the studies showed improved condition, except one, which showed hyaline-like regenerative tissue in histological analysis of the joints. This observation was only seen in high-dose administration of SVF [38]. Koh et al. have conducted related studies for consecutive years. The study by Koh and Choi compared the effect of SVF with PRP alone, as treatment approach in control group. The authors have shown that SVF injection is safe; however, no significant difference in disease outcome has been reported between the groups [34]. In 2013, Koh et al. used autologous SVF and PRP after arthroscopic debridement in 18 patients with knee OA. The study has reported that this combination is safe and able to improve all related clinical criteria including VAS and Western Ontario and McMaster Universities Osteoarthritis (WOMAC) scores. No serious complications have also been reported upon treatment [39]. In another study by the same authors, outcomes from second-look arthroscopy and other clinical observations have shown that SVF plus PRP therapy mildly improved indices for pain and symptoms compared with another group who received PRP alone. Moreover, findings from arthroscopic examinations have shown more fibrocartilage regeneration in patients receiving SVF/PRP than PRP alone [40]. In a retrospective study in 2014, patients with knee OA received implanted ADSCs, which at first seemed to have great potential for treatment. However, second-look arthroscopy was shown that it had 76% success in repair [41]. Bui et al. conducted a case-series in 21 patients with knee OA who received SVF and PRP. The improved VAS and Lysholm scores, as well as increased cartilage thickness, have been reported after 8.5 months of treatment [38]. Another study in 2015 has reported improved cartilage defect in 63% of the patients who received autologous SVF. The treatment group have also shown better VAS, Lysholm and outcome

scores [40]. A multi-center case-control study by Michalek et al. in 2015 has been conducted in patients with knee and hip OA. Upon receiving autologous adipose SVF, no serious side effects were reported in these patients. Clinical symptoms such as pain, stiffness, analgesic usage and extent of joint movement were improved which was estimated 75% in 63% of the patients [42]. In 2016, Pak et al. have found that autologous adipose extra-cellular matrix, when used in combination with SVF and PRP, can increase the effectiveness of treatment. All FRI, ROM and VAS scores were improved after three months of treatment in patients [43]. Fodor et al. have reported full activity and decreased pain in eight OA patients after autologous SVF therapy. Improvements in WOMAC and VAS scores were maintained after 1 year; however, no detectable structural differences were observed in MRI [44]. According to study by Bansal et al., pain levels of those patients who received SVF plus PRP have been reduced, especially after 3 months. Moreover, combinations of these treatment approaches with traditional exercise can make better improvements in the quality of lives of the OA patients [35]. Despite the observed benefits in above studies, all of them classified as case series with some limitations. Since SVF is always suspended in a volume of PRP, there is no information regarding the regenerative effects of pure SVF in OA patients. Moreover, the optimum times and modality of administration remain unknown. This underscores the need for randomized, double blind and placebo-controlled clinical trials of SVF therapy in OA (Table 1).

### **Platelet-rich plasma**

Platelet-rich plasma (PRP) is an autologous plasma product, which has four to five times more platelets than unprocessed blood plasma. Those many growth factors and inflammatory mediators, which released upon activation from pooled platelets, make PRP be potentially effective in orthopaedics. Moreover, the acceptability, non-invasiveness, and safety profile increase demands of PRP use in patients with OA [45]. Evidence suggests that direct injection of PRP can control the inflammatory environment of the joint [46]. One of the molecular mechanisms by which PRP exerts this controlling effect is preventing the activation of nuclear factor (NF)- $\kappa$ B target genes [47]. The inflammatory environment in chondrocytes from patients with OA contains interleukin (IL)-1 $\beta$ , which stimulates NF- $\kappa$ B to inhibit synthesis of anabolic related genes such as type 2 collagen [48]. Moreover, IL-1 receptor antagonist has been concentrated in PRP to exert the anti-inflammatory effect. Other anti-inflammatory effects of PRP are related to growth factor components in it. Some of these growth factors have the ability to control the NF- $\kappa$ B, however, others can suppress the expression of special chemokine receptor on the surface of cells at the site of inflammation [49]. Moreover, PRP increases the synthesis of proteoglycans and collagen as the same levels as in normal chondrocytes [50].

Many studies have reported that PRP administration has positive effects on patients with knee OA. In 2012, Gobbi et al. had shown that intra-articular injection of autologous

**Table 1.** Chronological list of studies regarding the application of SVF, PRP and MSCs in patients with knee OA.

Type of therapy	Publication Year	Study type	Patient population	Study design	Follow-up	Outcome	References
SVF therapy	2011	Case-series	3 women 1 man	ADSC HA PRP Calcium chloride	3 months	Positive changes in MRI; Improvements in pain, physical therapy outcomes and functional status	[36]
	2012	Therapeutic case-control level III	25	SVF + PRP	12 months	Improved Lysholm, Tegner and VAS scores; no adverse side effects	[34]
	2013	Case-series	18	SVF + PRP	24.3 months	Improved WOMAC, Lysholm, VAS and whole-organ MRI scores	[39]
	2013	Retrospective cohort study	91	SVF + PRP	26.62 ± 0.32 months	SVF is safe; no tumor formation; self-limited tendonitis and swelling	[37]
	2014	Case-series	21	SVF + PRP	8.5 months	Improved joint function; Decreased pain score; Increased Lysholm score; Improved MRI findings; No serious side effects	[38]
	2015	Comparative study	30	SVF	3, 12, 24 months	Improved clinical outcomes after 2-year follow-up	[77]
	2015	Case-series	30	SVF + PRP	24 months	Improved clinical results and cartilage status under second-look arthroscopic analysis	[40]
	2015	Multi-center case-control study	1114	SVF	17.2 months	Improved pain score and functional status	[42]
	2016	Case report	3	SVF + PRP + HA + ECM	3.5 months	Improved FRI, ROM and VAS	[43]
	2016	Case report	6	SVF	12 months	Improved pain, functional status; no MRI evidence of cartilage regeneration	[44]
	2017	Clinical trial	10	SVF + PRP	3 months	Reduced WOMAC score; Improved cartilage thickness; safety of treatment	[35]
	PRP therapy	2012	Case-series	50	PRP	12 months	Improved pain, clinical scores and quality of life
2013		Prospective cohort study	22	PRP	12 months	Improved pain, functional and clinical scores	[78]
2013		Randomized controlled trial	78	PRP	6 months	Improved WOMAC score	[52]
2014		Systematic review and meta-analysis	1543	PRP vs. HA	6 to 24 months	Improved function; more effective than HA	[53]
2017		Meta-analysis	1069	PRP	Variable	Similar pain relief and functional improvement at 6 months; better improvements for PRP at 12 months; PRP is safe	[54]
2018		Meta-analysis	1520	PRP vs. HA	6, 12 months	Similar effectiveness between PRP and HA	[55]
2018		Randomized clinical trial	89	PRP vs. HA	3, 6 months	Better improvement in pain and functional status for PRP; Improved synovial hypertrophy and vascularity scores	[56]
2018		Randomized clinical trial	42	PRP vs. PRL	6 months	PRP is more effective than PRL regarding pain, stiffness and functional limitations	[57]
Stem cell therapy	2013	Double blinded controlled trial	40	Prior MP injection vs. PRP alone	1, 3, 6, 12 months	Better clinical outcomes in prior MP injection	[58]
	2013	Double blinded controlled trial	40	Autologous Ad-MSCs	6 months	Similar effectiveness in pain score compared to placebo	[70]
	2014	Double-blinded controlled trial	46	BM-MSCs	12, 24 and 36 weeks	Significant clinical improvement after MSC treatment	[66]
	2014	Double-blinded controlled trial	55	Allogenic MSCs	12 months	Meniscus regeneration and improved pain	[79]
	2014	Clinical trial	18	Ad-MSCs	6 months	Safety; Improved WOMAC score; decreased cartilage defect	[71]
	2015	Double-blinded controlled trial	30	Allogenic BM-MSC	12 months	Significant improvements in functional indices; more convenient than autologous MSCs	[67]
	2016	Clinical trial	60	BM-MSCs	1, 3, 6, 12 months	Reduced pain in patients and repaired damaged cartilage in rats	[68]
	2016	Phase I/II multicenter randomized clinical trial	30	Autologous BM-MSCs	12 months	Safety, clinical and functional improvement	[69]
2016	Phase I Dose-Escalation Trial	18	Ad-MSCs	6 months	Safety; Significant improvements in pain and function	[80]	

SVF: stromal vascular fraction; PRP: platelet-rich plasma; HA: hyaluronic acid; MRI: magnetic resonance imaging; VAS: visual analog scale; ECM: extracellular matrix; MSC: mesenchymal stem cell; ADSC: adipose-derived stem cell; WOMAC: Western Ontario and McMaster Universities osteoarthritis; FRI: functional rating index; ROM: range of motion; BM: bone-marrow; MP: methyl prednisone.

PRP in patients who experienced arthroscopic debridement and micro-fractures made significant improvement in disease activity and symptoms [51]. A total of 78 patients with bilateral OA enrolled into the trial and randomized into four intervention groups; single PRP injection, two PRP injections 3e weeks apart, single saline injection and placebo. Those who received two PRP injections had comparable effects regarding primary and secondary outcomes with single dose group. However, PRP had better results than saline in these patients [52]. According to a meta-analysis of five randomized controlled trials in 2014, which compared PRP with HA, PRP had more prolonged and better effectiveness than HA in patients who have degenerative knee OA [53]. In two recent similar meta-analyses, most of the studies have reported comparable outcomes between PRP and HA, however, the authors suggested that a large multicenter randomized trial is needed to determine the efficacy of PRP in OA patients [54,55]. The randomized clinical trial by Ahmad et al. have shown the efficacy of both PRP and HA regarding the reduced pain and improved functional status in patients. The authors suggested that even PRP made better results than HA. This trial has not been included in aforementioned recent meta-analyses and it does not have larger sample size than other included studies [56]. Very recent evidence compared the reducing effect of PRP and prolotherapy on pain and symptoms in patients with knee OA. An irritant solution like hypertonic dextrose is often injected in prolotherapy to stimulate proliferation of cells at the damaged site. In case of enthesitis, prolotherapy is more effective than PRP, however, findings from Rahimzadeh et al. study has reported that PRP is even more effective over time in treatment of OA patients. The authors have pointed out that the lack of control group, small sample size and lack of

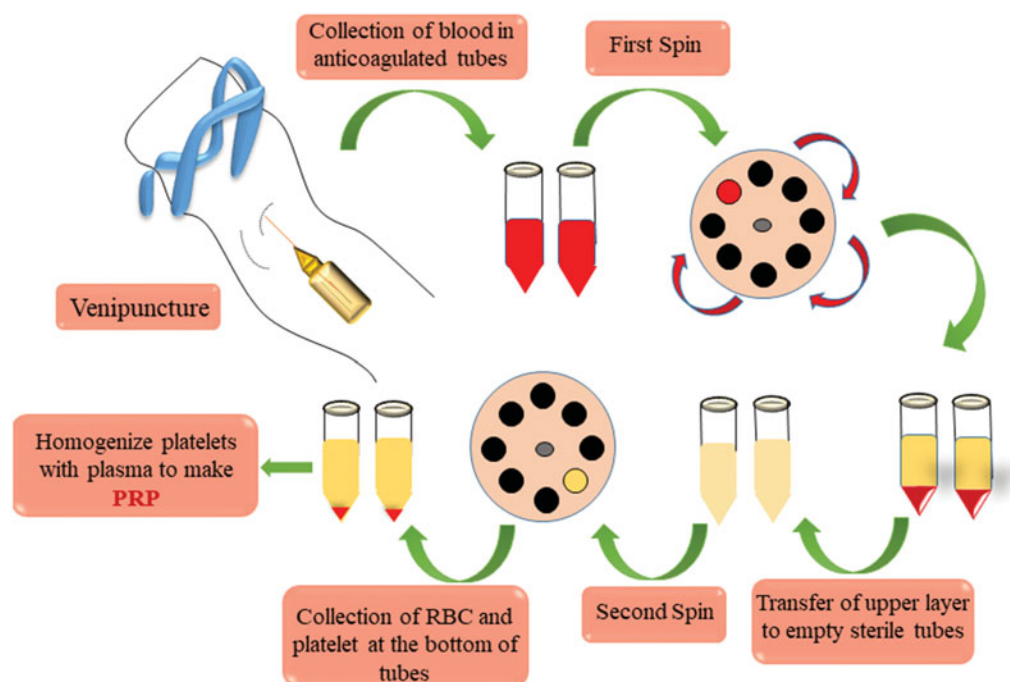
morphological assessments are among their study limitations [57]. As reported in a recent study, intra-articular injection of corticosteroids prior to PRP injection resulted in better outcomes in patients with mild to moderate OA [58].

Aside from studies including patients with knee OA, some randomized trials are also existed about other affected tissues like hip and ankle. To date, four studies compare PRP with HA in hip OA, which have conflicting results. This confliction has now been solved by a meta-analysis in 2018, which reported that PRP could reduce pain score at 2 months follow-up. However, this finding has not been approved at later months [59]. Just one study has pointed to the efficacy of PRP in patients with ankle OA, which again has shown that PRP can significantly reduce pain in these patients [60] (Figure 1).

Although unusual side effects have been reported for PRP, they are often mild and self-limited. Pain, allergic reactions and a grade of inflammatory response can be observed at the site of injection. If the aseptic conditions have not been considered during injection, infection can also be a serious side effect. Mild to moderate arthralgia is the most frequent event that often reported in patients, which can be resolved over time. Arthroscopic findings may report the hypertrophy of the cartilage tissue in some studies [61].

### Stem cells

Regeneration of the damaged cartilage is the main aim of therapy in degenerative osteoarticular diseases. There are a limited quantity of mesenchymal stem cells (MSCs) in normal joint fluid, which can differentiate into chondrocyte that further makes the new cartilage. However, this newly formed cartilage is fragile and easily destroyed by any minimal stress



**Figure 1.** Steps for PRP preparation. The first step is to collect around 20 mL of whole blood in anticoagulated vacutainer tubes. Then, place the blood-filled tubes on a specially prepared centrifuge to spin at  $600 \times g$  for 7 minutes. This results in formation of two phases, which the upper phase should be transferred to empty sterile tubes. In the next spinning stage, tubes are centrifuged at  $2000 \times g$  for 5 minutes. First RBCs and then platelets are deposited at the bottom of the tubes and one can homogenize the platelet layer to available plasma to make PRP.

on the joint. Therefore, the need still exists for the application of exogenous MSCs, which have several advantages include lack of need for biopsy and ease of injection in the therapeutic field of OA.

Due to immunomodulatory and regenerative capacities of MSCs, some clinical trials have addressed their use in cartilage repair. There are different protocols for MSC therapy in patients. In most of the cases, cells are isolated and culture-expanded prior to injection; however, in other cases, cells can be harvested at one stage and finally injected. SVF-derived MSCs are the best example for the latter protocol. Other formulations in this group include stem cells derived from lipoaspirate, aspirated concentrate of bone marrow (BM) and microfragmentation, which is a non-enzymatic approach for isolation of BM vascular niche [62]. In 2012, Koh et al. isolated stem cells from infrapatellar fat pad (IFP) and then injected them to knees of OA patients underwent arthroscopic debridement. This approach was considered safe, reduced pain levels and improved function after one-year follow-up in patients. Evidence suggests that those cells isolated from IFP source have high chondrogenic potential than other cells [34].

The local microenvironment of culture media can affect MSC differentiation and *in vitro* expansion of these cells may change the properties of injected MSCs. However, limited number of MSCs are available in one-stage harvest protocol [63]. Therefore, most research, as well as our discussion in this review, have been focused on culture-expanded cells. In 2008, Centeno et al. reported that the use of autologous culture-expanded bone marrow-derived stem cells (BM-SCs) could improve pain and ROM in individuals with degenerative joint disease [64]. In a prospective unblinded controlled trial by Wong et al., injection of autologous cultured BM-SCs in patients underwent high tibial osteotomy and microfracture resulted in better scores for primary and secondary outcomes, as indicated by International Knee Documentation Committee (IKDC), Tegner and Lysholm clinical scores [65]. Another study by Aghdami et al. indicated similar improvement of clinical scores in patients with moderate to severe knee OA who were followed-up for 9 months. The authors conducted a double-blinded placebo-controlled study, in which the control group received carrier media as placebo. Decreased subchondral oedema in some patients, as well as increased cartilage thickness in the treatment group, is another important observation in that study [66]. Vega et al. conducted another study in 30 patients who were not satisfied with traditional treatments. The authors were divided patients into two treatment groups: intra-articular injection of BM-SC or HA and followed them until 1-year. Symptom improvement was more obvious in BM-SC-receiving individuals and the damaged area in cartilage had significant reduction as seen in clinical imaging. Another finding in this study was that the allogenic MSC is better than autologous regarding the ease of use. Moreover, expansion of allogenic cells is cheaper than autologous. Immune rejection is the main limiting issue while working with these cells [67]. Gupta et al. have also tried allogenic MSCs at different doses to be injected in knees and found that 25-million-cell dose can effectively reduce pain; however, no changes have been

observed in imaging analysis [68]. In 2016, Espinosa et al. conducted a multicenter randomized controlled trial, in which individuals were randomly selected to receive autologous cultured BM-SCs or HA to assign either in treatment or control groups, respectively. All the participants were followed-up for 12 months, and the treatment group achieved good results especially in high-dose condition. Furthermore, radiographic evaluation has revealed reduced joint space only in control group. Joint damage was also decreased upon treatment [69].

Regarding studies on non-expanded stem cells, March et al. have observed that adipose-derived MSCs (Ad-MSCs) can reduce pain and improve symptoms in patients with knee OA [70]. One year later, Jo et al. decided to find the more appropriate strategy for treatment of generalized cartilage loss in OA. The study comprised two phases, which phase one included three dose-escalation cohorts and phase two began when patients received high doses of Ad-MSCs. Again, the primary and secondary outcomes, as well as the size of cartilage defect, have been improved in high-dose treatment group. In addition, histologic analysis has shown that hyaline-like cartilage regeneration was responsible for this improvement [71]. In a very recent study in 2018, a combination of *in-vitro* expanded Ad-MSCs with cell culture supernatant, known as progenza, was administered to patients with symptomatic knee OA. According to the findings, progenza was well-tolerated and induced significant improvements in patients. The authors claimed that any potential effect of progenza on disease modification warrants further studies [72].

## Limitations

There are some limitations regarding the application of PRP, SVF and stem cells in patients with OA. Most of the studies around the efficacy of PRP are case studies and preclinical investigations and few clinical trials are available in case of OA [73]. In addition, several protocols concerning the production of PRP exist; however, there is no consensus in methods that help us to select the gold standard. Some studies have declared that developing an antibody against bovine thrombin can initiate the activation of platelets [73]. Another issue that makes confusion is the dosage schedule of PRP in different studies [74]. SVF has many advantages that have been confirmed both *in vivo* and *in vitro* and those stem cells derived from SVF should fulfil the requirements of good manufacturing practices (GMPs) for clinical use. Other issues might be resolved before its application in clinics. What is the exact mechanism of action of ADSCs? How long do these cells stay in the joint to exert its local effects and which control group is more suitable to compare with SVF? Does SVF provide similar results if the source of adipose tissue obtained from obese individuals? Aside from the potential ability of MSCs in OA treatment, some limitations have been reported when using these cells. The availability of autologous cells might be scarce and tissue selection is important to minimize morbidity in patients. In addition, more

randomized clinical trials are required to better understand their positive impacts on patients with OA [75].

### Future perspectives and conclusion

The significant clinical burden of OA in populations highlights the importance of finding the most effective strategy for treatment. Cell-based therapies and regenerative medicine have provided effective results in the affected patients. PRP can reduce pain and improve functional status in the knee OA; however, imaging techniques have not pointed to any direct effect on cartilage. In addition, there is no calibration regarding the collection method and optimal treatment dosage of PRP in studies. Although SVF provides better quality of lives in OA patients, this kind of treatment is slightly aggressive to be used in humans. The efficacy of MSCs in cartilage repair is well established in animal, preclinical and phase I or II clinical studies. Other stem cell-based approaches such as the use of embryonic stem cells (ES) and induced pluripotent stem cells (iPS) are currently under investigation in animals. It has been reported that different tissue sources are available for iPS generation and using iPS is less invasive than MSC in regenerative medicine [76]. Finally, the efficacy of such treatments, as well as new stem cell-based approaches in OA, need to be confirmed by further controlled long-termed studies.

### Disclosure statement

No potential conflict of interest was reported by the authors.

### References

- [1] Man GS, Mologhianu G. Osteoarthritis pathogenesis – a complex process that involves the entire joint. *J Med Life*. 2014;7:37–41.
- [2] Palazzo C, Nguyen C, Lefevre-Colau M-M, et al. Risk factors and burden of osteoarthritis. *Ann Phys Rehabil Med*. 2016;59:134–138.
- [3] Cibrian Uhalte E, Wilkinson JM, Southam L, et al. Pathways to understanding the genomic aetiology of osteoarthritis. *Hum Mol Genet*. 2017;26:R193–R201.
- [4] Loeser RF, Collins JA, Diekman BO. Ageing and the pathogenesis of osteoarthritis. *Nat Rev Rheumatol*. 2016;12:412–420.
- [5] Attur M, Krasnokutsky S, Statnikov A, et al. Low-grade inflammation in symptomatic knee osteoarthritis: prognostic value of inflammatory plasma lipids and peripheral blood leukocyte biomarkers. *Arthritis Rheumatol*. (Hoboken, NJ). 2015;67:2905–2915.
- [6] Wang Y, Zhao X, Lotz M, et al. Mitochondrial biogenesis is impaired in osteoarthritis chondrocytes but reversible via peroxisome proliferator-activated receptor gamma coactivator 1alpha. *Arthritis Rheumatol* (Hoboken, NJ). 2015;67:2141–2153.
- [7] Hui W, Young DA, Rowan AD, et al. Oxidative changes and signalling pathways are pivotal in initiating age-related changes in articular cartilage. *Ann Rheum Dis*. 2016;75:449–458.
- [8] Carames B, Taniguchi N, Otsuki S, et al. Autophagy is a protective mechanism in normal cartilage, and its aging-related loss is linked with cell death and osteoarthritis. *Arthritis Rheum*. 2010;62:791–801.
- [9] Mobasheri A, Matta C, Zakany R, et al. Chondrosenescence: definition, hallmarks and potential role in the pathogenesis of osteoarthritis. *Maturitas*. 2015;80:237–244.
- [10] Loeser RF. Aging and osteoarthritis: the role of chondrocyte senescence and aging changes in the cartilage matrix. *Osteoarthritis Cartilage*. 2009;17:971–979.
- [11] Altman RD, Gold GE. Atlas of individual radiographic features in osteoarthritis, revised. *Osteoarthritis Cartilage*. 2007;15: A1–56.
- [12] Teichtahl AJ, Wang Y, Smith S, et al. Structural changes of hip osteoarthritis using magnetic resonance imaging. *Arthritis Res Therap*. 2014;16:466.
- [13] Demehri S, Guermazi A, Kwok CK. Diagnosis and longitudinal assessment of osteoarthritis: review of available imaging techniques. *Rheum Dis Clin North Am*. 2016;42:607–620.
- [14] Kandahari AM, Yang X, Dighe AS, et al. Recognition of immune response for the early diagnosis and treatment of osteoarthritis. *J Immunol Res*. 2015;2015:1.
- [15] Gibbs N, Diamond R, Sekyere EO, et al. Management of knee osteoarthritis by combined stromal vascular fraction cell therapy, platelet-rich plasma, and musculoskeletal exercises: a case series. *J Pain Res*. 2015;8:799–806.
- [16] Felson DT. Clinical practice. Osteoarthritis of the knee. *N Engl J Med*. 2006;354:841–848.
- [17] Ettinger WH, Jr., Burns R, Messier SP, et al. A randomized trial comparing aerobic exercise and resistance exercise with a health education program in older adults with knee osteoarthritis. The Fitness Arthritis and Seniors Trial (FAST). *JAMA*. 1997;277:25–31.
- [18] Messier SP, Loeser RF, Miller GD, et al. Exercise and dietary weight loss in overweight and obese older adults with knee osteoarthritis: the Arthritis, Diet, and Activity Promotion Trial. *Arthritis Rheum*. 2004;50:1501–1510.
- [19] Bottegoni C, Muzzarelli RA, Giovannini F, et al. Oral chondroprotection with nutraceuticals made of chondroitin sulphate plus glucosamine sulphate in osteoarthritis. *Carbohydr Polym*. 2014; 109:126–138.
- [20] Phillips S, Li CS, Phillips M, et al. Treatment of osteoarthritis of the knee with bracing: a scoping review. *Orthop Rev (Pavia)*. 2016;8:6256.
- [21] Gaffney K, Ledingham J, Perry JD. Intra-articular triamcinolone hexacetonide in knee osteoarthritis: factors influencing the clinical response. *Ann Rheum Dis*. 1995;54:379–381.
- [22] Hochberg MC, Altman RD, April KT, et al. American College of Rheumatology 2012 recommendations for the use of nonpharmacologic and pharmacologic therapies in osteoarthritis of the hand, hip, and knee. *Arthritis Care Res (Hoboken)*. 2012;64:465–474.
- [23] Mori S, Naito M, Moriyama S. Highly viscous sodium hyaluronate and joint lubrication. *Int Orthop*. 2002;26:116–121.
- [24] El-Hakeim EH, Elawamy A, Kamel EZ, et al. Fluoroscopic guided radiofrequency of genicular nerves for pain alleviation in chronic knee osteoarthritis: a single-blind randomized controlled trial. *Pain Phys*. 2018;21:169–177.
- [25] Kim DH, Choi SS, Yoon SH, et al. Ultrasound-guided genicular nerve block for knee osteoarthritis: a double-blind, randomized controlled trial of local anesthetic alone or in combination with corticosteroid. *Pain Phys*. 2018;21:41–52.
- [26] de l'Escalopier N, Anract P, Biau D. Surgical treatments for osteoarthritis. *Ann Phys Rehabil Med*. 2016;59:227–233.
- [27] Van Manen MD, Nace J, Mont MA. Management of primary knee osteoarthritis and indications for total knee arthroplasty for general practitioners. *J Am Osteopath Assoc*. 2012;112:709–715.
- [28] Kirkley A, Birmingham TB, Litchfield RB, et al. A randomized trial of arthroscopic surgery for osteoarthritis of the knee. *N Engl J Med*. 2008;359:1097–1107.
- [29] Zhang W, Ouyang H, Dass CR, et al. Current research on pharmacologic and regenerative therapies for osteoarthritis. *Bone Res*. 2016;4:15040.
- [30] Hunziker EB. Articular cartilage repair: basic science and clinical progress. A review of the current status and prospects. *Osteoarthritis Cartilage*. 2002;10:432–463.
- [31] Dimarino AM, Caplan AI, Bonfield TL. Mesenchymal stem cells in tissue repair. *Front Immunol*. 2013;4:201.
- [32] Strioga M, Viswanathan S, Darinskas A, et al. Same or not the same? Comparison of adipose tissue-derived versus bone marrow-derived mesenchymal stem and stromal cells. *Stem Cells Dev*. 2012;21:2724–2752.



- [33] Yoshimura K, Shigeura T, Matsumoto D, et al. Characterization of freshly isolated and cultured cells derived from the fatty and fluid portions of liposuction aspirates. *J Cell Physiol.* 2006;208:64–76.
- [34] Koh YG, Choi YJ. Infrapatellar fat pad-derived mesenchymal stem cell therapy for knee osteoarthritis. *Knee.* 2012;19:902–907.
- [35] Bansal H, Comella K, Leon J, et al. Intra-articular injection in the knee of adipose derived stromal cells (stromal vascular fraction) and platelet rich plasma for osteoarthritis. *J Transl Med.* 2017;15:141.
- [36] Pak J. Regeneration of human bones in hip osteonecrosis and human cartilage in knee osteoarthritis with autologous adipose-tissue-derived stem cells: a case series. *J Med Case Rep.* 2011;5:296.
- [37] Pak J, Chang JJ, Lee JH, et al. Safety reporting on implantation of autologous adipose tissue-derived stem cells with platelet-rich plasma into human articular joints. *BMC Musculoskelet Disord.* 2013;14:337.
- [38] Van Pham P, Bui KH-T, Duong TD, et al. Symptomatic knee osteoarthritis treatment using autologous adipose derived stem cells and platelet-rich plasma: a clinical study. *Biomed Res Therap.* 2014;1:2.
- [39] Koh YG, Jo SB, Kwon OR, et al. Mesenchymal stem cell injections improve symptoms of knee osteoarthritis. *Arthroscopy.* 2013;29:748–755.
- [40] Koh YG, Choi YJ, Kwon SK, et al. Clinical results and second-look arthroscopic findings after treatment with adipose-derived stem cells for knee osteoarthritis. *Knee Surg Sports Traumatol Arthrosc.* 2015;23:1308–1316.
- [41] Koh YG, Choi YJ, Kwon OR, et al. Second-look arthroscopic evaluation of cartilage lesions after mesenchymal stem cell implantation in osteoarthritic knees. *Am J Sports Med.* 2014;42:1628–1637.
- [42] Michalek J, Moster R, Lukac L, et al. WITHDRAWN: autologous adipose tissue-derived stromal vascular fraction cells application in patients with osteoarthritis. *Cell Transpl.* 2015;20:1–36.
- [43] Pak J, Lee JH, Park KS, et al. Regeneration of cartilage in human knee osteoarthritis with autologous adipose tissue-derived stem cells and autologous extracellular matrix. *BioRes Open Access.* 2016;5:192–200.
- [44] Fodor PB, Paulseth SG. Adipose derived stromal cell (ADSC) injections for pain management of osteoarthritis in the human knee joint. *Aesthet Surg J.* 2016;36:229–236.
- [45] Xie X, Zhang C, Tuan RS. Biology of platelet-rich plasma and its clinical application in cartilage repair. *Arthritis Res Ther.* 2014;16:204.
- [46] Sun Y, Feng Y, Zhang CQ, et al. The regenerative effect of platelet-rich plasma on healing in large osteochondral defects. *Int Orthop (Sicot).* 2010;34:589–597.
- [47] van Buul GM, Koevoet WL, Kops N, et al. Platelet-rich plasma releasate inhibits inflammatory processes in osteoarthritic chondrocytes. *Am J Sports Med.* 2011;39:2362–2370.
- [48] Wu CC, Chen WH, Zao B, et al. Regenerative potentials of platelet-rich plasma enhanced by collagen in retrieving pro-inflammatory cytokine-inhibited chondrogenesis. *Biomaterials.* 2011;32:5847–5854.
- [49] Bendinelli P, Matteucci E, Dogliotti G, et al. Molecular basis of anti-inflammatory action of platelet-rich plasma on human chondrocytes: mechanisms of NF- $\kappa$ B inhibition via HGF. *J Cell Physiol.* 2010;225:757–766.
- [50] Krüger JPHS, Endres M, Pruss A, et al. Human platelet-rich plasma stimulates migration and chondrogenic differentiation of human subchondral progenitor cells. *J Orthop Res.* 2012;30:845–852.
- [51] Gobbi A, Karnatzikos G, Mahajan V, et al. Platelet-rich plasma treatment in symptomatic patients with knee osteoarthritis: preliminary results in a group of active patients. *Sports Health.* 2012;4:162–172.
- [52] Patel S, Dhillon MS, Aggarwal S, et al. Treatment with platelet-rich plasma is more effective than placebo for knee osteoarthritis: a prospective, double-blind, randomized trial. *Am J Sports Med.* 2013;41:356–364.
- [53] Chang KV, Hung CY, Aliwarga F, et al. Comparative effectiveness of platelet-rich plasma injections for treating knee joint cartilage degenerative pathology: a systematic review and meta-analysis. *Arch Phys Med Rehabil.* 2014;95:562–575.
- [54] Dai WL, Zhou AG, Zhang H, et al. Efficacy of platelet-rich plasma in the treatment of knee osteoarthritis: a meta-analysis of randomized controlled trials. *Arthroscopy.* 2017;33:659–670.e1.
- [55] Zhang H-f, Wang C-g, Li H, et al. Intra-articular platelet-rich plasma versus hyaluronic acid in the treatment of knee osteoarthritis: a meta-analysis. *Dddt.* 2018;12:445–453.
- [56] Ahmad HS, Farrag SE, Okasha AE, et al. Clinical outcomes are associated with changes in ultrasonographic structural appearance after platelet-rich plasma treatment for knee osteoarthritis. *Int J Rheum Dis.* 2018;21:960–966.
- [57] Rahimzadeh P, Imani F, Faiz SHR, et al. The effects of injecting intra-articular platelet-rich plasma or prolotherapy on pain score and function in knee osteoarthritis. *Clin Interv Aging.* 2018;13:73–79.
- [58] Camurcu Y, Sofu H, Ucpunar H, et al. Single-dose intra-articular corticosteroid injection prior to platelet-rich plasma injection resulted in better clinical outcomes in patients with knee osteoarthritis: a pilot study. *J Back Musculoskelet Rehabil.* 2018;31:603–610.
- [59] Ye Y, Zhou X, Mao S, et al. Platelet rich plasma versus hyaluronic acid in patients with hip osteoarthritis: a meta-analysis of randomized controlled trials. *Int J Surg (London, England).* 2018;53:279–287.
- [60] Fukawa T, Yamaguchi S, Akatsu Y, et al. Safety and efficacy of intra-articular injection of platelet-rich plasma in patients with ankle osteoarthritis. *Foot Ankle Int.* 2017;38:596–604.
- [61] Filardo G, Kon E, Pereira Ruiz MT, et al. Platelet-rich plasma intra-articular injections for cartilage degeneration and osteoarthritis: single- versus double-spinning approach. *Knee Surg Sports Traumatol Arthrosc.* 2012;20:2082–2091.
- [62] Barry F, Murphy M. Mesenchymal stem cells in joint disease and repair. *Nat Rev Rheumatol.* 2013;9:584.
- [63] Bara JJ, Richards RG, Alini M, et al. Concise review: bone marrow-derived mesenchymal stem cells change phenotype following in vitro culture: implications for basic research and the clinic. *Stem Cells.* 2014;32:1713–1723.
- [64] Centeno CJ, Busse D, Kisiday J, et al. Increased knee cartilage volume in degenerative joint disease using percutaneously implanted, autologous mesenchymal stem cells. *Pain Physician* 2008;11:343–353.
- [65] Wong KL, Lee KB, Tai BC, et al. Injectable cultured bone marrow-derived mesenchymal stem cells in varus knees with cartilage defects undergoing high tibial osteotomy: a prospective, randomized controlled clinical trial with 2 years' follow-up. *Arthroscopy.* 2013;29:2020–2028.
- [66] Aghdami N, Liastani MG, Emadedin M, et al. Repeated intra articular injection of bone marrow derived mesenchymal stem cell in knee osteoarthritis: double blind randomized clinical trial. *Cytotherapy.* 2014;16:S14.
- [67] Vega A, Martin-Ferrero MA, Del Canto F, et al. Treatment of knee osteoarthritis with allogeneic bone marrow mesenchymal stem cells: a randomized controlled trial. *Transplantation.* 2015;99:1681–1690.
- [68] Gupta PK, Chullikana A, Rengasamy M, et al. Efficacy and safety of adult human bone marrow-derived, cultured, pooled, allogeneic mesenchymal stromal cells (Stempeucel®): preclinical and clinical trial in osteoarthritis of the knee joint. *Arthritis Res Therap.* 2016;18:301.
- [69] Lamo-Espinosa JM, Mora G, Blanco JF, et al. Intra-articular injection of two different doses of autologous bone marrow mesenchymal stem cells versus hyaluronic acid in the treatment of knee osteoarthritis: multicenter randomized controlled clinical trial (phase I/II). *J Transl Med.* 2016;14:246.
- [70] March L, Hunter D, Ward C, et al. A randomised placebo controlled pilot study of autologous non-expanded adipose-derived

- mesenchymal stem cells in the treatment of knee osteoarthritis. *Intern Med J.* 2013;43:4–5.
- [71] Jo CH, Lee YG, Shin WH, et al. Intra-articular injection of mesenchymal stem cells for the treatment of osteoarthritis of the knee: a proof-of-concept clinical trial. *Stem Cells.* 2014;32:1254–1266.
- [72] Kuah D, Sivell S, Longworth T, et al. Safety, tolerability and efficacy of intra-articular Progenza in knee osteoarthritis: a randomized double-blind placebo-controlled single ascending dose study. *J Transl Med.* 2018;16:49.
- [73] Choi J, Minn KW, Chang H. The efficacy and safety of platelet-rich plasma and adipose-derived stem cells: an update. *Arch Plast Surg.* 2012;39:585–592.
- [74] Dhillon MS, Patel S, John R. PRP in OA knee – update, current confusions and future options. *Sicot J.* 2017;3:27.
- [75] Pers YM, Ruiz M, Noel D, et al. Mesenchymal stem cells for the management of inflammation in osteoarthritis: state of the art and perspectives. *Osteoarthritis Cartilage.* 2015;23:2027–2035.
- [76] Willard VP, Diekman BO, Sanchez-Adams J, et al. Use of cartilage derived from murine induced pluripotent stem cells for osteoarthritis drug screening. *Arthritis Rheumatol (Hoboken, NJ).* 2014;66:3062–3072.
- [77] Kim YS, Choi YJ, Suh DS, et al. Mesenchymal stem cell implantation in osteoarthritic knees: is fibrin glue effective as a scaffold? *Am J Sports Med.* 2015;43:176–185.
- [78] Halpern B, Chaudhury S, Rodeo SA, et al. Clinical and MRI outcomes after platelet-rich plasma treatment for knee osteoarthritis. *Clin J Sport Med.* 2013;23:238–239.
- [79] Vangsness CT, Jr., Farr J, 2nd, Boyd J, et al. Adult human mesenchymal stem cells delivered via intra-articular injection to the knee following partial medial meniscectomy: a randomized, double-blind, controlled study. *J Bone Joint Surg Am.* 2014;96:90–98.
- [80] Pers YM, Rackwitz L, Ferreira R, et al. Adipose mesenchymal stromal cell-based therapy for severe osteoarthritis of the knee: a phase I dose-escalation trial. *Stem Cells Transl Med.* 2016;5:847–856.