

Patellofemoral Ligament Reconstruction in a Patient with *Rubinstein–Taybi Syndrome*

Fardin Mirzatolouei^{1*}

¹ Department of Orthopedic Surgery, Faculty of Medicine, Urmia University of Medical Sciences, Urmia, Iran

Received: 1 Jan. 2013; Accepted: 30 Apr. 2013

Abstract- Recurrent dislocation of patella may occur in patients with ligament laxity. Method of treatment in this condition is controversial but patellofemoral ligament reconstruction is the most accepted method. We present a patient with *Rubinstein–Taybi* syndrome and recurrent patellar dislocation who managed successfully by patellofemoral ligament reconstruction.

© 2014 Tehran University of Medical Sciences. All rights reserved.

Acta Medica Iranica, 2014;51(3):228-230.

Keywords: Congenital patella dislocation; Rubinstein-Taybi syndrome; Patellofemoral ligament; Instability

Introduction

The *Rubinstein–Taybi* syndrome is a rare congenital syndrome characterized by mental retardation, broad thumbs and big toes, and a specific face with a small mouth, beaked nose, hypertelorism, epicanthus, long eyelashes, short neck, , and hypoplastic nasal alae (1-4). Orthopedic surgeons are involved in this syndrome because of thumb deformities and also generalized ligamentous laxities (5). This ligamentous laxity may be presented in knee joint in form of patellar subluxation or dislocation. Type and results of treatment of recurrent patellar dislocation in *Rubinstein–Taybi* syndrome have significance both in *Rubinstein–Taybi* syndrome and other generalized ligamentous laxities complicated by knee cap dislocation.

Case Report

A fourteen years old girl was referred to an orthopedic clinic because of left knee pain and multiple falling downs. In general appearance she had dysmorphic facies with micrognathia, mental retardation and broad thumbs and halluces (Figure 1). The first falling down was occurred three years ago and she was managed with four weeks casting and rehabilitation program. Her old chart didn't show impression of Rubinstein-Taybi syndrome but her mental retardation was recorded. The second falling down was occurred 6 months later but she was not referred. Gradually the numbers of falling down were increased and interval between them decreased.

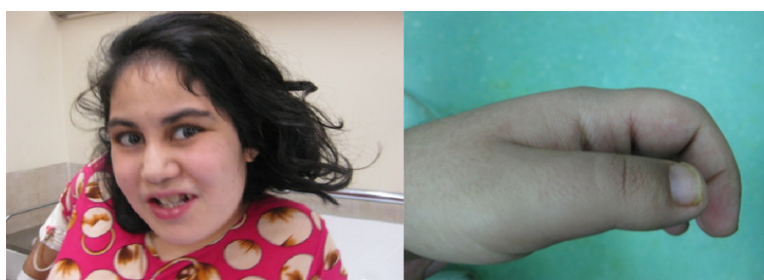

Figure 1. Patient has dystrophic face and broad thumb

On clinical examination, patient had short stature with a characteristic face including small mouth long eyelashes and beaked nose. Her behavior was indicative of mental retardation but she was polite and charming. The left knee showed full range of motion. Limbs

alignment and collateral and cruciates ligament examinations were unremarkable. Q angle was 25 degrees in both sides. External rotation of the tibia was normal. Apprehension test was strongly positive and knee cap was grossly dislocated in examination. Right

Corresponding Author: F. Mirzatolouei

Urmia University of Medical Sciences, Imam Khomeini hospital, Urmia, Iran
Tel: +98 9141435104, Fax: +98 441 3469935, E-mail address: fardin_tolouei@yahoo.com

knee was normal except for positive patellar apprehension test. Radiogram of the lower left extremity showed closed distal femoral physis and mild valgus deformity of the knee of approximately 20°. In AP view

lateral subluxation of patella in left knee was apparent. MRI showed normal knee except for shallow patellar groove and lateral patellar subluxation (figure2).

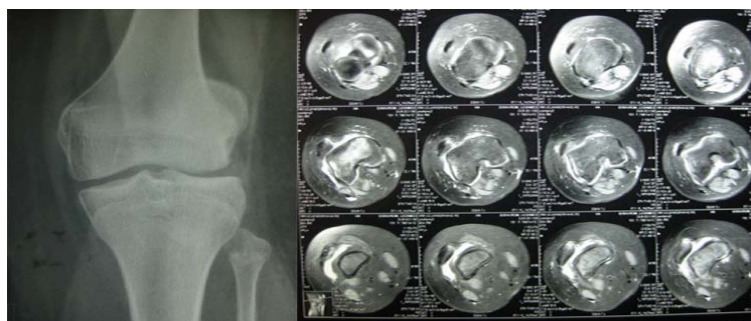


Figure2. Subluxed patella in AP radiography and MRI

She underwent open patellofemoral ligament reconstruction using gracilis tendon graft. Intraoperatively, patient had small patella and hematoma over insertion of patellofemoral ligament on patella. Femoral side isometric point was achieved and the graft fixed to femur using a bioabsorbable screw. On the first follow-up two weeks after operation the slab was removed by patient and she had 100° knee flexion. Six week after operation she had full weight bearing and 130° flexion. One year later patient had normal patellar alignment and negative apprehension test (Figure 3).

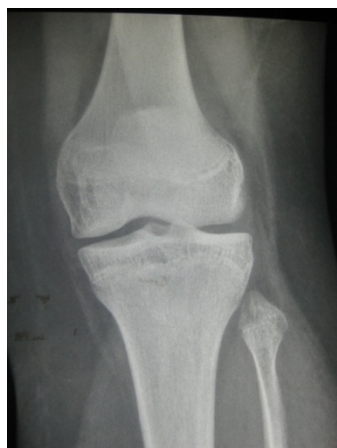

Figure 3. Corrected position of patella 5 months later

Discussion

Recurrent dislocation of the patella, as described in the literature, is found either isolated or associated with other syndromes, such as Down syndrome. In *Rubinstein-Taybi* syndrome, patellofemoral instability is estimated to be as frequent as 3.4% (6). In the presented case the patient had bilateral positive patellar

apprehension test more pronounced in left side. Recurrent patellar dislocation is a multifactorial condition in which the main factor is patellofemoral ligament insufficiency. Our surgical findings were in favor of patellofemoral avulsion from medial patellar border. Patellofemoral ligament reconstruction corrected this insufficiency and returned patient to her normal level of activities.

Anesthesiological complications including pneumonia or cardiovascular collapse have been reported in *Rubinstein-Taybi* syndrome. This can be due to valve or septal defects. Intraoperative and postoperative course of our patient was unremarkable. Most of these complications have been reported in younger kids.

Ochs *et al.* has reported aplasia of Posterior cruciate ligament and congenital dislocation of patella in a patient with *Rubinstein-Taybi* syndrome (7). Ceynowa and Mazurek also reported congenital dislocation of patella in a newborn (8). Our patient didn't have any congenital knee problem. Her knee was stable for anteroposterior and mediolateral directions. We emphasize that the patella in this case was smaller than expected and produced some difficulties in passing of graft through patella.

Patients with *Rubinstein-Taybi* syndrome may develop recurrent patellar dislocation. In our patient Patellofemoral ligament reconstruction corrected this problem successfully.

References

1. Rubinstein JH, Taybi H. Broad thumbs and toes and facial abnormalities. A possible mental retardation syndrome. *Am J Dis Child* 1963;105(6):588-608.
2. Rao SK, Fan DS, Pang CP, et al. Bilateral congenital

- corneal keloids and anterior segment mesenchymal dysgenesis in a case of Rubinstein-Taybi Syndrome. *Cornea* 2002;21(1):126-30.
3. Bloch-Zupan A, Stachtou J, Emmanouil D, et al. Oro-dental features as useful diagnostic tool in Rubinstein-Taybi Syndrome. *Am J Med Genet A* 2007;143(6):570-3.
 4. Stevens CA, Bhakta MG. Cardiac abnormalities in the Rubinstein-Taybi Syndrome. *Am J Med Genet* 1995;59(3):346-8.
 5. Mehlman CT, Rubinstein JH, Roy DR. Instability of patellofemoral joint in *Rubinstein-Taybi* Syndrome. *J Pediatr Orthop* 1998;18(4):508-11.
 6. Deie M, Ochi M, Adachi N, et al. Medial patellofemoral ligament reconstruction fixed with a cylindrical bone plug and a grafted semitendinosus tendon at the original femoral site for recurrent patellar dislocation. *Am J Sports Med* 2011;39(1):140-5.
 7. Ochs BG, Schmelzer-Schmied N, Carstens C, et al. Fixed posterior subluxation with lateral rotation of the knee joint caused by congenital dislocation of the patella in combination with aplasia of the posterior cruciate ligament. Case report and review of the literature. *Orthopade* 2005;34(4):356-61.
 8. Ceynowa M, Mazurek T. Congenital patella dislocation in a child with Rubinstein-Taybi syndrome. *J Pediatr Orthop B* 2009;18(1):47-50.