

Cyclosporine a induces testicular injury via mitochondrial apoptotic pathway by regulation of mir-34a and sirt-1 in male rats: The rescue effect of curcumin

Amir Mohammad Ghazipour^a, Alireza Shirpoor^{b,c}, Rafighe Ghiasi^{d,e}, Bagher Pourheydar^{f,g}, Naser Khalaji^c, Roya Naderi^{b,c,*}

^a Student Research Committee, Urmia University of Medical Sciences, Urmia, Iran

^b Nephrology and Kidney Transplant Research Center, Urmia University of Medical Sciences, Urmia, Iran

^c Department of Physiology, Faculty of Medicine, Urmia University of Medical Sciences, Urmia, Iran

^d Drug Applied Research Center, Tabriz University of Medical Sciences, Tabriz, Iran

^e Department of Physiology, Tabriz Faculty of Medical Science Tabriz University of Medical Sciences, Tabriz, Iran

^f Neurophysiology Research Center, Urmia University of Medical Sciences, Urmia, Iran

^g Department of Anatomical Sciences, Faculty of Medicine, Urmia University of Medical Sciences, Urmia, Iran

ARTICLE INFO

Keywords:

Cyclosporine A
Testis
Apoptosis
Curcumin
Mir-34a
Sirt-1

ABSTRACT

Testicular damage contributes to cyclosporine A (CsA) induced male infertility. However, the exact underlying molecular mediators involved in CsA-induced testis disorder remains unclear. The present study aimed to characterize the role of mir-34a/sirt-1 in CsA induced testicular injury alone or in combination with curcumin. A total of twenty-eight male Wistar rats were subdivided into four groups: control (Con), sham, cyclosporine A (CsA), cyclosporineA + curcumin (CsA + cur). The animals received cyclosporine A (30 mg/kg) and curcumin (40 mg/kg) for 28 days by oral gavage. At the end of the experiment, CsA administration significantly resulted in a decrease in testis weight and testis coefficient. The molecular analysis demonstrated that CsA exposure increased 8-OHdg and Nox4 protein contents in the testis tissue. TUNEL staining indicated that CsA caused the number of apoptotic cells to increase in the testes of male rats. In addition, exposure to CsA resulted in an increased expression of Bax, and a decreased expression in that of Bcl-2, with a concomitant up-regulation of the Bax/Bcl-2, c-Caspase-3/p-Caspase-3 ratio and cytochrome c level. Meanwhile, exposure to CsA increased the expression of mir-34a and decreased sirt-1 protein level in the testis tissue samples compared to the control group. Taken together, our findings suggested that CsA can cause damage to testicular germ cells via oxidative stress and mitochondrial apoptotic pathway, and probably mir-34a/sirt-1 play a crucial role in this process. It also demonstrates that these negative effects of CsA can be reduced by using curcumin as an antioxidant and anti-inflammatory agent.

1. Introduction

Cyclosporine A (CsA) is a powerful immunosuppressive agent that has been isolated from the fungus *Tolypocladium inflatum Gams* [1]. Currently, it is typically used for patients who receive organ transplants and also in the treatment of autoimmune diseases [2]. Nevertheless, it has been reported that CsA can have serious side effects in multiple

organs, including the reproductive system [1]. Previous studies have demonstrated that long-term use of CsA induces testicular and spermatozoal toxicity as manifested by the disruption of morphology and vitality of sperms through a variety of mechanisms [1,3]. Oxidative stress which is induced by excessive generation of reactive oxygen species (ROS) [4] induces the peroxidation of sperm membrane lipids, DNA breakage, and decreased sperm motility, leading to infertility

Abbreviations: CsA, cyclosporine A; Bax, Bcl2-associated X; Bcl-2, B-cell lymphoma-2; c-Caspase-3, cleaved Caspase-3; p-Caspase-3, pro Caspase-3; ROS, reactive oxygen species; miRNAs, microRNAs; mir-34a, mirRNA34a; sirt-1, sirtuin 1; NIH, National Institutes of Health; Con, Control; 8-OHdg, 8-hydroxy-2'-deoxyguanosine; DMSO, Dimethyl sulfoxide solution; Nox4, NADPH oxidase 4; HRP, Horseradish Peroxidase; TUNEL, Terminal deoxynucleotidyl transferase dUTP nick-end labeling; FFPE, formalin-fixed paraffin-embedded; MDA, malondialdehyde; GSH, Glutathione; GSH-PX, Glutathione peroxidase; CAT, Catalase; NO, nitric oxide

* Corresponding author. Nephrology and Kidney Transplant Research Center, Urmia University of Medical Sciences, Urmia, Iran.

E-mail address: naderi.r@umsu.ac.ir (R. Naderi).

<https://doi.org/10.1016/j.cbi.2020.109180>

Received 14 April 2020; Received in revised form 2 June 2020; Accepted 15 June 2020

Available online 20 June 2020

0009-2797/ © 2020 Elsevier B.V. All rights reserved.

[5,6]. Since there are high levels of polyenoic fatty acids in testicular membranes, the testis is particularly susceptible to oxidative damage [7]. CsA administration induces oxidative stress and subsequent testicular damage accompanied by dysplasia of sperm and spermatogenic cells [5]. Moreover, CsA markedly induces the impairment of testosterone synthesis and DNA damage, and increases the apoptotic index of germinal cells in seminiferous tubules, resulting in testicular toxicity [3,5]. There are two main apoptotic pathways, including intrinsic and extrinsic. Both of these signaling pathways are involved in testicular germ cell apoptosis in various conditions [8,9], but the main lethal apoptotic pathway in CsA treatment involves mitochondrial damage [10]. Accordingly, the exact molecular mechanisms that underlie the testicular damage during CsA treatment are not fully understood yet.

MicroRNAs (miRNAs) are small non-coding RNAs that play crucial roles in various biological processes, including proliferation, differentiation, apoptosis, and the response to cellular stress [11]. Regulation of several protein-coding genes in response to stress-generating agents can be mediated by alterations in the expression of many miRNAs [12]. Accumulating evidence has revealed the significance of miRNAs as a novel perspective in the regulation of spermatogenesis and male fertility [13–15]. MirRNA34a (mir-34a) is a member of the mir-34 family which is highly expressed in the testis [16]. This miRNA is an oxidative stress-responsive short non-coding RNA that deals with disadvantageous situations [12] in which a high enough stress can trigger testicular apoptosis, ultimately leading to infertility [1]. Recently, it has been indicated that mir-34a plays an important role in spermatogenesis and the function of spermatozoa [17,18]. Moreover, mir-34a and its target gene sirtuin 1 (sirt-1) contribute to testicular apoptosis, affecting almost every key cellular function [19]. Sirt-1 is a member of a large sirtuin family undergoing histone deacetylase activity which is known as a regulator of cell death/survival and stress response [20]. It is documented that sirt-1 prevents apoptosis and alleviates oxidative cellular damage and DNA degradation, thereby promoting cell viability [21]. In light of this information, mitigating oxidative stress and apoptosis may be a pivotal therapeutic target for attenuating the damage induced by CsA treatment.

Recently, it has been shown that various phytochemicals derived from herbs and spices possess powerful antioxidant activity. Thus, they may play a strong role in protecting organs against various disorders in controlling the generation of free radical species [22,23].

Curcumin originates from the plant *Curcuma longa* (turmeric) and, possesses various biological activities such as antioxidant, anti-inflammatory, anti-cancer, anti-apoptotic, and anti-mutagenic effect [24]. Several studies have reported the protective effects of curcumin in experimental investigations against testicular toxicity, thereby establishing the antioxidant and anti-apoptotic properties of curcumin [25–28]. Curcumin exhibits renoprotective effects against cisplatin-induced nephrotoxicity via modulating oxidative stress and increasing sirt-1 protein expression [29]. In addition, curcumin has been shown to inhibit apoptosis through modulating Bax/Bcl-2 expression and improving oxidative stress in the testes of streptozotocin-induced diabetic rats [30]. However, no data has been provided on the effect of curcumin in testicular injury induced by CsA administration.

Therefore, this study evaluated the effect of CsA treatment on oxidative stress and apoptosis probably mediated by mir-34a/sirt-1 pathway in rats' testes. It also sought to examine whether curcumin mitigates the testicular disturbances induced by CsA administration.

2. Materials and methods

2.1. Animals and conditions

All procedures were approved by Urmia University of Medical Sciences Animal Care Committee, Ministry of Health, Iran (IR.UMSU.REC.1398.276) and performed in strict accordance to the National Institutes of Health (NIH) Guide, for laboratory animals' care.

The animals maintained at 12-h light cycle with controlled temperature (23 °C–25 °C) and free access to food and water. Twenty-eight male Wistar rats (weighing 10 ± 220 g; aged 6–8 weeks) were randomly allocated into four groups (n = 7):

1. Control (Con): The animals were treated with tap water as a vehicle daily for 28 days.
2. Sham: The animals were treated with Dimethyl sulfoxide solution (5% DMSO) by gastric gavage daily for 28 days.
3. Cyclosporine A (CsA, Sandimmune®, New Jersey): The animals were treated with CsA (30 mg/kg) [24] diluted in DMSO by gastric gavage daily at morning (8:00 Am) for 28 days.
4. Cyclosporine A + curcumin (CsA + cur, Merck, India). The animals were treated with CsA (30 mg/kg) (8:00 Am) and cur (40 mg/kg) (10:00 Am) [31] diluted in DMSO by gastric gavage daily for 28 days.

At the end of twenty-eight days, the rats were weighted and anesthetized with ketamine (60 mg/kg) and xylazine (6 mg/kg) [32], then the testicular tissues were dissected, washed and dried by a filter paper, and weighed to calculate the organ coefficient of the testis (testis coefficient = weight of testis/body weight \times 100). A part of the right testis freed by liquid nitrogen, and stored at deep freeze (-80 °C) for gene and protein measurement (Real-time PCR and western blot), and the other part, was homogenized (10% w/v) in 50 mM Tris-HCl (pH 7.4). The homogenate was centrifuged at $5000 \times g$ for 10 min at 4 °C and obtained supernatant was stored at -80 °C for biochemical analysis (8-OHdG and cytochrome c). The protein level was evaluated according to the Lowry method [33] by bovine serum albumin as a standard. In addition, left testis was fixed in a 10% buffered formalin solution for tunnel staining.

2.2. ELISA

For estimation the testicular content of 8-hydroxy-2'-deoxyguanosine (8-OHdG) and cytochrome c, the supernatant sample was used by the quantitative sandwich enzyme immunoassay method using a related ELISA kit (China; Cat. NO. CSB-E10526r) and (China; Cat. NO. CSB-EL006328RA) in accordance to the manufacturers' instructions [6,34]. Accordingly, micro-plates were covered with a particular protein antibody. Then, standards and samples were drawing off with a pipette into the wells, and any special protein present was attached by an immobilized antibody. After dispelling all unbound substances, a biotin-conjugated Horseradish Peroxidase (HRP) was added to the wells. Then, a substrate solution was added into the wells to develop a color which was in proportion to the amount of protein bounded. After stopping the color development, the intensity of the color was assessed.

2.3. Western blot

Sirt-1, (NADPH oxidase 4) Nox4, (Bcl2-associated X) Bax, (B-cell lymphoma-2) Bcl2, cleaved Caspase-3 (c-Caspase-3) and pro Caspase-3 (p-Caspase-3) protein levels in the testicular tissue were determined by Western immunoblotting as described in our previous study [35]. In order to extract total protein, the tissue immersed in the RIPA lysis buffer with PMSF (Beyotime). The protein concentration was measured by the Bradford assay kit (Sigma-Aldrich, USA) and loaded into each well, then separated by SDS-PAGE. Within an hour, all the loaded samples transferred to the PVDF membrane. After blocking with 5% skim milk buffer containing 0.1% Tween 20, the membranes were incubated with primary antibodies overnight at 4 °C in a shaker incubator.

The primary antibodies included anti-sirt-1 (catalog number sc-74465, 1:500 dilution, SANTA CRUZ), anti-Nox4 (catalog number sc-21860, 1:500 dilution, SANTA CRUZ), anti-Bax (catalog number sc-7480, 1:500 dilution, SANTA CRUZ), anti-Bcl-2 (catalog number sc-492, 1:500 dilution, SANTA CRUZ) or anti-Caspase-3 (catalog number

14220, 1:1000 dilution, Cell Signaling). Then the membranes incubated with horseradish peroxidase-conjugated secondary antibody. The intensity of the bands was analyzed with Image J software (IJ 1.46r version, NIH, USA). Final results presented as a ratio of the target protein to β -actin protein.

2.4. Real-time PCR

miRNA was extracted from testis tissue using miRCURYTM RNA isolation kit (Exiqon, Vedbaek, Denmark) according to the protocol provided by the manufacturer. The RNA concentration and purity were determined by Nanodrop 1000 spectrophotometer (Thermo scientific, Wilmington, DE 19810 USA). The expression profile of microRNA was carried out on total RNA extracts using a cDNA synthesis kit. In brief, total RNA was polyadenylated and cDNA was synthesized using a poly (T) primer with a 3 degenerate anchor and a 5 universal tag (Exiqon, Vedbaek, Denmark). Provided cDNA was utilized as a template for quantitative real-time PCR of microRNA by taking advantage of the standard SYBR Green master mix (Exiqon, Vedbaek, Denmark) [36]. Real-time PCR reactions were analyzed with a Bio-Rad iQ5 detection System (Bio-Rad, Richmond, CA, USA). For miRNA RT-PCR, U6 was used as endogenous control and the relative expression of miRNA was calculated by $2^{-\Delta\Delta Ct}$ method [37,38]. The results were expressed as the fold-change to the relevant controls. The following primers were used: mir-34a forward, 5-CAATCAGCAAGTATACTGCCCT-3; mir-34a reverse, 5-CCAGTGCAGGGTCCGAGGTA-3; U6 sense: 5-GCTTCGGCAGCACATA TACTAAAT-3; and U6 antisense: 3-CGCTTCACGAATTGCGTGTCAT-5. Sequences were derived from GenBank. The primers were verified using Gene Runner software (Syngene, Cambridge, UK). The specificity of the novel primer sets checked by Oligo 7 software.

2.5. TUNEL staining

Apoptosis of the testicular tissue was detected by the terminal deoxynucleotidyl transferase (TdT) dUTP nick-end labeling (TUNEL) assay [35]. Sections (5- μ m thick) of formalin-fixed paraffin-embedded (FFPE) testis tissue were used for TUNEL staining with In Situ Cell Death Detection Kit (Roche Molecular Chemical, cat. number 11684817910). The slides were deparaffinized, rehydrated, and covered with 20 mg/mL proteinase K (Roche, Germany) for 15 min. Endogenous peroxidase activity was blocked via 3% hydrogen peroxide. Sections were then incubated 50 μ L of TUNEL solution (In Situ Cell Death Detection Kit, Roche, Germany) for 1 h at 37 °C. Staining was revealed using 3,3-diaminobenzidine (DAB, Sigma, Germany) chromogen. The slides were then rinsed in water and mounted. Finally, the sections were examined by a light microscope [39].

Apoptotic index = (number of labeled cells/total number of cells counted) \times 100.

2.6. Statistical analysis

All data were presented as mean \pm SEM using SPSS software version 16. Comparisons were carried out by one way ANOVA followed by Tukey's post-hoc test. $P < 0.05$ was assumed to be statistically significant.

3. Results

3.1. Body weight and testis weight

The comparisons of the body weight, testicular weight and testicular coefficient after 28 days of treatment are shown in Table 1. There was no significant difference in body weight among the groups at the beginning of this study (data not shown). There was a significant decrease ($p < 0.001$) in body weight and both testes (measured together) weight in the CsA group compared to the control and sham. The

testicular coefficient was lower in the CsA group than in the control and sham groups ($p < 0.001$). However, after 28 days of treatment, body weight and testes weights in the CsA + cur group were significantly ($p < 0.05$) higher than those in the CsA group. Also, testis coefficient markedly increased ($p < 0.05$) by curcumin treatment.

3.2. 8-OHdG and cytochrome c in the testicular tissue

Exposure to CsA resulted in a significant ($p < 0.001$) increase of the testis 8-OHdG content (32.31 ± 1.05) compared to that of the control (4.6 ± 0.42) and sham (4.86 ± 0.48) groups (Fig. 1a). In addition, there was a significant ($P < 0.001$) increase in cytochrome c (470 ± 51) in the testis of CsA treated rats as compared to the control (140 ± 21) and sham (168 ± 19) groups (Fig. 1b). Co-administration of curcumin along with CsA markedly reduced the 8-OHdG (28.74 ± 0.47) ($p < 0.01$) and cytochrome c (312 ± 23) ($p < 0.05$) content compared to that of the CsA group.

3.3. Sirt-1, Nox4, Bax, Bcl2, c-caspase-3 and p-caspase-3 protein levels in the testicular tissue

To estimate the effect of CsA and curcumin treatment on sirt-1, Nox4, Bax, Bcl-2, Bax/Bcl2 ratio, and Caspase-3 activation, western blot analysis was performed in testicular tissue obtained from different groups of study after 28 days of treatment. Based on the present western blot results, CsA treatment significantly ($P < 0.001$) decreased sirt-1 (0.275 ± 0.01) and increased Nox4 (3.65 ± 0.17) protein expression in the testes compared to the control (1 ± 0.0) group (Fig. 2 a, b, c). However, curcumin treatment alleviated sirt-1 (0.33 ± 0.01) ($P < 0.01$) and Nox4 (3.15 ± 1.06) ($P < 0.05$) protein expressions in the testes of CsA treated animals. Then, we further investigated the role of CsA in the intrinsic apoptotic pathway, namely the 'mitochondria apoptotic pathway', which has been shown to be critical in regulating apoptosis. We analyzed the expression of Bax and Bcl-2 and calculated the ratio of Bax/Bcl-2 in testicular tissue. Anti-apoptotic protein Bcl-2 as a key member in the Bcl-2 family, suppresses apoptosis however, Pro-apoptotic protein Bax could promote apoptosis. As shown in Fig. 3a and b, exposure to CsA increased the Bax protein expression and decreased Bcl-2 protein expression in CsA treated rats. So, the Bax/Bcl-2 ratio was increased (30.09 ± 3.94) in CsA treated rats compared to control (0.98 ± 0.03) and sham (1.03 ± 0.04) group ($P < 0.001$), which were reversed by curcumin administration (7.09 ± 0.88) ($P < 0.001$). This result indicates that Bcl-2 family members are involved in curcumin-induced anti-apoptosis in CsA-treated rats. As an important mediator of apoptosis, in this study, we investigated the enzymatic activity of the c-Caspase-3 with respect to p-Caspase-3 conducting a western blot analysis. As it was shown in Fig. 3 a and c, c-Caspase 3/p-Caspase 3 protein level notably enhanced in the CsA group (7.21 ± 0.58) in comparison with control (1.01 ± 0.0) and sham (1.04 ± 0.06) animals ($P < 0.001$). Nonetheless, curcumin administration could alleviate this ratio (7.09 ± 0.88) in the testes of CsA treated animals ($P < 0.001$).

3.4. Mir-34a expression in the testicular tissue

As shown in Fig. 4 RT-qPCR results were employed to find out the expressions of mir-34a in testicular tissues of rats in different groups. Our data exhibited significant increase ($P < 0.001$) in the expression levels of mir-34a in animals treated with CsA (12.1 ± 0.68) when compared with control (1 ± 0.0) and sham (1.35 ± 0.26) groups, while the expression of mir-34a was markedly ($P < 0.001$) down-regulated in curcumin-treated rats (1.46 ± 0.27) and returned to a normal state.

Table 1
Body and testis weight of rats at the end of experiment.

Groups	Con	Sham	CsA	CsA + cur
Body Weight (g)	301 ± 5.7	295 ± 5.2	211 ± 13.03***	252 ± 9.1\$
Testis Weight(g)	3.07 ± 0.07	3.05 ± 0.06	1.97 ± 0.1***	2.43 ± 0.09\$
testis coefficient	1.01 ± 0.02	1.02 ± 0.02	0.8 ± 0.03***	0.92 ± 0.02\$

All data are expressed as mean ± SEM (n = 7); ***P < 0.001 vs control and sham groups. \$ P < 0.05 vs CsA group. Con: control, CsA: cyclosporine A, CsA + cur: cyclosporine A + curcumin.

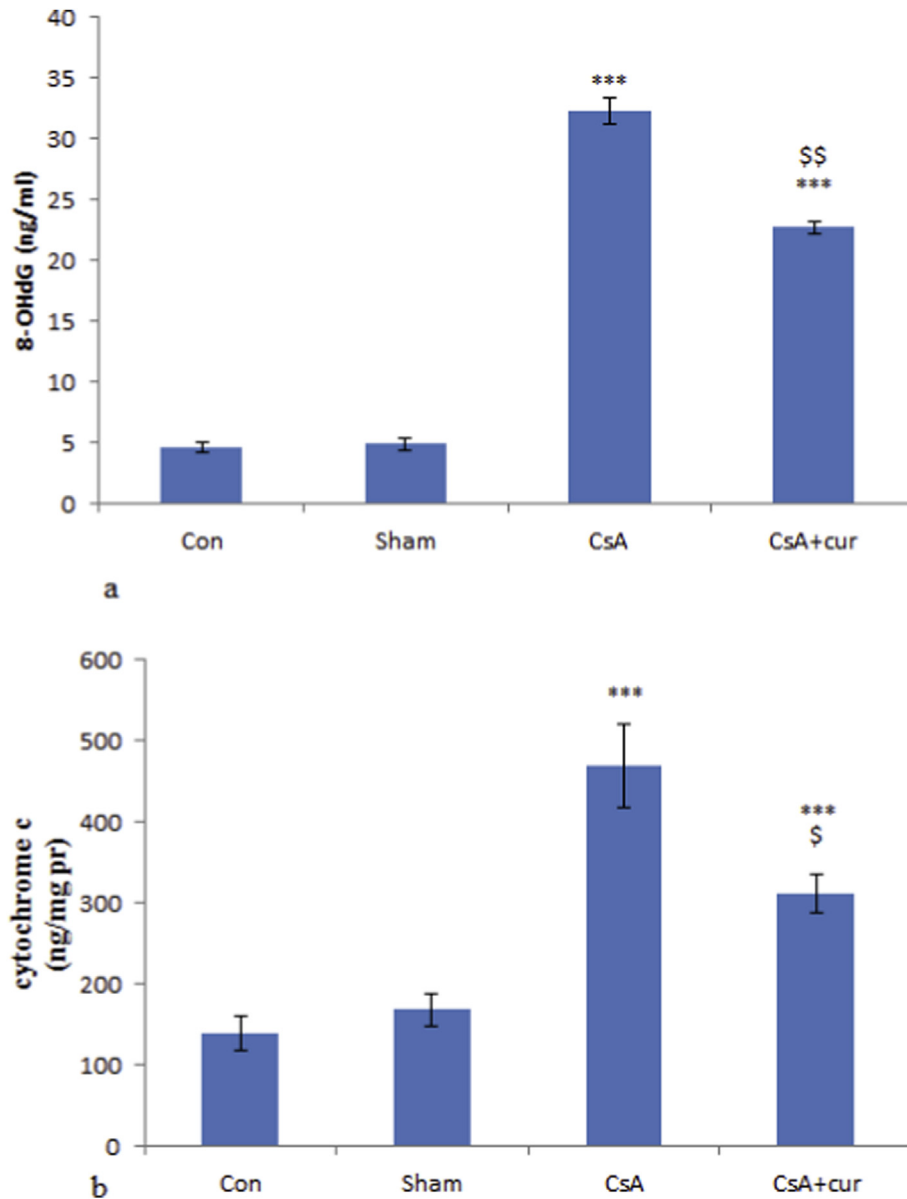


Fig. 1. The effect of CsA treatment on the 8-OHdG (a) and cytochrome c (b) levels in the testicular tissue in different groups. ***P < 0.001 vs con and sham groups, \$ P < 0.05, \$\$ P < 0.01 vs CsA group. All data are expressed as the mean ± SEM (n = 7).

3.5. Apoptotic cells in the testicular tissue

The apoptosis of testicular tissue was analyzed by a TUNEL assay. The TUNEL positive cells as the indicator of apoptosis were rarely identified in control and DMSO group, whereas a significant increase (p < 0.001) of positive cells was exhibited in the testes of CsA group

(11.92 ± 0.7) compared with the control (1 ± 0.0) and DMSO (1.45 ± 0.4) groups. Importantly, when compared with the CsA group, curcumin treatment (10.2 ± 0.3) significantly (p < 0.05) reduced the number of TUNEL-positive cells (Fig. 5 a, b).

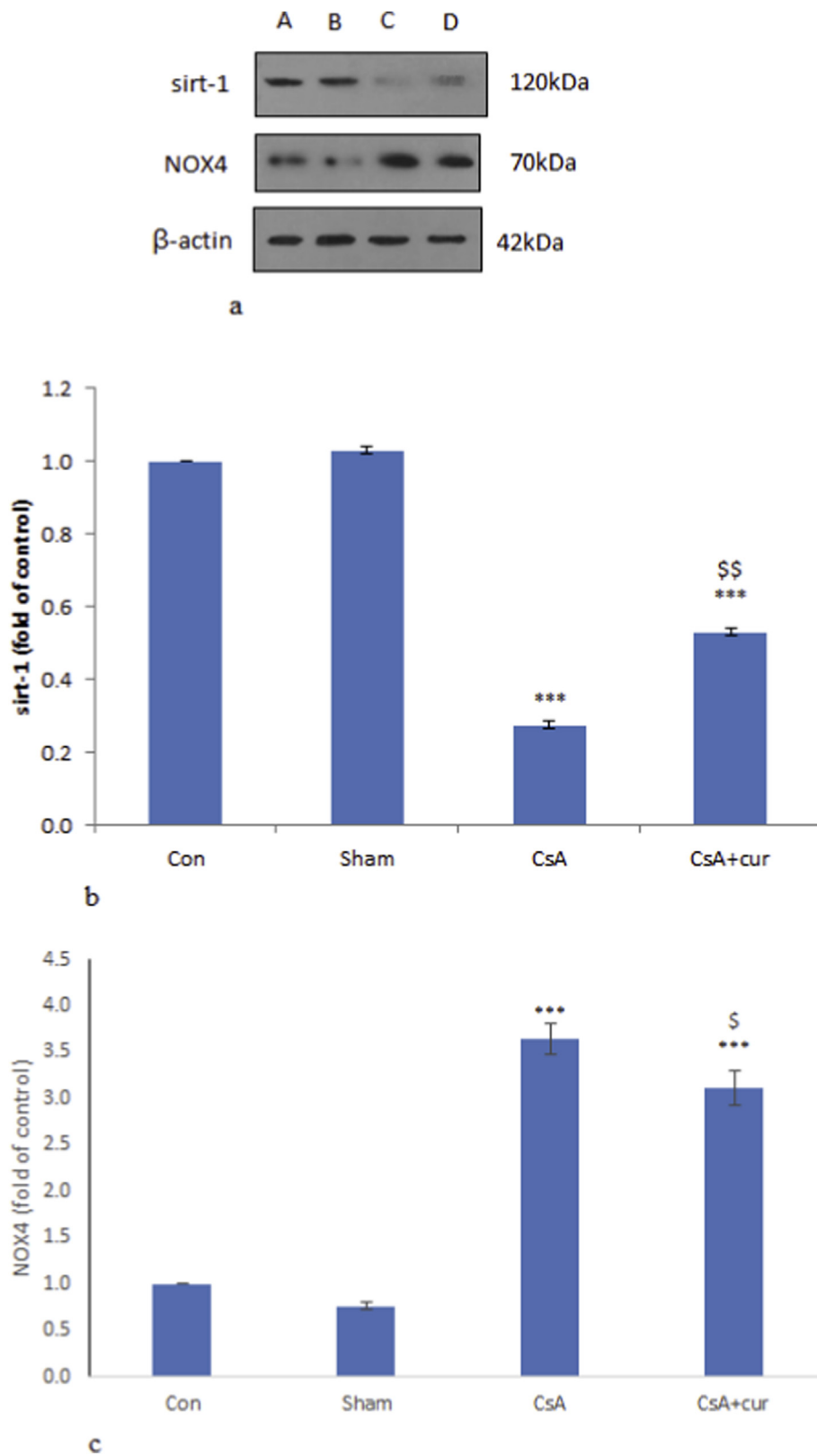


Fig. 2. The effect of CsA treatment on the sirt-1 and Nox4 protein expressions in the testicular tissue of all experimental groups. The blotting images of sirt-1 and Nox4 (a). The bar charts represent the quantitative analysis of the protein levels of sirt-1 and Nox4 (b, c) normalized against β -actin. All data are expressed as the mean \pm SEM (n = 7). ***p < 0.001 vs con and sham groups; \$ p < 0.05, \$\$ p < 0.01 vs CsA group.

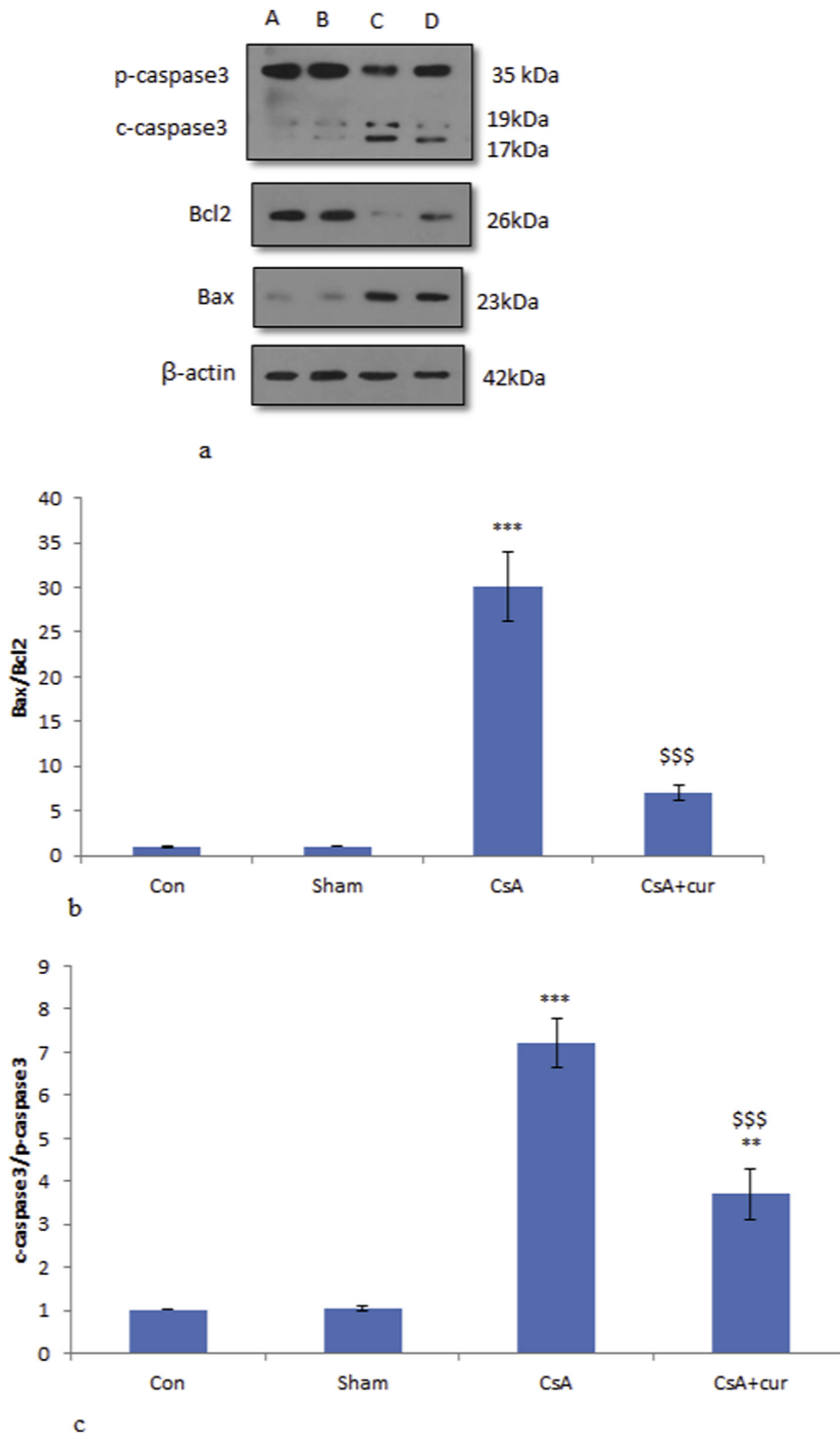


Fig. 3. The effect of CsA treatment on the Bax, Bcl2 and also c-Caspase-3, p-Caspase-3 protein expressions in the testicular tissue of all experimental groups. The blotting images of Bax and Bcl2 and also c-Caspase-3, p-Caspase-3 (a). The bar charts represent the quantitative analysis of the Bax/Bcl-2 ratio and c-Caspase-3/p-Caspase-3 protein level (b, c) normalized against β -actin. All data are expressed as the mean \pm SEM (n = 7). **p < 0.01, ***p < 0.001 vs con and sham groups; \$ \$ \$ p < 0.001 vs CsA group.

4. Discussion

Although there have been few reports on the morphological and functional impairments to testicular tissue affecting sperm quality caused by CsA exposure, none has specifically focused on the possible

mechanism of testicular toxicity in response to CsA treatment leading to male infertility.

The major findings of the present study were that after long-term exposure to CsA: (i) CsA could affect the reproductive system of rats with weight loss, decreased testicular weight, and testis coefficient; (ii)

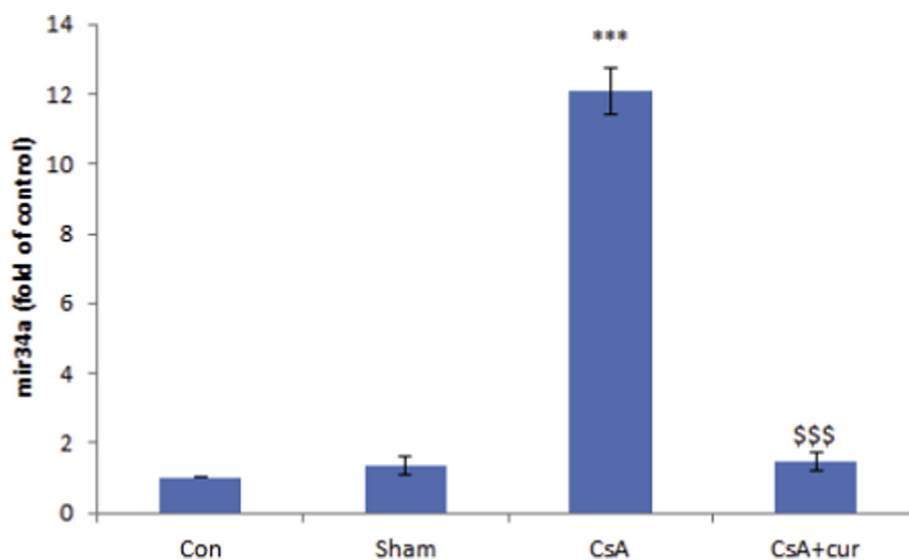


Fig. 4. The effect of CsA treatment on the mir-34a gene expression in the testicular tissue in different groups. *** $P < 0.001$ vs con group and sham groups, \$\$\$ $P < 0.001$ vs CsA group. All data are expressed as the means \pm SEM ($n = 7$).

CsA administration led to a significant increase in 8-OHdG and Nox4 levels as an oxidative stress manifestation in the testes of male rats; (iii) an increase in testicular apoptotic cells was observed in CsA-treated rats as evidenced by an increased Bax (therefore, an increased ratio of Bax/Bcl-2), a decreased Bcl-2 expression, and a concomitantly increased ratio of c-caspase3/p-caspase3 in the CsA-treated group compared to the control group; (iv) further molecular analysis showed that CsA elevated mir-34a gene expression and decreased sirt-1 protein level in the testes of male rats. Moreover, significant amelioration of oxidative stress manifestations and apoptosis indices was observed in the curcumin-treated animals. These alterations were probably mediated through the mir-34a/sirt-1 pathway.

Some studies have reported contradictory results on testicular weight [1,5,38]. CsA administration alone caused a significant reduction in testicular weight in the present study, which can be attributed to the sensitivity of rats used in different studies. The reduction in testicular weight and testis coefficient may be explained by CsA-induced testis atrophy mediated by ROS production, subsequently decreasing testosterone production [39]. Turk et al. reported that CsA caused testicular structural and functional disruptions including reduced sperm concentration and motility, an increased abnormal sperm rate, and decreased diameter of seminiferous tubules and germinal cell thickness of the testes, as well as degeneration, necrosis, interstitial edema, desquamative germinal cells, and the deceleration of spermatogenesis. These testicular abnormalities are associated with oxidative stress as evidenced by a significant increase in MDA (malondialdehyde) level, and a decrease in GSH (glutathione) level and GSH-PX (glutathione peroxidase) and CAT (catalase) activities [5]. Therefore, oxidative stress as a result of excessive generation of oxygen radicals or impairment of antioxidant systems is a powerful cause of testicular toxicity [1].

Nox4 is one of the principal sources of ROS generation in several tissues contributing to oxidative stress [40–43]. It belongs to the members of the Nox family of NADPH oxidases which is generally considered the predominant source of ROS through redox signaling regulators [44]. It is more general than those of some other Nox enzymes which are extensively expressed in many other cell types including the testes [44–46]. The increased Nox4 activity in these tissues may critically contribute to the formation of ROS, leading to oxidative stress [44,46]. It was clearly exhibited that Nox4 is a pro-oxidant gene and structurally active, playing a critical role in the toxicity of toxicant agents by accelerating the reaction of the production of nitric oxide

(NO) and superoxide free radicals [47]. Mohammadi et al. demonstrated that a high expression of Nox4 in Mancozeb (as a fungicide)-treated rats may result in oxidative stress in the testes of male albino mice [48]. Increased Nox4 also has been shown in children with undescended testes [46] and in diabetic reproductive damage [49]. This is the first study that examines Nox4 levels in CsA-treated rats. The Nox4 levels were significantly higher following CsA exposure as determined in our study.

Another finding of the present study was the significant increase in oxidative DNA damage in the testes of the CsA-treated group compared to control and sham groups. This undesirable effect is manifested by a high level of 8-OHdG in CsA treatment [5]. The 8-OHdG level is a ubiquitous marker of oxidative stress which shows the endogenous oxidative damage to DNA [50]. It is generally considered as a biomarker of mutagenesis consequent to oxidative stress due to disturbances in the macromolecular structure. This potential marker of DNA damage is formed from oxidation a hydroxyl group that is added to the 8th position of the guanine molecule, known as 8-OHdG [51]. Studies exhibited that 8-OHdG elevation positively contributes to poor semen quality, infertility, and birth defects, thereby having a negative relationship with reproductive success [52]. Previously, it was reported that exposure to CsA results in a remarkable increase in spermatozoa DNA damage and a significant decrease in fertilization rate [53]. Since 8-OHdG is a kind of DNA oxidation production which has the slowest repair kinetics, it is the most popular adduct originating in the DNA oxidative process [54].

Hence, oxidative stress induction in this study, indicated by elevated expression of 8-OHdG and Nox4 protein levels, contributes to testicular damage following CsA treatment.

A growing body of evidence has demonstrated that ROS production is clearly responsible for inducing apoptosis [49,55]. Apoptosis has a deleterious effect on testicular tissue and leads to irreversible damage to spermatogenesis [49]. Pan et al. have reported increased DNA breakage and a marked elevation in spermatogenic apoptotic cells in CsA-treated mice [55]. To provide mechanistic insight into molecular aspects of CsA-induced apoptosis, in the present study, we examined mitochondrial apoptotic molecular alterations which were approved as a main lethal apoptotic pathway in CsA-induced cell death [10]. Our analysis for the first time revealed that CsA administration increases Bax and caspase 3 and decreases Bcl-2 protein expressions, thereby increasing the ratio of Bax/Bcl-2 in the testis tissues, wherein the number of TUNEL-stained cells also concomitantly increased.

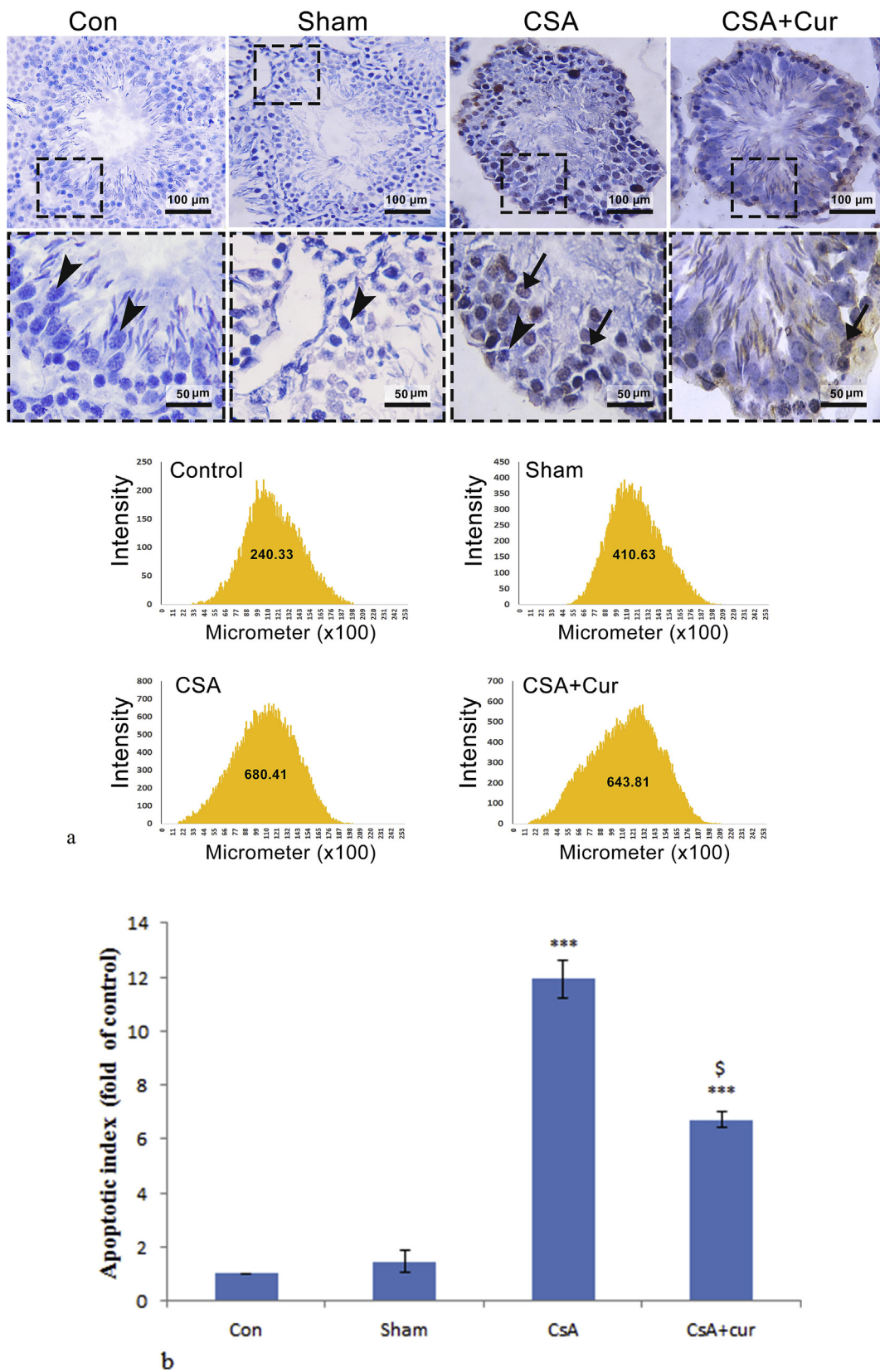


Fig. 5. Assessment of apoptosis in different groups. a) Images of apoptotic cells in the testicular tissue of rats treated with CsA with TUNEL staining. CsA exposure caused an increased number of apoptotic cells in the testicular tissue (black arrow). Magnification $\times 400$. b) Quantitative analysis of the apoptotic index (percentage of TUNEL-positive nuclei, %). All data are expressed as the mean \pm SEM (n = 7). ***p < 0.001 vs con and sham groups; \$ p < 0.05 vs CsA group. Scale bars are as indicated.

The mitochondrial, or intrinsic, apoptotic pathway is modulated by the members of the Bcl-2 protein family [56]. Bcl-2 family proteins consist of anti-apoptotic and pro-apoptotic proteins which are critical apoptotic regulators, involved in cell death. The pro-apoptotic Bax stimulates cytochrome *c* release and caspase activation, contributing to cell apoptosis, which could be counteracted by Bcl-2, an anti-apoptotic protein [57]. An increased ratio of Bax/Bcl-2 may activate caspase 3 which is a critical mediator of apoptosis, resulting in apoptosis [57].

Mir-34a is documented as a pro-apoptotic microRNA in various cell types [16]. Guo et al. [58] found that mir-34a knockout leads to a significant increase in progressive sperm motility in zebrafish. Some genes including apoptotic (p53) and anti-apoptotic (Bcl2 and sirt1) genes have been revealed to be mir-34a targets [59]. Mir-34a could stimulate apoptosis by down-regulating anti-apoptotic proteins [59]. Mir-34a was proved to modulate sirt1 expression at the transcription level. Sirt1 is a class III protein deacetylase and can modulate DNA function through histone deacetylation and influence several transcription factors such as those controlling ROS generation, e.g. FoxO pathways [60]. It appears that free radicals leading to oxidative stress can, in turn, control the activity of sirt1 [61]. Recently, the critical role of mir-34a/sirt-1 pathway was established in testicular apoptotic cell death induced by diabetes [11].

Interestingly, in this study, we observed that the up-regulation of mir-34a expression in the testes of CsA-treated animals was associated with a reduction in sirt-1 protein level.

Considering the above, our results suggest that CsA administration induces oxidative stress and apoptosis via the mir-34a/sirt-1 signaling pathway. These findings classify redox-sensitive, mitochondrial apoptotic pathway, and mir-34a/sirt-1 alterations as novel mechanisms causing CsA-induced testicular toxicity.

The second point addressed in this study was that the protective effects are likely related to anti-oxidative and anti-apoptotic effects of curcumin, which were possibly mediated by suppressing the activation of mir-34a/sirt-1 pathway [49].

A large body of evidence has revealed that the curcumin protective effects on sexual glands are in part due to its antioxidant and anti-apoptotic properties. Previous studies have shown that curcumin supplementation modulates oxidative stress manifestation such as superoxide dismutase, glutathione peroxidase enzyme activities, and lipid peroxidation in testicular injury [26–28,48]. In addition, inhibiting apoptosis by modulating Bax/Bcl-2 expression after curcumin treatment has been verified in testicular disturbances in oxidative conditions [26,28,30,62]. Accordingly, if CsA consumption induces testicular injury through oxidative stress and apoptosis, as confirmed by the present study, the rescue effects of curcumin supplementation on these abnormalities will be due to antioxidant and anti-apoptotic properties of curcumin.

Based on the above information, curcumin could reduce apoptotic cells in testicular tissue, but there is some apoptotic cells left in the peripheral layer where the diploid germ cells adjacent to the basement membrane is located (spermatogonia). According to the literature, there was high sensitivity to various deleterious toxicant exposures in spermatogonia rather than other epithelial cells [63]. It was estimated that decrease in the activity of antioxidant enzymes following toxicants exposure may lead to the more accumulation of free radicals and increased level of lipid peroxidation in peripheral layers contributed to more cell death [64].

To the best of our knowledge, this is the first investigation to show curcumin-mediated protection against CsA-induced oxidative and apoptotic injury by modulating the mir-34a/sirt-1 pathway, thereby preventing the testicular tissue from injury induced by CsA. This might confirm a novel mechanism for curcumin-mediated attenuation of testicular tissue injury induced by CsA.

5. Conclusion

Results of the present study provide new insight into the fact that CsA induces testicular damage as evidenced by an increase in oxidative stress damage markers and apoptotic cells, which are mediated, at least in part, by mir-34a/sirt-1 pathways. Administration of curcumin along with CsA exerts beneficial effects on the testes and might, therefore, be effective in CsA-induced testicular damage. Therefore, curcumin is an effective therapeutic agent with which one can mitigate oxidative stress and apoptosis in the testes of CsA-treated rats. However, further research is still required to define the exact details of the mechanisms through which CsA exposure exerts its deleterious effects on testes, causing abnormalities.

CRedit authorship contribution statement

Amir Mohammad Ghazipour: Data curation, Formal analysis, Writing - original draft. **Alireza Shirpoor:** Supervision, Validation, Visualization. **Rafiqe Ghiasi:** Data curation. **Bagher Pourheydar:** Data curation. **Naser Khalaji:** Data curation. **Roya Naderi:** Conceptualization, Data curation, Formal analysis, Methodology, Project administration, Supervision, Validation, Visualization, Writing - original draft, Writing - review & editing.

Declaration of competing interest

The authors declare that they have no known competing financial interests or personal relationships that could have appeared to influence the work reported in this paper.

Acknowledgments

This study was supported by the Nephrology Research Center, Urmia University of Medical Sciences, Urmia, Iran.

References

- [1] G. Turk, M. Sonmez, A.O. Ceribasi, A. Yuce, A. Atessahin, Attenuation of cyclosporine A-induced testicular and spermatozoal damages associated with oxidative stress by ellagic acid, *Int. Immunopharm.* 10 (2) (2010) 177–182, <https://doi.org/10.1016/j.intimp.2009.10.013>.
- [2] M. Abdul-Hamid, E.M. Abdella, S.R. Galaly, R.H. Ahmed, Protective effect of ellagic acid against cyclosporine A-induced histopathological, ultrastructural changes, oxidative stress, and cytogenotoxicity in albino rats, *Ultrastruct. Pathol.* 40 (4) (2016) 205–221, <https://doi.org/10.1080/01913123.2016.1203854>.
- [3] X. Pan, X. Wang, X. Wang, W. Zhang, Z. Sun, X. Liang, et al., Protective effects of new Wenshen Shengjing Decoction on cyclosporine-induced impairment of testosterone synthesis and spermatogenic apoptosis, *Experimental and therapeutic medicine* 15 (1) (2018) 813–821, <https://doi.org/10.3892/etm.2017.5473>.
- [4] R. Naderi, B. Pourheydar, R. Ghiasi, F. Shafiei, Modulatory effect of tropisetron in the liver of streptozotocin-induced diabetes in rats: biochemical and histological evidence, *Horm. Mol. Biol. Clin. Invest.* (2020), <https://doi.org/10.1515/hmbci-2020-0002>.
- [5] G. Turk, A. Atessahin, M. Sonmez, A. Yuce, A.O. Ceribasi, Lycopene protects against cyclosporine A-induced testicular toxicity in rats, *Theriogenology* 67 (4) (2007) 778–785, <https://doi.org/10.1016/j.theriogenology.2006.10.013>.
- [6] M. Sadeghzadeh, A. Shirpoor, Long-term ethanol consumption promotes changes in beta-defensin isoform gene expression and induces structural changes and oxidative DNA damage to the epididymis of rats, 86 (6) (2019) 624–631, <https://doi.org/10.1002/mrd.23138>.
- [7] A. Shirpoor, L. Norouzi, M.H. Khadem-Ansari, B. Ilkhanizadeh, M. Karimipour, The protective effect of vitamin E on morphological and biochemical alteration induced by pre and postnatal ethanol administration in the testis of male rat offspring: a three months follow-up study, *J. Reproduction Infertil.* 15 (3) (2014) 134–141.
- [8] A.L. Juárez-Rojas, M. García-Lorenzana, A. Aragón-Martínez, L.E. Gómez-Quiroz, S. Retana-Márquez Mdel, Intrinsic and extrinsic apoptotic pathways are involved in rat testis by cold water immersion-induced acute and chronic stress, *Syst. Biol. Reprod. Med.* 61 (4) (2015) 211–221, <https://doi.org/10.3109/19396368.2015.1030473>.
- [9] M. Wang, P. Su, The role of the Fas/FasL signaling pathway in environmental toxicant-induced testicular cell apoptosis: an update, *Syst. Biol. Reprod. Med.* 64 (2) (2018) 93–102, <https://doi.org/10.1080/19396368.2017.1422046>.
- [10] P. Justo, C. Lorz, A. Sanz, J. Egidio, A. Ortiz, Intracellular mechanisms of cyclosporin A-induced tubular cell apoptosis, *J. Am. Soc. Nephrol. : JASN (J. Am. Soc. Nephrol.)*

- 14 (12) (2003) 3072–3080, <https://doi.org/10.1097/01.asn.0000099383.57934.0e>.
- [11] D. Jiao, H. Zhang, Z. Jiang, W. Huang, Z. Liu, Z. Wang, et al., MicroRNA-34a targets sirtuin 1 and leads to diabetes-induced testicular apoptotic cell death, *J. Mol. Med.* 96 (9) (2018) 939–949, <https://doi.org/10.1007/s00109-018-1667-0>.
- [12] N.L. Simone, B.P. Soule, D. Ly, A.D. Saleh, J.E. Savage, W. Degraff, et al., Ionizing radiation-induced oxidative stress alters miRNA expression, *PLoS One* 4 (7) (2009) e6377, <https://doi.org/10.1371/journal.pone.0006377>.
- [13] S.L. Pratt, S.M. Calcaterra, Expression of microRNA in male reproductive tissues and their role in male fertility, *Reprod. Fertil. Dev.* 29 (1) (2016) 24–31, <https://doi.org/10.1071/rd16293>.
- [14] N. Kotaja, MicroRNAs and spermatogenesis, *Fertil. Steril.* 101 (6) (2014) 1552–1562, <https://doi.org/10.1016/j.fertnstert.2014.04.025>.
- [15] V. Robles, P. Herreraez, C. Labbe, E. Cabrera, M. Psenicka, D.G. Valcarce, et al., Molecular basis of spermatogenesis and sperm quality, *Gen. Comp. Endocrinol.* 245 (2017) 5–9, <https://doi.org/10.1016/j.ygcen.2016.04.026>.
- [16] N. Fatemi, M.H. Sanati, M. Shamsara, F. Moayeri, M.J. Zavarehei, A. Pouya, et al., TBHP-induced oxidative stress alters microRNAs expression in mouse testis, *J. Assist. Reprod. Genet.* 31 (10) (2014) 1287–1293, <https://doi.org/10.1007/s10815-014-0302-4>.
- [17] F. Bouhallier, N. Allili, F. Laval, F. Chalmel, M.H. Perrard, P. Durand, et al., Role of miR-34c microRNA in the late steps of spermatogenesis, *RNA (New York, NY)* 16 (4) (2010) 720–731, <https://doi.org/10.1261/rna.1963810>.
- [18] J. Wu, J. Bao, M. Kim, S. Yuan, C. Tang, H. Zheng, et al., Two miRNA clusters, miR-34b/c and miR-449, are essential for normal brain development, motile ciliogenesis, and spermatogenesis, *Proc. Natl. Acad. Sci. U.S.A.* 111 (28) (2014) E2851–E2857, <https://doi.org/10.1073/pnas.1407777111>.
- [19] M. Yamakuchi, M. Ferlito, C.J. Lowenstein, miR-34a repression of SIRT1 regulates apoptosis, *Proc. Natl. Acad. Sci. U.S.A.* 105 (36) (2008) 13421–13426, <https://doi.org/10.1073/pnas.0801613105>.
- [20] R. Ghiasi, R. Naderi, R. Sheervalilou, M.R. Alipour, Swimming training by affecting the pancreatic Sirtuin1 (SIRT1) and oxidative stress, improves insulin sensitivity in diabetic male rats, *Horm. Mol. Biol. Clin. Invest.* 40 (3) (2019), <https://doi.org/10.1515/hmbci-2019-0011>.
- [21] Y.Q. Wang, Q. Cao, F. Wang, L.Y. Huang, T.T. Sang, F. Liu, et al., SIRT1 protects against oxidative stress-induced endothelial progenitor cells apoptosis by inhibiting FOXO3a via FOXO3a ubiquitination and degradation, *J. Cell. Physiol.* 230 (9) (2015) 2098–2107.
- [22] B. Al-Dabbagh, I.A. Elhaty, A. Al Hrout, R. Al Sakkaf, R. El-Awady, S.S. Ashraf, et al., Antioxidant and anticancer activities of *Trigonella foenum-graecum*, *Cassia acutifolia* and *Rhazya stricta*, *BMC Compl. Alternative Med.* 18 (1) (2018) 240, <https://doi.org/10.1186/s12906-018-2285-7>.
- [23] B. Al-Dabbagh, I.A. Elhaty, M. Elhaw, C. Murali, A. Al Mansoori, B. Awad, et al., Antioxidant and anticancer activities of chamomile (*Matricaria recutita* L.), *BMC Res. Notes* 12 (1) (2019) 3, <https://doi.org/10.1186/s13104-018-3960-y>.
- [24] J. Huang, X. Yao, G. Weng, H. Qi, X. Ye, Protective effect of curcumin against cyclosporine A-induced rat nephrotoxicity, *Mol. Med. Rep.* 17 (4) (2018) 6038–6044, <https://doi.org/10.3892/mmr.2018.8591>.
- [25] R. Mohebbati, A. Aanaeigoudari, M.R. Khazdair, The effects of *Curcuma longa* and curcumin on reproductive systems, *Endocr. Regul.* 51 (4) (2017) 220–228, <https://doi.org/10.1515/enr-2017-0024>.
- [26] M. Kanter, C. Aktas, M. Erboğa, Curcumin attenuates testicular damage, apoptotic germ cell death, and oxidative stress in streptozotocin-induced diabetic rats, *Mol. Nutr. Food Res.* 57 (9) (2013) 1578–1585, <https://doi.org/10.1002/mnfr.201200170>.
- [27] A.J. Shah, S. Prasanth Kumar, M.V. Rao, H.A. Pandya, Ameliorative effects of curcumin towards cyclosporine-induced genotoxic potential: an in vitro and in silico study, *Drug Chem. Toxicol.* 41 (3) (2018) 259–269, <https://doi.org/10.1080/01480545.2017.1380660>.
- [28] E. Cheraghi, A. Golkar, K. Roshanaei, B. Alani, Aluminium-induced oxidative stress, apoptosis and alterations in testicular tissue and sperm quality in wistar rats: ameliorative effects of curcumin, *International journal of fertility & sterility* 11 (3) (2017) 166–175, <https://doi.org/10.22074/ijfs.2017.4859>.
- [29] S. Ugur, R. Ulu, A. Dogukan, A. Gurel, I.P. Yigit, N. Gozel, et al., The renoprotective effect of curcumin in cisplatin-induced nephrotoxicity, *Ren. Fail.* 37 (2) (2015) 332–336, <https://doi.org/10.3109/0886022x.2014.986005>.
- [30] L. Zhao, Q. Gu, L. Xiang, X. Dong, H. Li, J. Ni, et al., Curcumin inhibits apoptosis by modulating Bax/Bcl-2 expression and alleviates oxidative stress in testes of streptozotocin-induced diabetic rats, *Therapeut. Clin. Risk Manag.* 13 (2017) 1099–1105, <https://doi.org/10.2147/term.s141738>.
- [31] M.K. Bhutani, M. Bishnoi, S.K. Kulkarni, Anti-depressant like effect of curcumin and its combination with piperine in unpredictable chronic stress-induced behavioral, biochemical and neurochemical changes, *Pharmacol. Biochem. Behav.* 92 (1) (2009) 39–43, <https://doi.org/10.1016/j.pbb.2008.10.007>.
- [32] S. Gholizadeh-Ghaleh Aziz, R. Naderi, N. Mahmodian, Ameliorative effects of trospiretron on liver injury in streptozotocin-induced diabetic rats, *Arch. Physiol. Biochem.* (2019) 1–6, <https://doi.org/10.1080/13813455.2019.1640743>.
- [33] O.H. Lowry, N.J. Rosebrough, A.L. Farr, R.J. Randall, Protein measurement with the Folin phenol reagent, *J. Biol. Chem.* 193 (1) (1951) 265–275.
- [34] G. Albasher, R. Almeer, F.O. Al-Otibi, N. Al-Kubaisi, A.M. Mahmoud, Ameliorative effect of beta vulgaris root extract on chlorpyrifos-induced oxidative stress, inflammation and liver injury in rats, *Biomolecules* 9 (7) (2019), <https://doi.org/10.3390/biom9070261>.
- [35] A. Shirpoor, R. Gaderi, R. Naderi, Ethanol exposure in prenatal and early postnatal induced cardiac injury in rats: involvement of oxidative stress, Hsp70, ERK 1/2, JNK, and apoptosis in a 3-month follow-up study, *Cell Stress Chaperones* 24 (5) (2019) 917–926, <https://doi.org/10.1007/s12192-019-01015-w>.
- [36] E. Karimi-Sales, M.R. Alipour, R. Naderi, E. Hosseinzadeh, R. Ghiasi, Protective effect of trans-chalcone against high-fat diet-induced pulmonary inflammation is associated with changes in miR-146a and pro-inflammatory cytokines expression in male rats, *Inflammation* 42 (6) (2019) 2048–2055, <https://doi.org/10.1007/s10753-019-01067-1>.
- [37] M.R. Alipour, N. Yousefzade, F.M. Babil, R. Naderi, R. Ghiasi, Swimming impacts on pancreatic inflammatory cytokines, miR-146a and NF- κ B, *CyrlilicB* expression levels in type-2 diabetic rats, *Curr. Diabetes Rev.* (2019), <https://doi.org/10.2174/1573399815666191115154421>.
- [38] R. Naderi, A. Shirpoor, M. Samadi, B. Pourheydar, A. Moslehi, Trospiretron improves pancreas function and increases insulin synthesis and secretion in the STZ-induced diabetic rats: involvement of UCP2/ZnT8 pathway, *J. Pharm. Pharmacol.* (2020), <https://doi.org/10.1111/jphpp.13278>.
- [39] M. Amini, E. Saboori, B. Pourheydar, M. Bagheri, R. Naderi, Involvement of endocannabinoid system, inflammation and apoptosis in diabetes induced liver injury: role of 5-HT $_3$ receptor antagonist, *Int. Immunopharm.* 79 (2020) 106158, <https://doi.org/10.1016/j.intimp.2019.106158>.
- [40] J.C. Monteiro, F.S. Predes, S.L. Matta, H. Dolder, Heteropterys aphrodisiaca infusion reduces the collateral effects of cyclosporine A on the testis, *Anatomical record, Hoboken, NJ*, 2007, <https://doi.org/10.1002/ar.20709> 2008;291(7):809–817.
- [41] S.C. Sikka, D.C. Coy, C.A. Lemmi, J. Rajfer, Effect of cyclosporine on steroidogenesis in rat Leydig cells, *Transplantation* 46 (6) (1988) 886–890, <https://doi.org/10.1097/00007890-198812000-00019>.
- [42] J. Choi, N.L. Corder, B. Koduru, Y. Wang, Oxidative stress and hepatic Nox proteins in chronic hepatitis C and hepatocellular carcinoma, *Free Radic. Biol. Med.* 72 (2014) 267–284, <https://doi.org/10.1016/j.freeradbiomed.2014.04.020>.
- [43] A. Manea, M. Simionescu, Nox enzymes and oxidative stress in atherosclerosis, *Front. Biosci.* 4 (2012) 651–670, <https://doi.org/10.2741/s291>.
- [44] F. Pourgholamhossein, R. Rasooli, M. Pournamdari, L. Pourgholi, M. Samareh-Fekri, M. Ghazi-Khansari, et al., Pirfenidone protects against paraquat-induced lung injury and fibrosis in mice by modulation of inflammation, oxidative stress, and gene expression, *Food Chem. Toxicol. : an international journal published for the British Industrial Biological Research Association* 112 (2018) 39–46, <https://doi.org/10.1016/j.fct.2017.12.034>.
- [45] M. Sedek, A.C. Montezano, R.L. Hebert, S.P. Gray, E. Di Marco, J.C. Jha, et al., Oxidative stress, Nox isoforms and complications of diabetes—potential targets for novel therapies, *Journal of cardiovascular translational research* 5 (4) (2012) 509–518, <https://doi.org/10.1007/s12265-012-9387-2>.
- [46] Y. Nisimoto, B.A. Diebold, D. Cosentino-Gomes, J.D. Lambeth, Nox4: a hydrogen peroxide-generating oxygen sensor, *Biochemistry* 53 (31) (2014) 5111–5120, <https://doi.org/10.1021/bi500331y>.
- [47] Y. Maru, T. Nishino, K. Kakinuma, Expression of Nox genes in rat organs, mouse oocytes, and sea urchin eggs, *DNA Sequence : the journal of DNA sequencing and mapping* 16 (2) (2005) 83–88, <https://doi.org/10.1080/10425170500069734>.
- [48] V. Avci, K. Ayengin, H.H. Alp, Oxidative DNA damage and NOX4 levels in children with undescended testes, *Eur. J. Pediatr. Surg. : official journal of Austrian Association of Pediatric Surgery [et al.] = Zeitschrift fur Kinderchirurgie.* 29 (6) (2019) 545–550, <https://doi.org/10.1055/s-0039-1692167>.
- [49] S. Altun, S. Ozdemir, H. Arslan, Histopathological effects, responses of oxidative stress, inflammation, apoptosis biomarkers and alteration of gene expressions related to apoptosis, oxidative stress, and reproductive system in chlorpyrifos-exposed common carp (*Cyprinus carpio* L.), *Environ. Pollut.* 230 (2017) 432–443, <https://doi.org/10.1016/j.envpol.2017.06.085>.
- [50] M. Mohammadi-Sardoo, A. Mandegary, Mancozeb induces testicular dysfunction through oxidative stress and apoptosis, Protective role of N-acetylcysteine antioxidant 34 (11) (2018) 798–811, <https://doi.org/10.1177/0748233718778397>.
- [51] N. Jiao, Y. Chen, Y. Zhu, W. Wang, M. Liu, W. Ding, et al., Protective effects of catalpol on diabetes mellitus-induced male reproductive damage via suppression of the AGEs/RAGE/Nox4 signaling pathway, *Life Sci.* (2019) 116736, <https://doi.org/10.1016/j.lfs.2019.116736>.
- [52] H. Kasai, Analysis of a form of oxidative DNA damage, 8-hydroxy-2'-deoxyguanosine, as a marker of cellular oxidative stress during carcinogenesis, *Mutat. Res.* 387 (3) (1997) 147–163, [https://doi.org/10.1016/s1383-5742\(97\)00035-5](https://doi.org/10.1016/s1383-5742(97)00035-5).
- [53] A. Shirpoor, M. Zerehpooosh, M.H.K. Ansari, F. Kheradmand, Y. Rasmi, Ginger extract mitigates ethanol-induced changes of alpha and beta - myosin heavy chain isoforms gene expression and oxidative stress in the heart of male wistar rats, *DNA Repair* 57 (2017) 45–49, <https://doi.org/10.1016/j.dnarep.2017.06.023>.
- [54] T. Ishikawa, H. Fujioka, T. Ishimura, A. Takenaka, M. Fujisawa, Increased testicular 8-hydroxy-2'-deoxyguanosine in patients with varicocele, *BJU Int.* 100 (4) (2007) 863–866, <https://doi.org/10.1111/j.1464-410X.2007.07008.x>.
- [55] A. Zahra, N. Gholamreza, F. Farokhi, A. Shalazar Jalali, Attenuation of cyclosporine-induced sperm impairment and embryotoxicity by *Crataegus monogyna* fruit aqueous extract, *Cell journal* 15 (3) (2013) 198–205.
- [56] M. Dizdaroji, Chemical determination of free radical-induced damage to DNA, *Free Radic. Biol. Med.* 10 (3–4) (1991) 225–242, [https://doi.org/10.1016/0891-5849\(91\)90080-m](https://doi.org/10.1016/0891-5849(91)90080-m).
- [57] S. Yang, W. Zhang, L.L. Xuan, F.F. Han, Y.L. Lv, Z.R. Wan, et al., Akebia Saponin D inhibits the formation of atherosclerosis in ApoE(-/-) mice by attenuating oxidative stress-induced apoptosis in endothelial cells, *Atherosclerosis* 285 (2019) 23–30, <https://doi.org/10.1016/j.atherosclerosis.2019.04.202>.
- [58] X. Wang, B. Yuan, B. Cheng, Y. Liu, B. Zhang, X. Wang, et al., Crocin alleviates myocardial ischemia/reperfusion-induced endoplasmic reticulum stress via regulation of miR-34a/sirt1/nrf2 pathway, *Shock* 51 (1) (2019) 123–130, <https://doi.org/10.1097/shk.0000000000001116>.
- [59] C.L. Song, B. Liu, H.Y. Diao, Y.F. Shi, J.C. Zhang, Y.X. Li, et al., Down-regulation of

- microRNA-320 suppresses cardiomyocyte apoptosis and protects against myocardial ischemia and reperfusion injury by targeting IGF-1, *Oncotarget* 7 (26) (2016) 39740–39757, <https://doi.org/10.18632/oncotarget.9240>.
- [60] W. Guo, B. Xie, S. Xiong, X. Liang, J.F. Gui, J. Mei, miR-34a regulates sperm motility in zebrafish, *Int. J. Mol. Sci.* 18 (12) (2017), <https://doi.org/10.3390/ijms18122676>.
- [61] T.C. Chang, E.A. Wentzel, O.A. Kent, K. Ramachandran, M. Mullendore, K.H. Lee, et al., Transactivation of miR-34a by p53 broadly influences gene expression and promotes apoptosis, *Mol. Cell* 26 (5) (2007) 745–752, <https://doi.org/10.1016/j.molcel.2007.05.010>.
- [62] A. Brunet, L.B. Sweeney, J.F. Sturgill, K.F. Chua, P.L. Greer, Y. Lin, et al., Stress-dependent regulation of FOXO transcription factors by the SIRT1 deacetylase, *Science* (New York, NY) 303 (5666) (2004) 2011–2015, <https://doi.org/10.1126/science.1094637>.
- [63] S. Kalia, M.P. Bansal, Regulation of apoptosis by Caspases under oxidative stress conditions in mice testicular cells: in vitro molecular mechanism, *Mol. Cell. Biochem.* 322 (1–2) (2009) 43–52, <https://doi.org/10.1007/s11010-008-9938-7>.
- [64] B. Niknafs, M. Salehnia, M. Kamkar, Induction and determination of apoptotic and necrotic cell death by cadmium chloride in testis tissue of mouse, *J. Reproduction Infertil.* 16 (1) (2015) 24–29.