

Traumatic Rupture of a Latent Lung Hydatid Cyst and Drowning and Asphyxia with Hydatid Fluid in a 5-year-old Boy, 2021: A Case Report

*Rahim Mahmoodlou¹, Fatemeh Roydel², Bahare Rivaz³, Mahbubeh Moradi⁴, Abbas Khalilpour⁵,
Kazhal Mobaraki⁶, Jamal Ahmadzadeh⁷, Awat Yousefiazar⁸**

Received 15 Sep 2021, Accepted for publication 15 Feb 2022

Abstract

Lung involvement is a common presentation of Hydatid disease in children. In addition, giant Hydatid cyst is common in children due to parenchymal elasticity of their lungs. In this study, we presented a case of giant Hydatid cyst that was ruptured following trauma through car accident and lung drowning with Hydatid fluid in a 5-year-old boy.

Case presentation: Our patient was a 5-year-old boy who was injured in a car accident. He had full signs and symptoms of obvious respiratory failure. Based on chest X-ray, the primary diagnosis was congenital pulmonary cyst, so a chest tube was placed for decompression. By evaluation of the chest CT-scan, we detected a communicating rupture of Hydatid cyst. Despite full conservative treatment, patient's condition was exacerbated. Therefore, we decided to perform surgical intervention for removing the pressure of the cyst on lung. The patient's condition did not improve. Unfortunately, the patient had cardiac arrest, cardiopulmonary resuscitation was not successful and we lost the patient.

Conclusion: Chest trauma is common in traumatic patients and pleural effusion, empyema, and pneumothorax may occur for a variety of reasons. Various factors can cause these symptoms, and among all the possible causes, the physician should consider the possibility of a ruptured Hydatid cyst following trauma to the lung as one of the differential diagnoses, especially in endemic areas with higher prevalence of Hydatid disease. In the present case, cyst rupture and subsequent drowning and asphyxia with cyst fluid were the main causes of mortality.

Keywords: Lung Hydatid Cyst; Traumatic Rupture Cyst; Asphyxia; Chemical Pneumonitis

Address: School of Allied Medical Sciences, Pardis Nazlou, 11th km of Nazlou Road, Urmia, Iran.

Tel: +98 914 167 2768

Email: Yousefiazar.a@umsu.ac.ir

¹ Associate professor, Department of General Surgery, School of Medicine, Imam Khomeini Hospital, Urmia University of Medical Sciences, Urmia, Iran

² MSc in Operating Room, Isfahan University of Medical Sciences, Isfahan, Iran

³ Bachelor Sciences Degree in Public Health, Urmia University of Medical Sciences, Urmia, Iran

⁴ Instructor of Critical Care Nursing, School of Nursing, Gerash University of Medical Sciences, Gerash, Iran

⁵ Instructor, Department of Operating Room, School nursing, Khoy University of Medical Sciences, Khoy, Iran

⁶ MSc in Epidemiology, Social Determinants of Health Research Center, Urmia University of Medical Sciences, Urmia, Iran

⁷ MSc, Department of surgical technology, School of Allied Medical Sciences, Urmia University of Medical Sciences, Urmia, Iran

⁸ MSc, Department of surgical technology, School of Allied Medical Sciences, Urmia University of Medical Sciences, Urmia, Iran

Introduction

Hydatid disease is a main health and economic issue in vast areas in the world. This zoonotic disease is endemic in countries with agriculture and livestock economy such as Mediterranean countries, south Africa, the Middle East, South America and New Zealand (1). Hydatid disease is caused by the tapeworm *Echinococcus granulosus*. The worm has two hosts. The definitive hosts are certain carnivores notably dogs harboring mature parasites in their intestine, and intermediate hosts including herbivores such as sheep, goats as well as humans that are known as aberrant intermediate hosts (2). Man is infected with echinococcus by eating vegetables infested with dog feces (1, 2).

Lung involvement is the common presentation of Hydatid disease among children. Furthermore, due to parenchymal elasticity of children's lungs, giant Hydatid cysts (>10 cm) are prevalent in them (1). On the other hand, giant cysts are susceptible to rupture and threaten the patient's life during trauma; therefore, the importance of the cyst can be more than the trauma itself (3).

Diagnosis of a ruptured Hydatid cyst, especially in a critical condition, is difficult. After rupture and evacuation of cyst contents, the radiologic features that are a main factor of diagnosis are changed and the diagnosis of Hydatid cyst becomes difficult, delaying its treatment (4, 5). Perforated Hydatid cysts may be misdiagnosed as pneumonia, tuberculosis, lung abscess, and lung tumor. Finally, when the whole content of cysts are released and fill the cyst cavity

with air, a thin-walled, hollow, air-filled cavity or tension-air bag can be diagnosed as pneumothorax (4, 5). Treatment of pulmonary Hydatid cyst is mainly surgical and it should be done before the occurrence of complications; however, in acute phase of perforated Hydatid cyst, especially communicating rupture when patient is in respiratory failure due to chemical pneumonitis, the first priority is to stabilize the patient conditions (6).

In this study, we have presented a case of giant Hydatid cyst ruptured following trauma by car accident and drowning the lung with Hydatid fluid in a 5-year-old boy.

Case presentation

Our patient was a 5-year-old boy who was injured in collision of an automobile 30 minutes before admission to hospital. The patient arrived in hospital by emergency medical services. His primary vital sign was as follows: RR: 32/min. PR: 130, BP: 90/52. The boy was in respiratory distress status and had full signs and symptoms of obvious respiratory failure such as cyanosis, nasal flaring, accessory respiratory muscle efforts, agitation, and perspiration.

The patient was immediately intubated and ventilated with 100% FiO₂. There was no respiratory sound in right hemi-thorax and the sound was diminished in left hemi-thorax. SaO₂ was 80-90% through the administration of 100% FiO₂. Portable chest-x-Ray showed a large cyst with compressed right upper lobe that shifted mediastinum to the left (Figure 1).

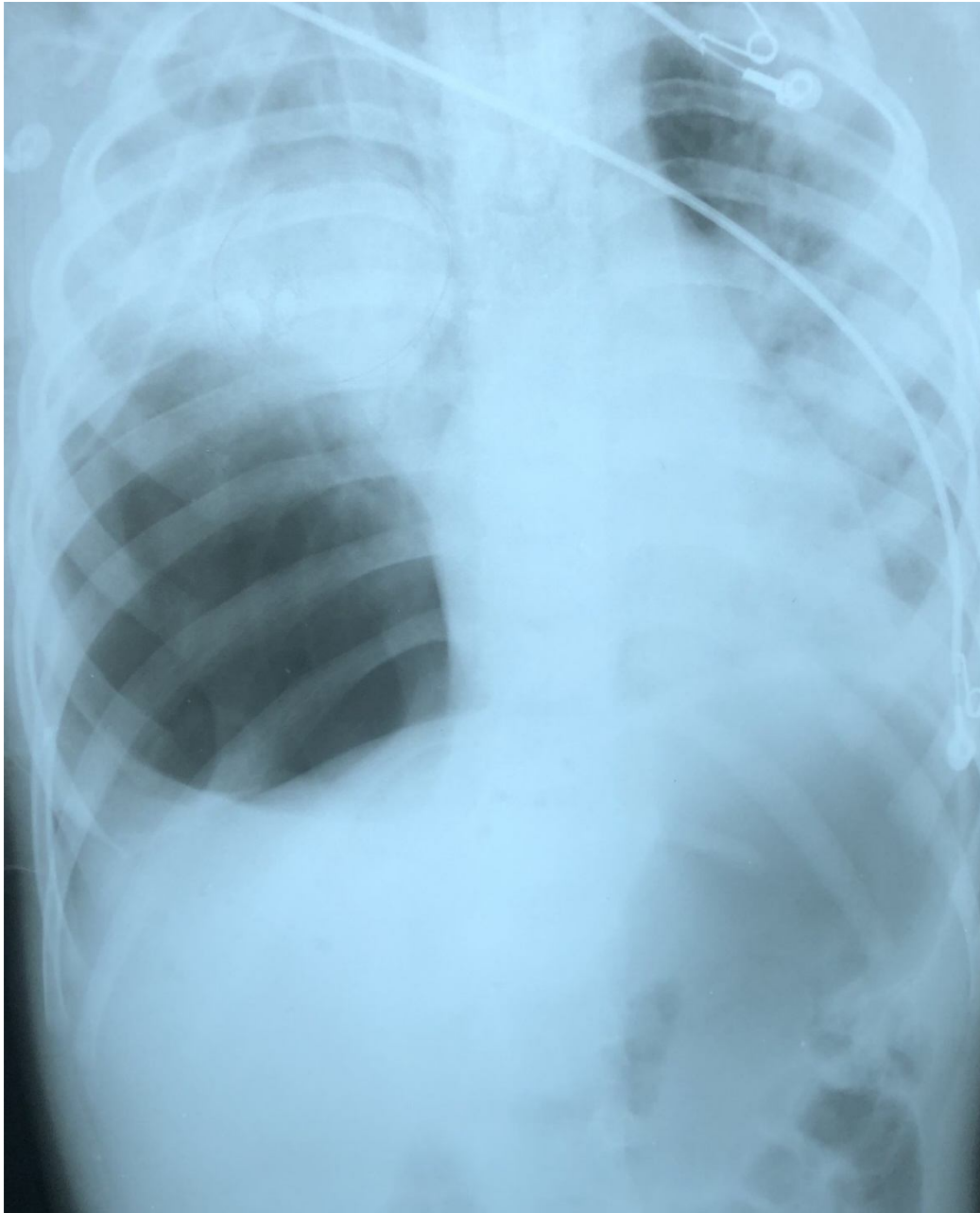


Fig 1: Portable C-X-Ray that shows mediastinal shift to left and right upper lobe collapse

Primary diagnosis was congenital pulmonary cyst that expanded due to mechanical ventilation. Because of unilateral valve mechanisms, the uninvolved lung was compressed with the hyperinflated cyst. Therefore, chest tube was inserted in right hemi-thorax with the hope of perforating the cyst and decompressing the uninvolved lung. Afterward, the patient was referred to a level I trauma center.

At the time of arrival, his vital sign was as follows: BP: 95/50, PR: 110/min, SaO₂:88% by mechanical ventilation and Fio₂: 100%.

The patient was managed based on probable diagnosis at the primary trauma center by chest-x-Ray, namely a congenital cyst that hyper-inflated due to mechanical ventilation.

We were faced with two main questions. If the culprit is the cyst, why has it showed itself after

trauma? And what is the relationship between trauma and the cyst?

To clarify this mystery, the patient underwent chest CT-scan without contrasts. After that, the puzzle was solved (Figure 2).

By evaluation of the chest CT-scan, we diagnosed a communicating rupture of Hydatid cyst, near drowning of the patient with Hydatid fluid, and compression of remaining lung secondary to pericyst overexpansion due to mechanical ventilation.

Our intervention included conservative treatment for stabilizing the patient. Therefore, intravenous hydrocortisone (25 mg stat), antibiotic, and ranitidine were prescribed. The patient was ventilated by mechanical ventilation using SIMV MODE: Fio₂: 100% TV: 130 RR: 18 PEEP: 5 cm H₂O. Despite full conservative treatment, his condition got worse and even with receiving 100% FiO₂, his arterial oxygenation was inadequate and SaO₂ was <90%.

In this condition, the only thing that seemed likely to help the patient was removing the pressure of the cyst on the lung. Our postulation was that “progressive inflation of the cyst due to mechanical ventilation will stop remaining lung function”. So, the patient was transferred to operating room and anterolateral

thoracotomy was performed in supine position. Intraoperative findings include a large cyst occupying the whole hemi-thorax like a lobar emphysema. The whitish and thin wall of cyst showed that the cyst was of Hydatid type. After incision of pericyst, the large cyst membrane was removed, bronchial opening was closed with 4/0 Vicryl, and the overzealous pericyst was removed with Endo stapler. Right upper lobe was as stiff as liver and gas exhaustion was obvious from bronchial opening despite severe ventilation, namely findings that support parenchymal pathology. After insertion of chest tube, the thoracotomy was closed, but unfortunately the patient’s condition did not improve.

The patient returned to ICU and conservative treatment continued; unfortunately, his oxygenation worsened in spite of 100% oxygen delivery using CMV mode. Four hours after surgery, the patient showed bradycardia and was hypotensive. Norepinephrine was started and his hemodynamics corrected transiently, but SaO₂ remained under 80%. Regrettably, his bradycardia status was persistent and the patient had cardiac arrest. Cardiopulmonary resuscitation was not successful and the boy was deceased.

A written informed consent was obtained from the family.

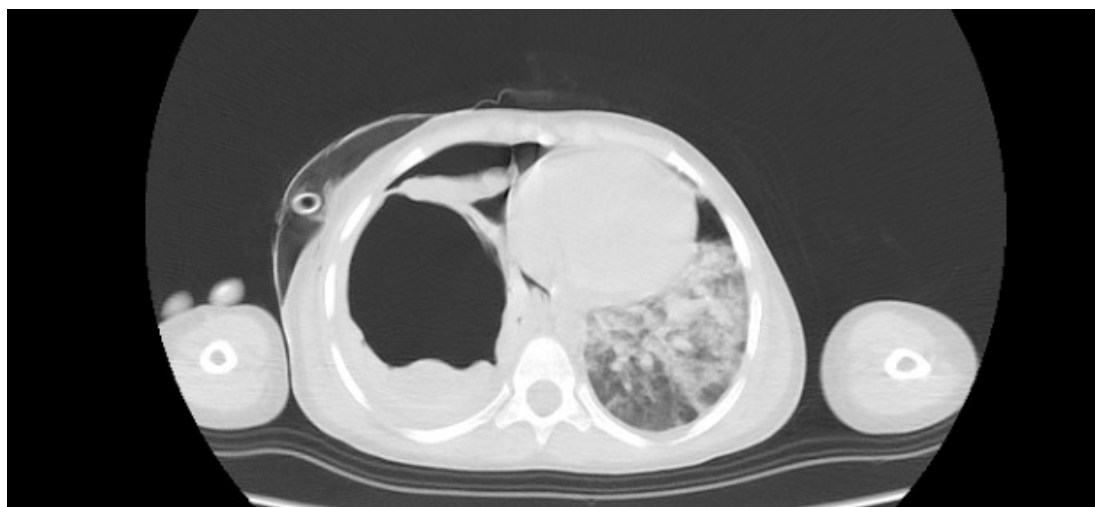


Fig 2. Chest CT-scan showing hyper inflated cyst with mediastinal shift and flooded intact lung

Discussion

Natural history of pulmonary Hydatid cyst indicates relentless growth until the complications occur, unless the diagnosis is made before complications (1-3, 7). The lung is second to liver in involvement by this disease (2). Hydatid disease in lung has several unique characteristics, and due to high elasticity of the lung parenchyma, delayed presentation of symptoms is common in pulmonary Hydatid cyst. The cyst growth rate is high in the lungs; therefore, it can reach a giant size before the diagnosis. Because children's lungs are more elastic than adults, the difference in growth rate is exaggerated in children's lungs. It is reported that the cyst growth rate in adult is 1 cm/year while in children it is 5 cm per year. The rapid increase in size has two consequences. Firstly, pulmonary Hydatid cyst in children is clinically more common than liver and secondly, giant cyst (>10 cm) and its complications such as rupture are prevalent in their lungs.(2, 6-8) In the present case, similar to the data reported in previous studies,(7, 9) we were faced with a giant ruptured cyst that involved the whole hemi-thorax.

Rupture of Hydatid cyst can be classified into three categories: 1) contained rupture, when the endocyst is ruptured but pericyst is intact and thus the contents of cyst have no communication with tracheobronchial tree or pleural space, 2) communicated ruptured, when the endocyst is ruptured and cyst contents are drained with bronchioles that have been incorporated in the cyst, 3) Direct or broken rupture, in which endocyst and pericyst are ruptured simultaneously and the cyst contents spill into pleural space (8). In present study, we were confronted with a communicated rupture.

Although each type of rupture has its own potential danger, the communicating rupture is the most dangerous type because of drowning and asphyxia with cyst fluid and suffocation due to airway obstruction with particles of ruptured membrane that threatens the

patient life. Furthermore, it can lead to endobronchial spread of Hydatid cysts, anaphylactic shock, circulatory collapse and acute respiratory failure (4, 5, 8).

Pulmonary Hydatid cyst can be discovered in three manners. Firstly, it may be asymptomatic and detected during an unexpected imaging such as pre-employment examinations, which is uncommon in children. Secondly, pulmonary Hydatid cyst may present with respiratory symptoms such as chest pain, cough, and dyspnea. Thirdly, it can present with complications, namely rupture (2, 8).

Despite these definitions for Hydatid cyst, in the present case, the patient was a child without symptoms in whom the rupture and fatal complications of Hydatid cyst were the first presentation of pulmonary Hydatid cyst. Asphyxia followed by sudden death occurred due to rapid growth of cyst in lung, posttraumatic rupture, and catastrophic complications.

Tension pneumothorax is the most common misdiagnosis in the ruptured Hydatid cyst, (7) and was a differential diagnosis in our case report.

Treatment of pulmonary Hydatid cyst is mainly surgical and should be done before occurrence of complications. Nevertheless, in acute phase of perforated Hydatid cyst, especially communicating rupture in which the patient is in respiratory failure due to chemical pneumonitis, the first priority is to stabilize the patient conditions (6). The main principles of this surgery are the prevention of spillage, removing cyst membranes including germinative and laminated membrane, closings bronchial openings, and handling the pericyst cavity (10). Covering surroundings of cyst with gauze or long gauzes soaked with hypertonic saline will prevent intraoperative spillage (10). The cyst can be removed by enucleation in intact cysts or removing membranes in perforated ones (6, 10). After removing the cyst, the pericyst cavity can be managed

by capitonage or non-capitonage methods such as secularization (5, 6, 10).

In the present study, removal of ruptured cyst membrane and closure of the bronchial tree by Vicryl suture were performed. Because of the emergency surgery, pulmonary resection and capitonage were avoided.

In various studies extracorporeal membrane oxygenation (ECMO) was used for acute severe lung failure. Unfortunately we didn't have access to the ECMO machine for using after surgery during ICU follow up.

Conclusions

Chest trauma is common in traumatic patients, and pleural effusion, empyema, and pneumothorax may occur for several reasons. Many factors can cause these symptoms, and among all the possible factors, the physician must consider the possibility of a ruptured Hydatid cyst following trauma to the lung as one of the differential diagnoses, especially in endemic areas that have a higher prevalence of Hydatid disease. In the present case, cyst rupture and subsequent drowning and asphyxia with cyst fluid were the main cause of mortality. One question that remained unanswered in this case, however, was as follows: what could we have done for saving the patient?

Acknowledgments

None.

Conflicts of Interest

The authors declare that they have no conflict of interest.

Informed Consent

Informed consent was obtained from all patients for being included in the study.

Authors Contributions

RM, AY is a main operator who performed the intervention, and a primary author of manuscript development. KM, JA, FR, BR, AKH and MM collected background data, and provided significant authorship in the development of manuscript.

References

- Özdemir A, Bozdemir ŞE, Akbiyik D, Daar G, Korkut S, Korkmaz L, et al. Anaphylaxis due to ruptured pulmonary hydatid cyst in a 13-year-old boy. *Asia Pacific Allergy* 2015;5(2):128-31.
- Stewart M, Cunningham M. Tension pneumothorax complicating pulmonary hydatid disease in childhood. *Clinical pediatrics* 1987;26(8):422-4.
- Gulalp B, Koseoglu Z, Toprak N, Satar S, Sebe A, Gokel Y, et al. Ruptured hydatid cyst following minimal trauma and few signs on presentation. *Neth J Med* 2007;65(3):117-8.
- Hijazi MH, Al-Ansari MA. Pulmonary hydatid cyst in a pregnant patient causing acute respiratory failure. *Ann Thorac Med* 2007;2(2):66.
- Shameem M, Akhtar J, Bhargava R, Ahmed Z, Khan NA, Baneen U. Ruptured pulmonary hydatid cyst with anaphylactic shock and pneumothorax. *Respir. Care* 2011;56(6):863-5.
- Ashour MH, Hajjar WM, Ishaq M, Alamassi M, Saleh W, Al Kattan KM, et al. Pulmonary hydatid cysts: the naturally occurring models for rupture. *Asian Cardiovasc Thorac Ann* 2016;24(7):670-5.
- Sokouti M, Shokouhi B, Sokouti M, Sokouti B. Giant Pulmonary Hydatid Cyst and Trauma in a 9 Year-Old Child: A Case Report. *Open Respir Med J* 2015;9:67.
- Jedidi M, Mlayeh S, Masmoudi T, Souguir MK, Zemni M. Sudden death due to hydatid cyst: thirty-four medicolegal autopsy cases. *Am. J. Forensic Med. Pathol* 2014;35(1):29-33.
- Arroud M, Afifi MA, El Ghazi K, Nejari C, Bouabdallah Y. Lung hydatid cysts in children:

comparison study between giant and non-giant cysts.
Pediatr. Surg. Int 2009;25(1):37.

a modified uncapitonnage method of surgery for
pulmonary hydatidosis. World J. Surg 2013;37(9):2129-
33.

10. Mahmoulou R, Sepehrvand N, Nasiri M. Saucerization: