

## A 43 Year-Old Woman with Fever Eleven Years after Kidney Transplantation

Legha Lotfollahi <sup>1</sup>, Payam Tabarsi <sup>1</sup>,  
Amir Ahmad Nassiri <sup>1</sup>, Arda Kiani <sup>1</sup>,  
Farin Rashid Farokhi <sup>2</sup>, Ilad Alavi  
Darazam <sup>1</sup>, Khadijeh Makhdoomi <sup>3</sup>,  
Mohammad Hossein Rahimi Rad <sup>3</sup>,  
Davood Mansouri <sup>1</sup>

<sup>1</sup> Clinical Tuberculosis and Epidemiology Research Center, National Research Institute of Tuberculosis and Lung Disease (NRITLD), Shahid Beheshti University of Medical Sciences, Tehran, Iran, <sup>2</sup> Telemedicine Research Center, NRITLD, Shahid Beheshti University of Medical Sciences, Tehran, Iran, <sup>3</sup> Department of Pulmonary Medicine, Imam Khomeini hospital, Urmia university of medical sciences, Urmia, Iran.

Correspondence to: Mansoori SD  
Address: NRITLD, Shaheed Bahonar Ave,  
Darabad, TEHRAN 19569, P.O:19575/154, IRAN  
Email address: dmansouree@yahoo.com

### WHAT IS YOUR DIAGNOSIS?

Our patient was a 43 year-old woman referred due to fever eleven years after allograft renal transplantation. She was healthy until 4 months ago on a combination of mycophenolate mofetil (1 gr twice daily) and cyclosporine (50 mg twice daily). Preliminary evaluations for sustained fever without any concomitant symptoms in another center had revealed only diffuse ground glass opacities in both lungs on chest computed tomography (CT) scan (Figure 1). Before admission, based on positive cytomegalovirus (CMV) immunoglobulin G (IgG), mycophenolate mofetil had been discontinued due to an assumption of reactivation of CMV infection. A combination of ganciclovir plus prednisolone 10 mg daily and then valganciclovir for approximately three months resulted in fever cessation.

One week after discontinuation of the aforementioned regimen, she became febrile again. A new consolidation in left lower lobe was the prominent finding (Figure 2). She rejected CT-guided biopsy; empirical amphotericin B and standard regimen of anti-tuberculosis (TB) were initiated. Finally, she was referred to our center for further evaluation. On admission, she was stable without remarkable findings in physical examination. Complete blood cell count, liver biochemistry and renal function test were all within normal range. During recent admission, valganciclovir and anti-TB were discontinued and bronchoscopy was performed. Serum and bronchoalveolar lavage (BAL) specimens were negative for galactomannan. Acid-fast bacilli were seen by direct Ziehl-Neelsen staining along with positive result of polymerase chain reaction (PCR) for *Mycobacterium tuberculosis*. Anti-TB regimen was initiated again, cyclosporine stopped and prednisolone dosage increased to 20 mg daily. Two weeks later the patient became febrile again associated with cough and malaise. The previous consolidation revealed further extension with central cavitation (Figure 3). A new work-up including bronchoscopy and open lung biopsy in the primary center solely confirmed the diagnosis of tuberculosis. She was referred again due to new-onset fever, non-purulent cough and mild exertional dyspnea without remarkable finding in physical examination.

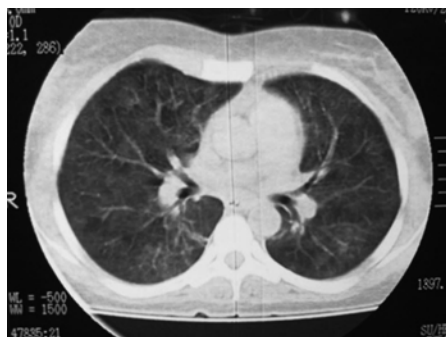

Figure 1. Diffuse ground glass opacity in both lungs on chest computed tomography scan four months before admission

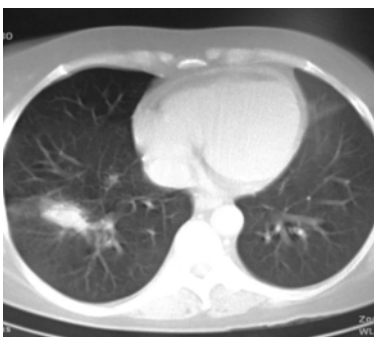

Figure 2. New consolidation in lower lobe

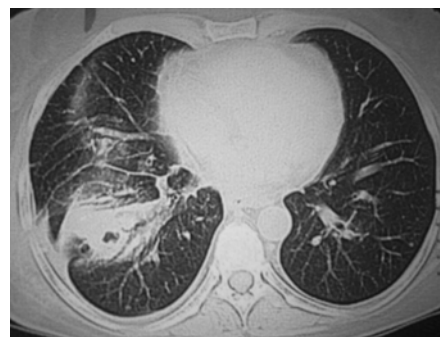


Figure 3. Chest CT-scan after initiation of anti-TB medication

## Answer

### Diagnosis: Immune reconstitution inflammatory syndrome (IRIS) after initiation of anti-tuberculosis medication

Recent evaluations of new-onset fever, malaise, dyspnea and non-productive cough for suspected bacterial, viral and fungal pathogens were entirely negative. Antimicrobial sensitivity testing revealed no resistance to isoniazid and rifampin. Finally, unremarkable findings, reevaluations, and amelioration of general condition during her admission suggested immune reconstitution inflammatory syndrome due to the treatment of underlying TB.

Tuberculosis is a serious opportunistic infection that is frequently seen in transplant recipients particularly within the first year after transplantation when they are profoundly immunosuppressed (1). The incidence of tuberculosis among recipients is 20-74 times higher than the general population, with a mortality rate of up to 30 % (2). Occurrence of tuberculosis eleven years after renal transplantation (when the patient did not receive high dose steroid and had no new exposure to tuberculosis) is an unusual presentation in this case.

Two large studies that involved patients with all types of solid organ transplantation described a median time of 9 months (range, 0.5–13 months) for onset of TB in 61%–63% of patients. The remaining patients developed tuberculosis more than two years after transplantation (2). Another challenging issue in this case that further confused us was occurrence of TB 18 months after discontinuation of corticosteroid when the recipient was on cyclosporine and mycophenolate only. However, most studies have demonstrated that the introduction of cyclosporine and mycophenolate mofetil has led to lower rates of infection in transplant recipients (other than CMV in patients receiving mycophenolate mofetil) (1).

IRIS results from rapid restoration of immune responses to opportunistic pathogens and is most frequently seen in immunocompromised patients (3) when there is an abrupt shift of host immunity from an anti-inflammatory and immunosuppressive status towards a pathogenic proinflammatory state. Characteristic features of IRIS in HIV patients include clinical deterioration after initiation of effective antiretroviral therapy usually within the last three months without an alternative diagnosis. The most important opportunistic pathogen responsible for IRIS is *Mycobacterium tuberculosis* followed by varicella zoster virus, herpes viruses, and CMV (4). Tuberculosis-associated IRIS consists of two different manifestations: paradoxical IRIS (onset in patients who are already being treated for TB) and unmasking IRIS (onset in patients with previously unrecognized TB) (1,5).

The overall incidence of IRIS is unknown depending on the understudy population and its burden of underlying opportunistic infections. In our patient, discontinuation of cyclosporine and mycophenolate mofetil probably ameliorated her immunosuppression before initiation of anti-TB therapy.

In addition to HIV-infected patients, immune reconstitution inflammatory syndrome has also been observed in solid organ transplant recipients, women during the postpartum period, neutropenic patients, and tumor necrosis factor antagonist recipients (6). To date, there is no definite diagnostic markers for IRIS, therefore confirmation of the disease relies heavily upon case definitions based on clinical and laboratory data (7,8). Recently, Marias et al. revealed low interferon gamma and high tumor necrosis factor concentrations in cerebrospinal fluid of patients with TB-IRIS. These promising results are

suggestive of the diagnostic yield of serum or other fluids like bronchoalveolar lavage concentrations of interferon gamma and tumor necrosis factor for other manifestations of TB-IRIS including pulmonary disease (5).

Due to the unremarkable findings regarding suspected infectious and non-infectious causes of her new onset symptoms and signs, she was followed closely with no change in her treatment protocol. All the aforementioned symptoms including fever, malaise and cough relieved and she was discharged in good status. On her follow up two months later, she was well and afebrile.

To sum-up, immunocompromised patients with noticeable findings should be evaluated judiciously for suspected opportunistic infections due to different incidence and burden of infections and their varying clinical presentations in these patients. The challenging diagnosis of IRIS should be taken into account, particularly in association with marked changes in the immune status including adjusting the dosage of immunosuppressive agents.

## REFERENCES

1. Fitzgerald DW, Sterling TR, Haas DW. Mycobacterium tuberculosis. In: Mandell GL, Bennet JE, Dolin R, editors. Principles and practice of infectious disease. 7<sup>th</sup> ed. Philadelphia: Churchill Livingstone Elsevier. 2010; 3148.
2. Muñoz P, Rodríguez C, Bouza E. Mycobacterium tuberculosis infection in recipients of solid organ transplants. *Clin Infect Dis* 2005; 40 (4): 581- 7.
3. Tappuni AR. Immune reconstitution inflammatory syndrome. *Adv Dent Res* 2011; 23 (1): 90- 6.
4. Murdoch DM, Venter WD, Van Rie A, Feldman C. Immune reconstitution inflammatory syndrome (IRIS): review of common infectious manifestations and treatment options. *AIDS Res Ther* 2007; 4: 9.
5. Marais S, Meintjes G, Pepper DJ, Dodd LE, Schutz C, Ismail Z, et al. Frequency, severity and prediction of tuberculous meningitis immune reconstitution inflammatory syndrome. *Clin Infect Dis* 2012.
6. Sun HY, Singh N. Immune reconstitution inflammatory syndrome in non-HIV immunocompromised patients. *Curr Opin Infect Dis* 2009; 22 (4): 394- 402.
7. Meintjes G, Lawn SD, Scano F, Maartens G, French MA, Worodria W, et al. Tuberculosis-associated immune reconstitution inflammatory syndrome: case definitions for use in resource-limited settings. *Lancet Infect Dis* 2008; 8 (8): 516- 23.
8. Müller M, Wandel S, Colebunders R, Attia S, Furrer H, Egger M; IeDEA Southern and Central Africa. Immune reconstitution inflammatory syndrome in patients starting antiretroviral therapy for HIV infection: a systematic review and meta-analysis. *Lancet Infect Dis* 2010; 10 (4): 251- 61.