

# Interaction between gentamicin and mycophenolate mofetil in experimentally induced pyelonephritis

H. Malekinejad, A. Nikibakhsh<sup>1</sup>, S. Gholizadeh-Soltani, A. Farshid<sup>2</sup>

Departments of Pharmacology and Toxicology, Faculty of Veterinary Medicine, Urmia University, <sup>1</sup>Nephrology-Urology-Transplantation Research Center, Urmia University of Medical Sciences, and <sup>2</sup>Department of Pathology, Faculty of Veterinary Medicine, Urmia University, Urmia, Iran

## ABSTRACT

Acute pyelonephritis (APN) is an inflammatory disease that leads to kidney malfunction. The objective of this investigation was to evaluate the impact of gentamicin (GEN) and ceftriaxone (CEF) alone and in combination with mycophenolate mofetil (MMF) on experimentally induced APN. Forty two Wistar male rats were assigned into seven groups +APN, APN +GEN, APN+CEF, APN+MMF, APN+GEN+MMF and APN+CEF+MMF. APN was induced by injecting *E. coli* in the left kidney. The control and +APN groups were treated with normal saline while the other APN groups received GEN, CEF, or MMF alone and/or in combination for 2 weeks. The elevated total white blood cells count and increased level of creatinine and blood urea nitrogen (BUN) in +APN groups returned to normal levels following 14 days treatment with GEN and CEF. Co-administration of GEN with MMF could not recover the APN-induced changes and resulted in a significant ( $P < 0.05$ ) elevation of creatinine and BUN levels. Histopathological studies supported the biochemical findings as GEN and CEF alone could partly restore the APN-induced degeneration and leukocytic infiltration; however, the combination therapy of GEN plus MMF failed to reduce the APN-induced damages. The antibacterial susceptibility test demonstrated that the strain of *E. coli* used in this study was susceptible to GEN and CEF and the combination therapy did not change the antibacterial potency. These findings suggest that co-administration of GEN with MMF in APN may enhance kidney damage and the adverse effects of combination therapeutic regimen could be related partly to incompatibility of these compounds.

**Key words:** Acute pyelonephritis, ceftriaxone, combination therapy, *E. coli*, gentamicin, mycophenolate mofetil

## Introduction

Urinary infections such as acute and chronic pyelonephritis may induce severe inflammation, renal dysfunction and result in scar formation. Acute pyelonephritis (APN) is one of the most common infectious diseases occurring both in complicated and uncomplicated forms.<sup>[1]</sup> Pyelonephritis may occur during pregnancy capable of causing perinatal and maternal disorders such as premature delivery, infants

with low birth weight and transient renal insufficiency.<sup>[2]</sup> *E. coli* is the major culprit in pyelonephritis followed by *Proteus spp.* and *Klebsiella spp.*<sup>[3-5]</sup> There are various antibiotic regimens for the treatment of APN including cefazolin, ceftriaxone, and gentamicin, which could be given alone or in combination.<sup>[6]</sup>

Aminoglycosides, including gentamicin (GEN), the most common used member of this family, can exert considerable nephrotoxicity.<sup>[7]</sup> It has been shown that the co-administration of poly-L-aspartic acid, fleroxacin with aminoglycosides may attenuate the nephrotoxicity of aminoglycosides.<sup>[8,9]</sup> Ceftriaxone (CEF), another broad-spectrum  $\beta$ -lactam antimicrobial agent, is also used for the treatment of APN. Previous reports indicate that CEF was clinically and microbiologically effective and the most patients could tolerate it well.<sup>[10]</sup>

Mycophenolate mofetil (MMF) is employed as an immunosuppressive agent for the prophylaxis of organ rejection in patients receiving allogenic renal transplants. MMF inhibits inosine monophosphate dehydrogenase

### Address for correspondence:

Dr. Hassan Malekinejad, Department of Pharmacology and Toxicology, Faculty of Veterinary Medicine, Urmia University, P. O. Box: 1177, Urmia, Iran. E-mail: hassanmalekinejad@yahoo.com

### Access this article online

#### Quick Response Code:



#### Website:

[www.indianjnephrol.org](http://www.indianjnephrol.org)

#### DOI:

10.4103/0971-4065.91188

(IMPDH). In patients with renal insufficiency an increase of up to 50% in plasma concentration of mycophenolic acid (MPA) as active metabolite of MMF has been reported indicating urinary elimination of MMF and/or its metabolites.<sup>[11]</sup> Accumulating data suggest that the use of MMF for the treatment of transplanted kidneys results in less chronic changes. At the same time, it has also been found that 30% to 50% of the renal transplanted patients develop APN within 2 months, which are counted as complicated APN.<sup>[12]</sup>

Since MMF is administered for a long period of time in kidney recipients<sup>[13]</sup> and there is a high risk of APN in the same patients, who may be treated with aminoglycosides or cephalosporins, this study aimed to evaluate the effects of GEN, CEF, and MMF on experimentally induced acute pyelonephritis. Moreover, the efficacy of combination therapy for the treatment of complicated APN was tested in experimentally induced APN in an animal model.

## Materials and Methods

### Animals

Forty two adult male Wistar rats (200-220 g) were obtained from the animal house of the Faculty of Veterinary Medicine, Urmia University. The rats were acclimatized for 1 week and had free access to food and water both during adaptation and experimental periods. The experimental protocols were approved by the ethical committee of Urmia University in accordance with principles of laboratory animal care (NIH publication no. 85-23, revised 1985). Animals were assigned into seven groups ( $n = 6$ ) including APN/+NS (normal saline), APN/+GEN, APN/+CEF, APN/+MMF, APN/+GNM + MMF, and APN/+CEF+MMF. A group without APN was also used as the control group.

### Pyelonephritis induction

The APN induction was carried out as described previously.<sup>[14]</sup> *Escherichia coli* (*E. coli*) ATCC 25922 strain, as a known pathogen in rats, was used for APN induction. Animals were anesthetized intraperitoneally with a combination of ketamin (40 mg/kg) and xylazine (4 mg/kg). The left side of the rats was shaved and aseptically prepared. Then the left kidney was surgically exposed. Subsequently, 100  $\mu$ l from a freshly prepared suspension of bacteria, containing  $10^6$  to  $10^7$  organisms per ml of phosphate-buffered saline, was injected using a 26-gauge needle into the midpolar region of the kidney. The kidney was returned to its normal anatomical position and surgery was finalized with suturing muscle and skin layers.

### Treatment protocol

Exactly 24 h after APN induction, APN rats were treated with normal saline (i.p.), GEN (20 mg/kg, i.p.), CEF (50 mg/kg, i.m.), MMF (15 mg/kg, p.o.), or GEN+MMF (20 mg/kg, i.p. + 15 mg/kg, p.o) and CEF + MMF (50 mg/kg, i.m + 15 mg/kg, p.o) for 14 consecutive days, while the control group received normal saline.

### Hematological analyses

A total of 0.5 ml of blood was transferred into a pediatric (1 ml) tube containing ethylene diaminetetraacetic acid (EDTA) as an anticoagulant. A blood smear was prepared from fresh blood dried in air and fixed with methanol. The slides then underwent a Giemsa staining. Hematological analyses were completed using an automated analyzer System (Hitachi 704, Japan).

### Determination of the serum biochemical profile

On days 4 and 15, following a light anesthesia induced with diethyl ether, the blood samples (0.5 mL) were collected directly from the heart. After one hour at room temperature the samples were centrifuged at 3000 g for 10 min to obtain the serum. To evaluate the impact of APN and the therapeutic effects of the agents on renal function, the serum levels of creatinine (Parsazmun Inc. Karaj, Iran) and BUN (DarmanKave, Isfahan, Iran) were determined. These measurements were performed using available commercial standard kits and according to the manufacturer's instructions.

### Determination of minimal inhibitory concentration, minimal bactericidal concentration and inhibition zone diameter

The microdilution method was performed to determine the minimal inhibitory concentration (MIC) value of the agents used against *E. coli* according to the Clinical and Laboratory Standards Institute (CLSI) guidelines.<sup>[15]</sup> A range of concentrations (0.125, 0.312, 0.625, 1.25, 2.5, 5, 10, 20, and 40 mg/ml in di-ionized water) from GEN, CEF (Sigma-Aldrich, Germany), and MPA (Sigma Chemical Co. St Luis, MO, USA) were prepared.

Twenty microliters from a freshly cultured suspension of bacterium containing approximately  $10^6$  CFU/ml were applied onto Mueller Hinton broth medium (MHB, Merck, Germany) supplemented with the various concentrations of GEN, CEF, MPA, and equivalent concentrations of the combination of GEN and MPA and/or CEF and MPA (twofold dilution). Control assays with the same concentration of the solvent (<1%), and without the given test compounds were performed under the same condition. The microtiter plates were then incubated at 37°C for 24 h. MIC was calculated in triplicates for all compounds as the lowest concentration

capable of causing a complete suppression of colony growth.

Minimal bactericidal concentration (MBC) values were determined by streaking contents from microtiter wells that gave significant MIC values on fresh MHB and incubated at 37°C for 24 h. The concentration, which caused complete free of CFU after 24 h incubation, was considered as MBC.

To determine the diameter of inhibition zone, we used the punch hole method. Briefly, the surface of previously prepared nutrient agar medium was inoculated with the same amount of organism ( $10^7$  CFU/ml) used for in vivo induction of APN. After 10 min, the surface of the agar medium was punched using a sterile cork borer. Twenty milliliters from individual antibiotics at the already calculated MIC and MBC concentrations were dropped into the holes and kept in an incubator for 24 h at 37°C for an optimal growth of the organism. Following 24 h incubation, the inhibition zone in all wells was read and the diameter expressed in mm.

### Histopathological studies

On day 15, all rats, following anesthesia with ketamine (5%, 40 mg/kg, i.p.) and xylazine (2%, 5 mg/kg, i.p.), were euthanized in a special device using CO<sub>2</sub> gas. The left and right kidneys were immediately removed and were fixed in 10% buffer formal saline for further histopathological examinations. The samples were paraffin embedded; 5-6 μm sections were cut using rotary microtome. The samples were stained with the hematoxyline and eosin technique and ultimately analyzed under a light microscope. To evaluate the level of damage following APN induction and the effect of different regimens used in the test groups, indexes such as hemorrhages, congestion, leukocytic infiltration, fibroblastic proliferation, and degeneration were scored numerically. The criteria for pathological lesions were as follows: 0 for no detectable lesion, 1 for mild changes, 2 for moderate changes, and 3 for severe changes. The histopathological studies were conducted by a pathologist who was blinded to the study.

### Statistical analyses

Data are expressed as the mean ± SD. The results were analyzed using Graph Pad Prism software (version 2.01. Graph Pad software Inc. San Diego, California). The comparisons between groups were made by analysis of variance (ANOVA) followed by Bonferroni post test. For comparing the graded degree of pathological findings between groups, the Kruskal-Wallis test was used. A *P* value of <0.05 was considered as significant.

## Results

### Hematological analyses

The hematological analyses following APN induction indicated that the control and +APN groups showed significant differences in all studied parameters. Without treatment +APN animals showed typical signs of infection. Administration of GEN at 20 mg/kg for 3 days resulted in improvement of the parameters; however, only total neutrophil density was significantly (*P* < 0.05) reduced compared to the +APN group. Following the application of the combination therapy with GEN plus MMF for 3 days, the hematological results showed almost the same profile as we already described for GEN alone [Table 1].

On 14 days after APN induction, the +APN group still exhibited relatively a high total white blood cell count (TWBC), total neutrophils (TN) density, and low lymphocyte count in comparison to the control group. GEN and CEF administration for 14 days resulted in some recovery of the infected animals from hematological point of view. Surprisingly co-administration of GEN and MMF for 14 days caused no therapeutic effects on the hematological profile and as we expected the total lymphocytes density was significantly (*P* < 0.05) reduced [Table 2]. By

**Table 1: Effects of the different treatment regimens on hematological parameters in rats with experimentally induced APN (3 days after the treatment); for each group n = 8, mean values ± SD are given**

Groups	T. WBC ( $\times 10^3/\mu\text{l}$ )	T. NTP (%)	T. LMT (%)
Control	10.30 ± 0.08 <sup>a</sup>	20.33 ± 1.53 <sup>a</sup>	74.00 ± 1.73 <sup>a</sup>
APN	14.46 ± 1.36 <sup>b</sup>	58.50 ± 2.12 <sup>b</sup>	47.50 ± 6.36 <sup>b</sup>
APN+GEN	12.50 ± 0.70	41.00 ± 5.20*	57.33 ± 8.50
APN+CEF	8.18 ± 1.18*	28.60 ± 4.62*	71.00 ± 4.24*
APN+MMF	7.86 ± 0.49*	73.40 ± 5.15*	14.23 ± 2.08*
APN+GEN+MMF	12.06 ± 1.33*	44.00 ± 7.07*	45.50 ± 0.71*
APN+CEF+MMF	10.25 ± 1.37*	31.67 ± 3.21*	63.33 ± 2.31*

TWBC = Total white blood cells; TNTP = Total neutrophils; TLMT = Total lymphocytes. Different superscript (a and b) represent the significant differences (*P* < 0.05) between control and APN groups and stars (\*) indicating significant differences between APN and other test groups at the same column.

**Table 2: Effects of the different treatment regimens on hematological alterations in rats with experimentally induced APN (14 days after the treatment); for each group n = 8, mean values ± SD are given**

Groups	T. WBC ( $\times 10^3/\mu\text{l}$ )	T. NTP (%)	T. LMT (%)
Control	10.73 ± 0.97 <sup>a</sup>	21.70 ± 1.19 <sup>a</sup>	71.30 ± 2.60 <sup>a</sup>
APN	13.54 ± 1.77	49.50 ± 0.70 <sup>b</sup>	42.00 ± 4.24 <sup>b</sup>
APN+GEN	11.37 ± 1.44	33.19 ± 3.79*	77.00 ± 5.20*
APN+CEF	9.00 ± 1.34*	36.00 ± 4.24*	61.50 ± 4.95*
APN+MMF	10.39 ± 0.81	53.00 ± 5.57	26.74 ± 3.06*
APN+GEN+MMF	13.08 ± 2.51	69.00 ± 7.07*	28.00 ± 1.41*
APN+CEF+MMF	12.77 ± 1.33	32.50 ± 3.54*	70.33 ± 5.10*

TWBC = Total white blood cells, TNTP = Total neutrophils, TLMT = Total lymphocytes. Different superscript (a and b) represent the significant (*P* < 0.05) differences between control and +APN groups and stars (\*) indicating significant differences between +APN and other test groups at the same column.

contrast, simultaneously administration of CEF and MMF remarkably recovered the +APN-induced hematological disorders.

### Biochemical parameters alterations

Comparing the control and APN groups showed that following 3 days after APN induction in the +APN group, from the biochemical biomarkers creatinine but not BUN increased significantly ( $P < 0.05$ ). The measurements on 14 days after APN induction demonstrated a substantial increase of both parameters. On day 3, no significant differences were found between the APN group and other groups except animals which received GEN plus MMF that showed a

significant ( $P < 0.05$ ) increase in BUN level [Table 3]. It was found that following 14 days treatment with GEN and/or CEF alone, CEF could return the biochemical changes significantly ( $P < 0.05$ ) to normal level. This experiment showed also a substantial increase of both BUN and creatinine in serum of the animals, which received the GEN and MMF, simultaneously. At the same time, co-administration of CEF and MMF resulted in a slight decrease of APN-induced elevation of BUN and a significant decline in creatinine level.

### MIC and MBC and IZD

The first outcome of conducted assays indicates that GEN alone exerted a potent antibacterial effect against *E. coli*. MPA had no antibacterial effect on *E. coli* which used to induce APN in this study. Moreover, GEN + MPA, although increased the MBC value, the MIC value was not altered. At the same time the combination of CEF + MPA caused a significant decrease in diameter of the inhibition zone with an increase in MBC value. The values of IZ for both concentrations (MIC and MBC concentrations) were found slightly lower than that of individual treatment [Table 4].

### Histopathological findings

In the current study, no pathological lesions were observed in the left and right kidneys of the control group [Figures 1a and 2a]. In the APN group, however, as numerically scored in Table 5 and depicted in Figures 1b and 2b, remarkable infiltration of the leukocytes and the occurrence of hemorrhages and hydropic degeneration representing acute phase of the experimentally induced infection were observed. The total score calculated by summing all scores in individual group and an average of three sections was obtained for each kidney. Although 14 days treatment with GEN could diminish the severity of the histological abnormalities, some pathological lesions such as focal leukocyte infiltration, fibroblastic proliferation along with broad congestion did not return to the normal [Figures 1c and 2c]. The kidneys in the CEF-treated group of animals showed less severe inflammatory feature with mild congestion, cell swelling, and focal fibroblastic proliferation [Figures 1d and 2d]. The histopathological lesions such as congestion, cell swelling,

**Table 3: Biochemical changes in serum of the rats after treatment with proposed compounds; for each group n = 8, mean values ± SD (mg/dl) are given.**

Groups	BUN (3 days)	BUN (14 days)	CTN (3 days)	CTN (14 days)
Control	25.33 ± 3.21 <sup>a</sup>	23.00 ± 3.00 <sup>a</sup>	0.45 ± 0.06 <sup>a</sup>	0.43 ± 0.02 <sup>a</sup>
APN	28.67 ± 1.53 <sup>a</sup>	31.67 ± 3.06 <sup>b</sup>	0.63 ± 0.06 <sup>b</sup>	0.70 ± 0.04 <sup>b</sup>
APN+GEN	31.00 ± 6.56	27.50 ± 2.83	0.67 ± 0.15	0.63 ± 0.10
APN+CEF	28.67 ± 4.73	22.00 ± 2.83 <sup>*</sup>	0.63 ± 0.06	0.53 ± 0.06 <sup>*</sup>
APN+MMF	27.35 ± 2.65	23.20 ± 2.54 <sup>*</sup>	0.74 ± 0.0	80.80 ± 0.05
APN+GEN+MMF	90.67 ± 22.37 <sup>*</sup>	448 ± 67.55 <sup>*</sup>	0.73 ± 0.06	2.13 ± 0.4 <sup>*</sup>
APN+CEF+MMF	32.67 ± 2.52	30.50 ± 0.71	0.62 ± 0.06	0.53 ± 0.06 <sup>*</sup>

Different superscript (a and b) represent the significant ( $P < 0.05$ ) differences between control and +APN groups and stars (\*) indicating significant differences between +APN and other test groups in the same column.

**Table 4: MIC, MBC (µg/ml) and IZ (mm) of the tested compounds against *E. coli***

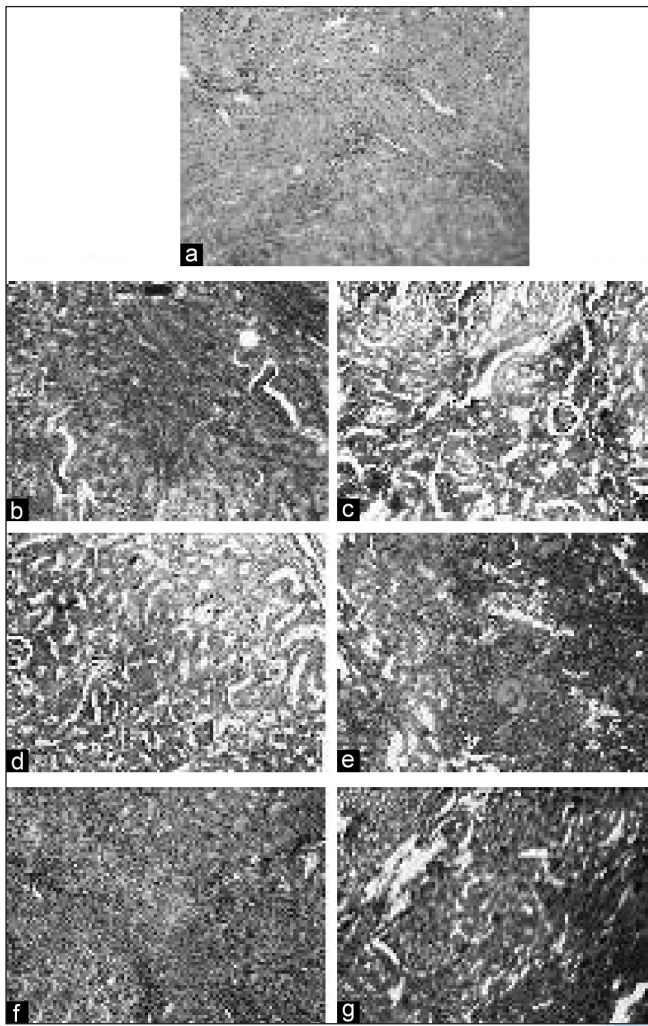
Groups	MIC	MBC	IZ <sub>(MIC)</sub>	IZ <sub>(MBC)</sub>
GEN	0.078	0.078	24.5	24.5
CEF	50	50	25	25
MPA	ND	ND	ND	ND
GEN+MPA	0.078	0.156	23.5	22
CEF+MMF	50	100	23.5	20

ND = Not detected

**Table 5: Pathological findings in the left kidney following APN induction and given regimens of the treatments; mean values ± SD are given**

Groups	C	H	D	LI	FP
Control	0.0 <sup>a</sup>	0.0 <sup>a</sup>	0.0 <sup>a</sup>	0.0 <sup>a</sup>	0.0 <sup>a</sup>
APN	6.9 ± 1.2 <sup>b</sup>	9.0 ± 1.2 <sup>b</sup>	6.9 ± 1.2 <sup>b</sup>	9.0 ± 0.7 <sup>b</sup>	1.8 ± 0.4 <sup>b</sup>
APN+GEN	6.0 ± 0.3	4.8 ± 0.7 <sup>*</sup>	3.0 ± 0.3 <sup>*</sup>	3.0 ± 0.0 <sup>*</sup>	0.9 ± 0.2
APN+CEF	3.0 ± 0.3 <sup>*</sup>	3.0 ± 0.3 <sup>*</sup>	7.8 ± 1.3	4.8 ± 0.6 <sup>*</sup>	4.8 ± 0.9 <sup>*</sup>
APN+MMF	4.8 ± 0.6 <sup>*</sup>	3.0 ± 0.4 <sup>*</sup>	6.0 ± 0.6	7.8 ± 1.5	3. ± 0.6
APN+GEN+MMF	6.0 ± 0.5	6.0 ± 0.7 <sup>*</sup>	9.0 ± 1.4 <sup>*</sup>	9.0 ± 1.6	6.0 ± 0.8 <sup>*</sup>
APN+CEF+MMF	6.0 ± 0.7	6.0 ± 0.8	9.0 ± 0.9	6.0 ± 0.6	3.0 ± 0.5

Different superscript (a and b) represent the significant ( $P < 0.05$ ) differences between control and +APN groups and stars (\*) indicating significant differences between +APN and other test groups at the same column. C = Congestion; H = Hemorrhages; D = Degeneration; LI = Leukocyte Infiltration; and FP = Fibroblast proliferation.

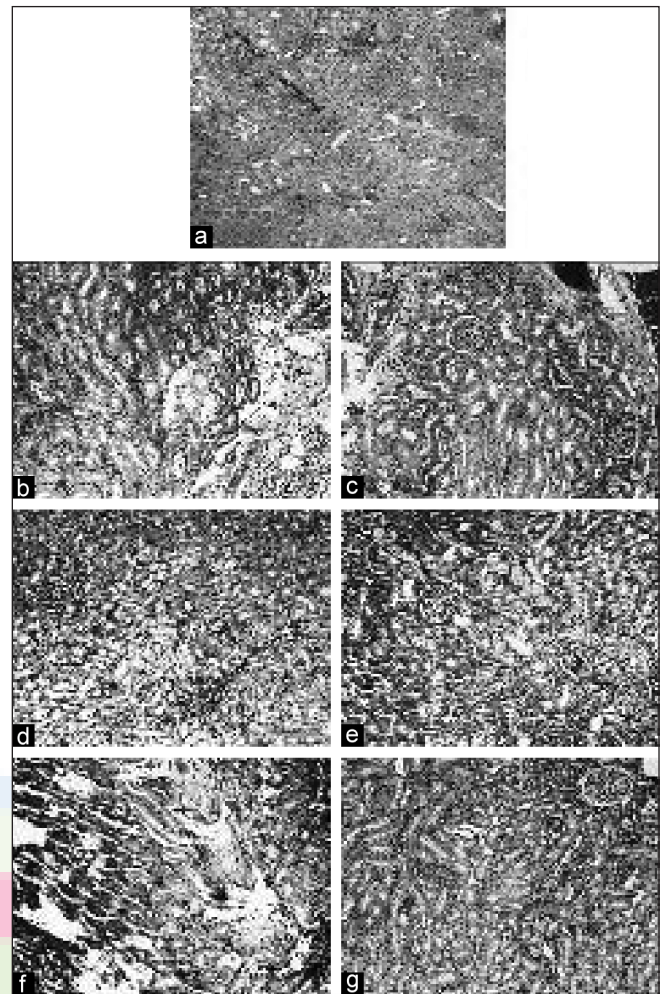


**Figure 1:** Representative micrographs of the rat left kidney in (a) control, (b) +APN/+NS; the leukocyte infiltration into parenchyma along with congestion are seen, (c) +APN/+GEN; remarkable decrease of inflammatory cells infiltration is observed, (d) +APN/+CEF: cell swelling and degeneration are noticed, (e) +APN/+MMF; the glomerular swelling is observed, (f) +APN/+GEN+MMF; the inflammatory cells infiltration along with degenerative changes are present, and (g) +APN/+CEF+MMF; the focal necrosis and cells swelling are observed (H and E, ×100)

and very mild leukocyte infiltration were observed in the MMF-treated animals [Figures 1e and 2e]. Co-administration of GEN with MMF during 14 days failed to recover the APN-induced pathological lesions. Moreover, the situation became severely abnormal and glomerular swelling, hydropic degeneration, and cell swelling were seen [Figures 1f and 2f]. Histopathologically, although those animals which received simultaneously CEF and MMF showed less leukocyte infiltration, at the same time lesions such as the cortical congestion, mild hydropic degeneration, and focal necrosis were also observed [Figures 1g and 2g].

## Discussion

This study demonstrated that GEN is not an appropriate



**Figure 2:** Representative micrographs of the rat right kidney in (a) control, (b) +APN/+NS; congestion, hydropic degeneration and focal leukocytic infiltration are seen, (c) +APN/+GEN; focal leukocytic infiltration and fibroblastic proliferation are noticed, (d) +APN/+CEF; cell swelling and focal fibroblastic proliferation are observed, (e) +APN/+MMF; congestion and very mild focal leukocytic infiltration are seen, (f) +APN/+GEN+MMF; hydropic degeneration and the glomerular swelling are noticed, and (g) +APN/+CEF+MMF; the cortical congestion along with mild hydropic degeneration and focal necrosis are seen (H and E, ×100)

choice for the treatment of APN in cases which simultaneously are treated with immunosuppressive agents such as MMF. Comparing the +APN and the control groups indicated that 3 days after APN induction a significant increase in TWBC and TNTP occurred signaling out an acute infection. At the same time a significant elevation of both BUN and creatinine levels confirmed that the infection most likely affected the kidneys.

In the management of APN, using effective antibiotics and attempts to reach a high concentration of chosen antibiotic in renal parenchyma are key considerations. Most commonly used antibiotics in APN are one of the followings: (1) fluoroquinolones; (2) aminoglycosides; or (3) an extended-spectrum cephalosporin.<sup>[16]</sup> GEN and CEF administration in this study relatively could

diminish the severity of the APN. It seemed however none of them were able to cure completely the functional and pathological disorders induced by APN. The possible reason for this finding might be related to nephrotoxicity of aminoglycosides. It has been demonstrated that the aminoglycosides are nephrotoxic because part of the given antibiotic is accumulated in epithelial cells.<sup>[17]</sup> Comparing two antibiotics used in this study revealed that CEF showed relatively better outcome as reflected by hematological and biochemical assays [Tables 1-3]. The most acceptable explanation for this finding could be related to the CEF pharmacokinetics as it is not only eliminated by the renal system but it is equally eliminated by the hepatic system too. Thus, it might be concluded that the CEF administration unlike to GEN, does not cause serious renal disorder. It has been reported that CEF plasma concentration increased in human critical care patients suffering from acute renal failure suggesting that in certain conditions such as renal and hepatic acute disorders, CEF may cause adverse effects.<sup>[18]</sup>

In management of the uncomplicated form of APN, patients do not essentially require to be hospitalized and 14 days antibiotic therapy will be adequate to overcome the disease.<sup>[19]</sup> This strategy, however, certainly would be inadequate in complicated APN. There are accumulating data indicating that in a high percentile of the transplanted patients the incidence of APN is high, representing a frequently occurring form of complicated APN.<sup>[20]</sup> Certainly the effective management of these patients cannot be as simple as in uncomplicated APN cases. For example, in patients with organ transplantation along with antibiotic therapy, the administration of immunosuppressive agents such as MMF would be essential.

The second part of this study was devoted to clarify the impact of co-administration of MMF with widely used antibiotics. Co-administration of GEN with MMF not only did not recover the APN-induced injuries but also resulted in remarkable increases in serum level of BUN, creatinine and inflammatory cells in the blood. Previous data reported the nephrotoxicity of aminoglycosides could be characterized with nonoliguric renal failure and a rise in serum creatinine.<sup>[21]</sup> There is, however, lack of knowledge to show any chemical or pharmacological incompatibility between aminoglycosides and in particular GEN and MMF. We do suggest an interaction, which might be related to the pharmacokinetics, mainly the common way of excretion of both compounds. It is well established that aminoglycosides largely are excreted via urine and due to accumulation in renal epithelial cells they can cause lipid peroxidation and an increased expression of heat shock protein 72 leading to considerable damage in the kidneys.<sup>[22,23]</sup> On the other hand, it has been reported

that MMF after oral administration is absorbed rapidly and hydrolyzed to MPA by estrases. Another possible explanation for incompatibility between GEN and MMF could be possible enzyme up/down-regulation by GEN and consequently changing the concentration of MPA and other metabolites of MMF in plasma. This hypothesis has been demonstrated for some enzymes including gamma-glutamyltransferase, beta-N-acetylglucosaminidase, which following GEN-treatment the activity of them increased significantly.<sup>[24]</sup>

Another major concern regarding the co-administration of GEN and MMF could be the interaction of these compounds in renal system. The MPA glucuronide (MPAG) metabolite is excreted into the urine via active tubular secretion.<sup>[25,26]</sup> The urinary excretion of MPAG and GEN-induced nephrotoxicity may explain the biochemical and histopathological negative impact of concomitant administration of MMF with GEN.

The increase of the BUN and creatinine levels after 14 days treatment with GEN plus MMF clearly indicates a dysfunction of the kidneys. These biochemical findings are firmly supported by our histopathological findings in the kidney tissues. Histopathological findings such as regenerative lesions by inflammatory cells infiltration and degenerative alteration by granulation of epithelial cells all indicate an aminoglycoside nephrotoxicity.<sup>[17]</sup> Therefore, it would be reasonable conclusion that MMF co-administration with GEN may strengthen the aminoglycoside-induced nephrotoxicity. Although co-administration of CEF and MMF was able to recover partly the hematological and biochemical changes, CTF was unable to cure the pathological damage. The reason for this various effects of the combination might be explained by the fact that the recovery of pathological damage requires relatively long period of time.

In general, determination of MIC and MBC values are required to clarify the presence or the absence of resistance mechanism(s) and also to highlight whether the selected compound exerts an antibacterial effect on chosen pathogen.<sup>[27]</sup> In this study, the obtained MIC values for GEN and CEF support the MIC values which are suggested by European committee on antimicrobial susceptibility testing (EUCAST) for GEN of >4 mg/l, and the recommended CLSI breakpoint of  $\geq 16$  mg/l for various strains of *E. coli*.<sup>[28]</sup> According to CLSI guideline, it became clear that the strain of *E. coli* used in this study could be categorized as susceptible to GEN and CEF.<sup>[29]</sup>

In conclusion, this study showed that CEF plus MMF could be applied for the treatment of complicated APN. However, in APN cases which co-administration of GEN with MMF is provided, the biochemical and histopathological abnormalities may occur. Moreover, the hematological and biochemical negative alterations could be used as reliable laboratory tools to monitor the combination therapy.

## Acknowledgments

The authors are grateful to Professor Adelbert van Miert from Utrecht University (the Netherlands) and Dr. Hadian M from Urmia University (Iran) for their proof reading.

## References

1. Tugtepe H, Sener G, Cetinel S, Velioglu-Ogunc A, Yegen BC. Oxidative renal damage in pyelonephritic rats is ameliorated by montelukast, a selective leukotriene CysLT1 receptor antagonist. *Eur J Pharmacol* 2007;557:69-75.
2. Nicolle LE, Friesen D, Harding GK, Roos LL. Hospitalization for acute pyelonephritis in Manitoba, Canada, during the period from 1989 to 1992: Impact of diabetes, pregnancy, and aboriginal origin. *Clin Infect Dis* 1996;22:1051-6.
3. Wing DA, Hendershott CM, Debuque L, Millar LK. A randomized trial of three antibiotic regimens for the treatment of pyelonephritis in pregnancy. *ObstetGynecol* 1998;92:249-53.
4. Chong CY, Tan AS, Ng W, Tan-Kendrick A, Balakrishnan A, Chao SM. Treatment of urinary tract infection with gentamicin once or three times daily. *ActaPaediatr* 2003;92:291-6.
5. Wu CY, Chiu PC, Hsieh KS, Chiu CL, Shih CH, Chiou YH. Childhood urinary tract infection: A clinical analysis of 597 cases. *ActaPaediatr Taiwan* 2004;45:328-33.
6. Hellerstein S. Antibiotic treatment for urinary tract infections in pediatric patients. *Minerva Pediatr* 2003;55:395-406.
7. LeBrun M, Grenier L, Gourde P, Bergeron MG, Labrecque G, Beauchamp D. Effectiveness and toxicity of gentamicin in an experimental model of pyelonephritis: Effect of the time of administration. *Antimicrob Agents Chemother* 1999;43:1020-6.
8. Thibault N, Grenier L, Simard M, Bergeron MG, Beauchamp D. Attenuation by daptomycin of gentamicin-induced experimental nephrotoxicity. *Antimicrob Agents Chemother* 1994;38:1027-35.
9. Beauchamp D, Laurent G, Grenier L, Gourde P, Zanen J, Heuson-Stiennon JA, *et al.* Attenuation of gentamicin-induced nephrotoxicity in rats by fleroxacin. *Antimicrob Agents Chemother* 1997;41:1237-45.
10. Takahashi S, Hirose T, Satoh T, Kato R, Hisasue SI, Takagi S, *et al.* Efficacy of a 14-day course of oral ciprofloxacin therapy for acute uncomplicated pyelonephritis. *J Infect Chemother* 2001;7:255-7.
11. González-Roncero FM, Gentil MA, Brunet M, Algarra G, Pereira P, Cabello V, *et al.* Pharmacokinetics of mycophenolate mofetil in kidney transplant patients with renal insufficiency. *Transplant Proc* 2005;37:3749-51.
12. Bergeron MG. Treatment of pyelonephritis in adults. *Med Clin North Am* 1995;79:619-49.
13. Fernandez A, Marcen R, Pascual J, Martins J, Villafuela JJ, Cano T, *et al.* Mycophenolatemofetil levels in stable kidney transplant recipients. *Transplant Proc* 2007;39:2182-4.
14. Kaye D. The effect of water diuresis on spread of bacteria through the urinary tract. *J Infect Dis* 1971;124:297-305.
15. National Committee for Clinical Laboratory Standards (NCCLS). *Methods for Dilution Antimicrobial Susceptibility Tests for Bacteria that Grow Aerobically—Third Edition: Approved Standard* 1993; M7-A3: Villanova, PA, USA: NCCLS.
16. Warren JW, Abrutyn E, Hebel JR, Johnson JR, Schaeffer AJ, Stamm WE. Guidelines for antimicrobial treatment of uncomplicated acute bacterial cystitis and acute pyelonephritis in women. *Infectious Diseases Society of America (IDSA). Clin Infect Dis* 1999;29:745-58.
17. Mingeot-Leclercq MP, Tulkens PM. Aminoglycosides: Nephrotoxicity. *Antimicrob Agents Chemother* 1999;43:1003-12.
18. Heinemeyer G, Link J, Weber W, Meschede V, Roots I. Clearance of ceftriaxone in critical care patients with acute renal failure. *Intensive Care Med* 1990;16:448-53.
19. Nickel JC. The management of acute pyelonephritis in adults. *Can J Urol* 2001;8:29-38.
20. Kamath NS, John GT, Neelakantan N, Kirubakaran MG, Jacob CK. Acute graft pyelonephritis following renal transplantation. *Transpl Infect Dis* 2006;8:140-7.
21. Yanagida C, Ito K, Komiya I, Horie T. Protective effect of fosfomycin on gentamicin-induced lipid peroxidation of rat renal tissue. *ChemBiol Interact* 2004;48:139-47.
22. Garry F, Chew DJ, Hoffsis GF. Enzymuria as an index of renal damage in sheep with induced aminoglycoside nephrotoxicosis. *Am J Vet Res* 1990;51:428-32.
23. Zhipeng W, Li L, Qibing M, Linna L, Yuhua R, Rong Z. Increased expression of heat shock protein (HSP) 72 in a human proximal tubular cell line (HK-2) with gentamicin-induced injury. *J ToxicolSci* 2006;31:61-70.
24. Sam WJ, Akhlaghi F, Rosenbaum SE. Population pharmacokinetics of Mycophenolic Acid and its 2 glucuronidated metabolites in kidney transplant recipients. *J Clin Pharmacol* 2009;49:185-95.
25. Staatz CE, Tett SE. Clinical pharmacokinetics and pharmacodynamics of mycophenolate in solid organ transplant recipients. *Clin Pharmacokinet* 2007;46:13-58.
26. Brum S, Nolasco F, Sousa J, Ferreira A, Possante M, Pinto JR, *et al.* Leukopenia in kidney transplant patients with the association of valganciclovir and mycophenolatemofetil. *Transplant Proc* 2008;40:752-4.
27. Stachyra T, Lévassieur P, Pechereau MC, Girard AM, Claudon M, Miossec C, *et al.* *in vitro* activity of the  $\beta$ -lactamase inhibitor NXL104 against KPC-2 carbapenemase and Enterobacteriaceae expressing KPC carbapenemases. *J Antimicrob Chemother* 2009;64:326-9.
28. Jakobsen L, Sandvang D, Jensen VF, Seyfarth AM, Frimodt-Møller N, Hammerum AM. Gentamicin susceptibility in *Escherichia coli* related to the genetic background: Problems with breakpoints. *Clin Microbiol Infect* 2007;13:830-2.
29. Clinical and Laboratory Standards Institute. *Performance Standards for Antimicrobial Susceptibility Testing: Eighteenth Informational Supplement* 2008;M100-S18; Wayne, PA, USA: CLSI.

**How to cite this article:** Malekinejad H, Nikibakhsh A, Gholizadeh-Soltani S, Farshid A. Interaction between gentamicin and mycophenolate mofetil in experimentally induced pyelonephritis. *Indian J Nephrol* 2012;22:26-32.

**Source of Support:** Nil, **Conflict of Interest:** None declared.