

The Protective Effect of Penicillamine Against Bleomycine Induced Pulmonary Fibrosis in Rats**¹Peyman Mikaili, ²Ali Asghar Hemmati, ²Mohammad Javad Khodayar, ³Mehri Ghafurian and ⁴Iran Rashidi**¹*Department of Pharmacology, School of Medicine, Urmia University of Medical Sciences, Urmia, Iran.*²*Department of Pharmacology and Toxicology, School of Pharmacy, Jondishapour University of Medical Sciences, Ahwaz, Iran.*³*Department of Immunology, Jondishapour University of Medical Sciences, Ahwaz, Iran.*⁴*Department of Pathology, Jondishapour University of Medical Sciences, Ahwaz, Iran.*

Peyman Mikaili, Ali Asghar Hemmati, Mohammad Javad Khodayar, Mehri Ghafurian and Iran Rashidi; The Protective Effect of Penicillamine Against Bleomycine Induced Pulmonary Fibrosis in Rats.

ABSTRACT

Pulmonary fibrosis is commonly progressive and essentially untreatable disease, with a fatal outcome. A good knowledge of the underlying mechanisms of pathogenesis of this chronic disease may pave the way, to achieve the better resolutions of treating human lung fibrosis. In this study, we evaluated the involving processes of fibrosis and their inhibition or prevention, in the three levels, namely, at [I] cellular level [inflammatory leukocytes, fibroblasts, myofibroblasts and pulmonary tissue cells], [II] tissue index factors [collagen, hydroxyproline], [III] pathophysiological or exaggerated physiological processes [inflammation, fibrosis]. The pharmacological agent which are selected for evaluation in this study is penicillamine. Bleomycin-induced pulmonary fibrosis is a widely used animal model for lung injury and fibrosis. After single dose instillation of intratracheal bleomycin, the fibrotic responses were studied by biochemical measurement of collagen deposition and analysis of pathological lung changes in different treatment groups. The results of this study showed that administrated agents in different doses, had satisfactorily healing effects on fibrosis process, ranging from good to moderate, through significant decreasing in lung collagen content [$P < 0.05$].

Key words: Pulmonary fibrosis, Bleomycin, Penicillamine, L- Hydroxyproline, Rat.**Introduction**

Bleomycin is commonly used as a part of the cytostatic treatment of several tumor types, such as germ-cell tumors, lymphomas, and Kaposi's squamous cell carcinomas of head and neck. The application of bleomycin is featured by the occurrence of some fatal side effects. Pulmonary toxicity is the most serious side effect of BLM. In lung, the toxicity of BLM involved inflammation and fibrosis. Bleomycin-induced pulmonary fibrosis is an animal model for lung injury and fibrosis [1]. Pulmonary fibrosis, idiopathic or otherwise, is commonly progressive and essentially untreatable, with a fatal outcome [2,3]. There are five million people worldwide that are affected by this disease. In the United States there are over 200,000 patients with Pulmonary Fibrosis. As a consequence of misdiagnosis the actual numbers may be significantly higher. *Of these more than 40,000 expire annually.* This is the same as the people who die from Breast

Cancer. Typically, patients are in their forties and fifties when diagnosed. However, diagnoses have ranged from age seven to the eighties. The pathogenesis of pulmonary fibrosis remains incompletely understood. Studies of associated inflammation have led to the discovery of a number of cytokines and chemokines that are found to be important either directly or indirectly for the fibrotic process. So, it is clear from a rather wide body of work that the underlying mechanism involves dysregulation and overproduction of certain cytokines [1,2,4,5]. However, the importance of inflammation in pulmonary fibrosis is unclear, and at the time of diagnosis the inflammatory component is variable and usually not responsive to anti-inflammatory therapeutic agents. A central mechanism appears to involve continued overproduction of TGF- β [transforming growth factor], which could in turn increase the production, activity, or both of CTGF [connective-tissue growth factor] [3,6-10]. In addition to promoting myofibroblast differentiation, transforming growth

Corresponding Author

Peyman Mikaili, Department of Pharmacology, School of Medicine, Urmia University of Medical Sciences, Urmia, Iran.

E-mail: peyman_mikaili@yahoo.com

factor- β [especially TGF- β 1] provides protection against apoptosis. Thus, this well-known fibrogenic cytokine is important both for the emergence of the myofibroblast and its survival against apoptotic stimuli. This is consistent with the critical importance of this cytokine in diverse models of fibrosis in various tissues [11-14]. Considering the abovementioned short introduction, we practically want to investigate the involving phenomena during the process of bleomycin-induced fibrosis in the murine lungs. We are to evaluate the involving processes of fibrosis and their inhibition or prevention, in the three levels, namely, at [I] cellular level [inflammatory leukocytes, fibroblasts, myofibroblasts and pulmonary tissue cells], [II] tissue index factors [collagen, hydroxyproline], [III] pathophysiological or exaggerated physiological processes [inflammation, fibrosis]. The pharmacological agent which are selected for evaluating in this study is Penicillamine, which their selection rationale will be discussed in detail separately in the following sections.

Experimental:

Materials:

Chemicals:

Bleomycin [Nippon Kayaku Co. Ltd, Japan], Ketamine [Rotexmedica Co., Germany], Penicillamine and L-hydroxyproline [the latter three from Sigma Chemical Co, England] were used. All other analytical grade reagents for histology and biochemical assays were bought either from Merck [Germany] or Sigma Chemical Co. [England].

Animals:

Male Sprague–Dawley rats weighing 180–200 g were used during the study. Animals were held in an air-conditioned room with 12 h light cycle at 21–24 °C and 45–55% humidity, and they were fed on standard laboratory chow and tap water *ad libitum*.

Methods:

Induction Of Pulmonary Fibrosis By Bleomycin:

The rats, according to the method of Schraufnagel *et al.*, were anaesthetized with ether, and then they were placed on a slanted board [20 degree from vertical] hanging from their upper incisors [See Figure 5]. Bleomycin [7.5 IU/kg] was delivered via the mouth into the trachea with a modified syringe needle in a volume of 1 ml/kg body weight. So the animals received an intratracheal injection of bleomycin [7.5 IU/kg] in saline solution [15]. The rats were rotated immediately after receiving bleomycin to ensure that good drug distribution occurred in the lung. After recovery from

anesthesia, the rats were returned to their cages and allowed food and water as normal. Control rats received an intratracheal instillation of the same volume of sterile saline. Their food intake, respiration, and activity were observed every day [16].

Drugs Treatment:

The animals were divided into the following groups, [n=6 rats]. 1. A group received only bleomycin as “positive control”. 2. The rats in this group received vehicle [normal saline] as “negative control”. 3. “Treatment-P1 group” received daily penicillamine 50mg/kg/day, 7 days before and 4 weeks after administering single-dose bleomycin [18]. 4. “Treatment-P2 group” received daily penicillamine 300mg/kg/day, 7 days before and 4 weeks after administering single-dose bleomycin [18]. All the administration routes were as intraperitoneal [IP] and the vehicle in all solutions was distilled water. We also investigated the effects of the drugs and the vehicle [without bleomycin] as sham groups. 5. Penicillamine 15mg/kg/day plus the vehicle for 5 weeks as “sham P”.

Determination Of Collagen And Hydroxyproline Content Of Lung Tissue:

Hydroxyproline content of lung tissue was determined by colorimetric method as described by Edwards and O'Brien [20]. Total content of tissue collagen was calculated with the assumption that 12.5% of collagen is constituted of hydroxyproline. Hydroxyproline is extracted from collagen and can be oxidized to pyrrole by chloramine-T, and then it can produce color with *para*-dimethylbenzaldehyde. Tissue samples will be homogenized and processed according to the earlier discussed method. The absorbance will be measured at 500 nm to determine hydroxyproline content. The hydroxyproline value is divided by 0.125 to express collagen content of tissue [mg/g tissue] [21].

Histological Examination:

Lung tissue was fixed by 10% neutral formalin solution for paraffin slides and sectioned at approximately 5- μ m thickness. Tissue affixed to a glass slide deparaffinised, rehydrated and counterstained with hematoxylin and eosin [H&E] or Masson's trichrome. The slides were examined by light microscopy and photographed [21].

Statistical Analysis:

Data will be presented as the mean \pm SEM. For determination of the significant differences, statistical analyses will be performed using student's t-test or one-way ANOVA and also Kruskal-Wallis

by SPSS software. Values of $p < 0.05$ will be regarded as statistically significant.

Results:

Body and Lung Weights:

Generally, there was a significant body weight loss in the groups, which received bleomycin. But the treatment groups had moderate weight loss [Figure 1]. Total wet lung weight was measured as an indicator of lung inflammation due to Bleomycin [7.5 IU/kg]. The results have been tabulated in Figure 2.

Hydroxyproline Content Of Lung:

To determine and analysis of lung fibrosis, lung collagen was measured as hydroxyproline content

after euthanizing animals at the end of the experimental course. Our findings showed that administration of bleomycin [7.5 IU/kg] significantly increased [$p < 0.001$] hydroxyproline level in positive control group. Other groups had different results which have been summarized in the Figure 3.

Histology:

Morphological examination of lungs was carried out at the end of the study course [Figure 4]. Histological analysis showed that the treatment groups had less pathological changes in lung in comparison to the positive control group. However, in different treatment groups, the severity of changes varied from slight to moderate. The comparative analysis of the lung tissue of the different groups has been presented in Figure 4 [a-d], in detail.

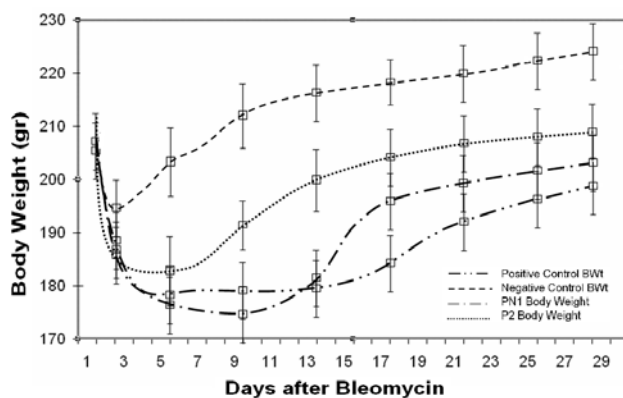


Fig. 1: The effect of bleomycin and/or penicillamine on body weight of the animals during the study. Data are presented as mean \pm SEM of $n = 6$. Positive control: bleomycin [7.5 IU/kg single dose]; negative control: normal saline; P1: penicillamine 50mg/kg/day; P2: penicillamine 300mg/kg/day, BWt: Body Weight.

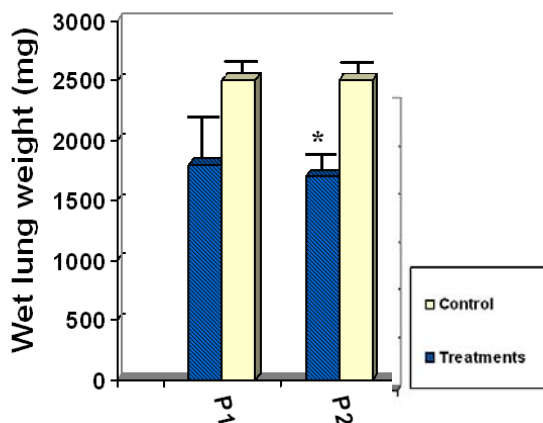


Fig. 2: The effect of bleomycin on wet lung weight of the animals at the end of the study. Data are presented as mean \pm SEM of $n = 6$; * $P < 0.05$ versus positive control. [Positive] control: bleomycin [7.5 IU/kg single dose]; P1: penicillamine 50mg/kg/day; P2: penicillamine 300mg/kg/day.

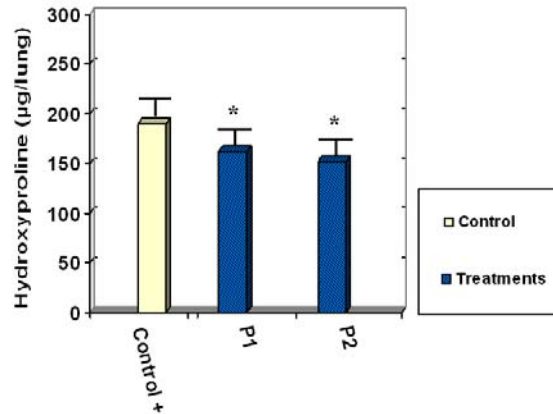


Fig. 3: The effect of bleomycin on lung hydroxyproline content in the studied animals. Hydroxyproline content of lung tissue of mice was measured and normalized to micrograms per lung. Data are presented as mean \pm SEM of n = 6; * P < 0.05 versus control. Positive control: bleomycin [7.5 IU/kg single dose]; P1: penicillamine 50mg/kg/day; P2: penicillamine 300mg/kg/day.

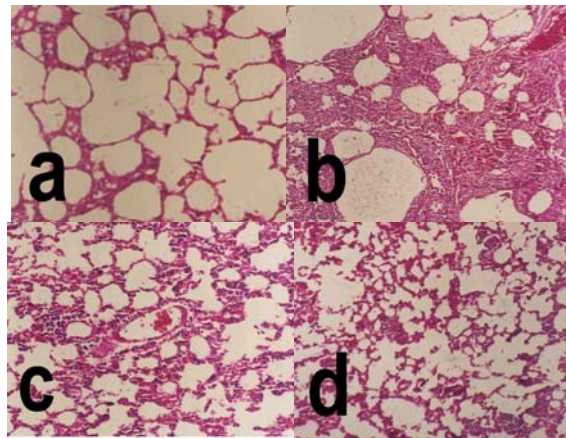


Fig. 4: Hematoxylin-eosin histological sections of lung tissue of different groups [magnifications $\times 100$]. [a] normal lung tissue of saline treated rat [control negative group]; [b] there is an increase in cellularity of alveolar septal and intra-alveolar fibrosis with collagenous bands accompanying great septal thickness and diffuse damage to lung architecture are observed [control positive group]; [c] decreased fibrosis although it can be seen focally somewhere [group P1]; [d] decreased septal thickness versus b, although there are slightly thickened septa focally and fibrosis [group P2]; Positive control: bleomycin [7.5 IU/kg single dose]; P1: penicillamine 50mg/kg/day; P2: penicillamine 300mg/kg/day.

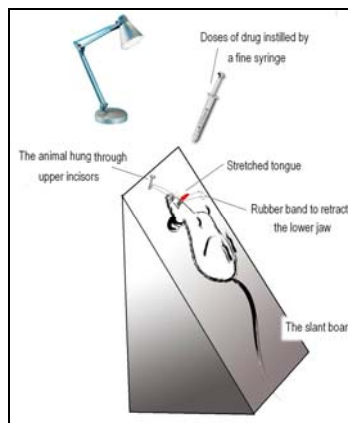


Fig. 5: Diagrammatic representation of the method for intratracheal installation in the anesthetized rat.

Discussion:

Severe lung injury induces excessive cell death. Maintaining normal function and repair of parenchymal cells is the key to improving the prognosis of patients. Excessive cell death of parenchymal cells means irreversible tissue damage and may lead to pulmonary fibrosis. As mentioned above, Bleomycin-induced pulmonary fibrosis is an animal model for lung injury and fibrosis [22]. In selecting the candidate agents for treatment of pulmonary fibrosis, we have considered patient-oriented factors, such as convenient of administration, the least complications and economical considerations.

It has been shown that copper-decreasing therapy with copper-specific agents, [e. g. Tetrathiomolybdate] can prevent, at least for a time, the growth of many types of advanced and metastatic cancers [23, 24] and pulmonary fibrosis [25] through an antiangiogenic mechanism. The hypothesis underlying this approach is that one or more copper-containing or copper-binding angiogenic promoters [e.g., vascular endothelial growth factor, fibroblastic growth factor [e.g. TGF- β], angiogenin, angiotropin, SPARC, or others] require higher levels of copper to be active than are required for basic cellular needs for copper [25]. In this case, the measurement of serum or urine copper, in the rats, is not necessary, because the penicillamine chelates the free copper and so the monitoring test will be not valid [25]. A series of cytokines involved in the pathogenesis of fibrosis, have a high probability of sharing the copper dependency of the angiogenic cytokines discussed above and that copper-decreasing therapy with copper-decreasing therapy might abrogate the development of pulmonary fibrosis. So in this work, we have provide a copper-decreasing therapy [Penicillamine] to know, if it inhibits development of pulmonary fibrosis in the bleomycin murine model or not. Our results were optimistic for future studies. Penicillamine is indicated in the treatment of Wilson's disease, a copper poisoning inherited condition. Wilson's Disease Treatment has two objectives: I. to minimize dietary intake and absorption of copper. II. to promote excretion of copper deposited in tissues. For the second objective Penicillamine is the only copper chelating agent that is orally effective [26]. We have also considered a low price of this drug, which is routinely used as a toxicity antidote in the clinical practices, in comparison with other similar agents.

From these findings it may be concluded the selected pharmacological agent, like our previous research [27], may be considered as promising and also economical agents or as lead candidates for treatment of pulmonary fibrosis. However further studies are required to define the mechanisms underlying this chronic disease to understand the

precise role of different intervening factors in lung fibrosis.

Acknowledgment

The authors wish to thank Dr. Ardeshir Arzi, Mrs. Engin. Nazari and Mr. Mehdi Sameie for their assistance with this work. This research was supported by a grant from the research council of Ahvaz Jondishapour University of Medical Sciences.

References

1. Nuno R Grandel, Mário ND Peão, Carlos M de Sá and Artur P Águas, 1998. lung fibrosis induced by bleomycin: structural changes and overview of recent advances. *Scanning Microscopy*, 3: 487-494.
2. Coker, R.K., G.J. Laurent, 1997. Anticytokine approaches in pulmonary fibrosis: bringing factors into focus. *Thorax*, 52: 294-6.
3. Zhang, K., S.H. Phan, 1996. Cytokines and pulmonary fibrosis. *Biol. Signals Recept*, 5: 232-9.
4. Smith, R.E., R.M. Strieter, K. Zhang, S.H. Phan, T.J. Standiford, N.W. Lucacs, *et al.*, 1995. A role for C-C chemokines in fibrotic lung disease. *J. Leukoc. Biol.*, 57: 782-7.
5. Hogaboam, C.M., R.E. Smith, S.L. Kunkel, 1998. Dynamic interactions between lung fibroblasts and leukocytes: implications for fibrotic lung disease. *Proc. Assoc. Am. Phys.*, 110: 313-20.
6. Khalil, N., A.H. Greenberg, 1991. The role of TGF-beta in pulmonary fibrosis. *Ciba Found Symp*, 157: 194-211.
7. Border, W.A., N.A. Noble, 1994. Mechanisms of disease: transforming growth factor [beta] in tissue fibrosis. *N. Engl. J. Med.*, 331: 1286-92.
8. Lasky, J.A., L.A. Ortiz, B. Tonthat, G.W. Hoyle, M. Corti, G. Athas, *et al.*, 1998. Connective tissue growth factor mRNA expression is unregulated in bleomycin-induced lung fibrosis. *Am. J. Physiol.*, 275: L365-71.
9. Brigstock, D.R., 1999. The connective tissue growth factor/cysteine-rich 61/nephroblastoma overexpressed [CCN] family. *Endocr. Rev.*, 20: 189-206.
10. Pittet, J.F., M.J.D. Griffiths, T. Geiser, N. Kaminski, S.L. Dalton, X. Huang, *et al.*, 2001. TGF- β is critical mediator of acute lung injury. *J. Clin. Invest.*, 107: 1537-44.
11. Denis, M., 1994. Neutralization of transforming growth factor-beta 1 in a mouse model of immune-induced lung fibrosis. *Immunology*, 82: 584-90.
12. Allen, J.T., R.A. Knight, C.A. Bloor, M.A. Spiteri, 1999. Enhanced insulinlike growth factor binding protein-related protein 2

- [connective tissue growth factor]: expression in patients with idiopathic pulmonary fibrosis and pulmonary sarcoidosis. *Am. J. Respir. Cell. Mol. Biol.*, 21: 693-700.
13. Pittet, J.F., M.J.D. Griffiths, T. Geiser, N. Kaminski, S.L. Dalton, X. Huang, *et al.*, TGF- β is critical mediator of acute lung injury. *J. Clin. Invest.*, 107: 1537-44.
 14. Kuwano, K., M. Yoshimi, T. Maeyama, N. Hamada, M. Yamada and Y. Nakanishi, 2005. Apoptosis Signaling Pathways in Lung Diseases, *Medicinal Chemistry*, 1: 49-56.
 15. Schraufnagel, D.E., D. Mehta, R. Harsbarger, K. Trevianus, N.S. Wang, 1986. Capillary remodeling in bleomycin induced pulmonary fibrosis. *Am. J. Pathol.*, 125: 97-106.
 16. Szapiel, S.V., N.A. Elson, J.D. Fulmer, G.W. Hunninghake, R.G. Crystal, 1979. Bleomycin-induced interstitial pulmonary disease in the nude, athymic mouse. *Am. Rev. Respir. Dis.*, 120: 893-9.
 17. Medical Economics Company, 1998. *Inc. Philadelphia PDR.*, 679-686.
 18. Gupta, B., R.K. Srivastava, K.K. Saxena, D.N. Prasad, 1980. A study on the penicillamine induced gastric ulceration in the rat. *Ind. J. Pharm.*, 4: 247-252.
 19. Melo, S.S., M.R. Arantes, M.S. Meirelles, *et al.*, 2000. Lipid peroxidation in nicotinamide-deficient and nicotinamide-supplemented rats with streptozotocin-induced diabetes. *Acta Diabetol.*, 37: 33-39.
 20. Edwards, C.A., W.D.J. O'Brien, 1980. Modified assay for determination of hydroxyproline in tissue hydrolysate. *Acta Clin. Chem.*, 104: 161-76.
 21. Hemmati, A.A. and R. Hicks, 1999. Increased myofibroblast contractile sensitivity in paraquat pretreated rat lung tissue. *Life Scii.*, 22: 231-237.
 22. Nuno, R. Grande1, Mário ND Peão, Carlos M de Sá and Artur P Águas, 1998. Lung fibrosis induced by bleomycin: structural changes and overview of recent advances. *Scanning Microscopy.*, 3: 487-494.
 23. Brewer, G.J., R.D. Dick, D.K. Grover, V. LeClaire, M. Tseng, M. Wicha, *et al.*, 2000. Treatment of metastatic cancer with tetrathiomolybdate, an anticopper, and antiangiogenic agent: phase I study. *Clin. Cancer.*, 6: 1-10.
 24. Merajver, S.D., J. Irani, K. Van Golen, G.J. Brewer, 1998. Copper depletion as an antiangiogenic strategy in HER2-neu transgenic mice. *Proceedings of the American Association for Cancer Research Conference on Angiogenesis and Cancer, Saginaw.*, B11.
 25. George, J. Brewer, Matthew R Ullenbruch, Robert Dick, Leovigildo Olivarez, and Sem H Phan, 2003. Tetrathiomolybdate therapy protects against bleomycin-induced pulmonary fibrosis in mice. *J. Lab. Clin. Med.*, 141: 210-216.
 26. Goldstein, N.P., W.N. Tauxe, J.T. McCall, R.V. Randall, J.B. Gross, 2005. What Wilson's Disease and its Treatment Have Taught us about the Metabolism of Copper. Observations in 27 cases. *Med. Clin. North. Am.*, 52: 989-1001.
 27. Hemmati, A.A., Mikaili Peyman, M.J. Khdayar, M. Ghafurian and I. Rashidi, 2008. The protective effects of Cetirizine against Bleomycine induced pulmonary fibrosis in rats. *Pak J Med Sci.*, [part II]; 24[6]: 813-820.