

# Spontaneous Rupture and Hemorrhage of Adrenal Pseudocyst Presenting With Acute Abdomen and Shock

Rahim Mahmoulou<sup>1</sup>, Neda Valizadeh<sup>2</sup>

## Abstract

Adrenal gland pseudocysts are not common conditions, and most of them are nonfunctional and asymptomatic. However, large pseudocysts may cause abdominal discomfort and have compressive effects on adjacent organs. They may rupture spontaneously or after trauma, and lead to retroperitoneal hemorrhage and surgical emergency. Herein, we report a case of 21-year-old female who presented with acute abdomen and hemorrhagic shock due to spontaneous rupture of adrenal pseudocyst. She was treated successfully by open surgery, removal of adrenal pseudocyst and unilateral adrenalectomy.

**Iran J Med Sci 2011; 36(4): 311-314.**

**Keywords** • Adrenal • pseudocyst • adrenal cyst • hemorrhagic shock

## Introduction

Adrenal gland cysts and pseudocysts are rare lesions and usually are asymptomatic, but may cause many diagnostic and management difficulties.<sup>1,2</sup> Their sizes vary from several millimeters to 50 cm in different reports.<sup>3</sup> They are mostly occurring in the 4<sup>th</sup> and 5<sup>th</sup> decades of life with female predominance.<sup>4,5</sup> Most of them are benign and unilateral.<sup>2,3</sup> The majority of adrenal cysts is asymptomatic and is accidentally discovered in autopsy or during the radiologic studies such as Ultrasonography, CT scan or MRI performed for other causes.<sup>2,3</sup> Cysts with larger size may cause compressive effect on neighboring organs, or cause abdominal symptoms such as flank pain, nausea and vomiting.<sup>1,2,4</sup> Large size adrenal cysts may rupture spontaneously or after blunt abdominal trauma resulting in massive hemorrhage and retroperitoneal hematoma, which can present with acute abdomen and hypovolemic shock, and imitate acute abdomen.<sup>1,4-6</sup> Papaziogas et al. reported a case of 28-year-old woman presented with acute abdomen and hypovolemic shock due to hemorrhagic pseudocyst of left adrenal gland, and was treated successfully with left adrenalectomy.<sup>4</sup> They suggested that high estrogen levels during pregnancy may cause rapid growth of adrenal cystic lesions and relaxation of cyst wall connective tissue. So, the tendency of adrenal cyst rupture and hemorrhage may increase during pregnancy.<sup>4</sup> Some other authors reported similar cases of large size adrenal cysts that presented with massive hemorrhage and acute abdomen following spontaneously or traumatic rupture in non-pregnant females.<sup>1,5,6</sup>

Herein, we report a case of a young female with spontaneously ruptured large size right adrenal pseudocyst manifested with

<sup>1</sup>Department of General and Thoracic Surgery, Emam Khomeini Hospital, Urmia University of Medical Sciences, Urmia, Iran.

<sup>2</sup>Department of Endocrinology, Emam Khomeini Hospital, Urmia University of Medical Sciences, Urmia, Iran.

### Correspondence:

Neda Valizadeh MD,  
Department of Endocrinology,  
Emam Khomeini Hospital, Ershad street,  
Postal Code: 81351-57157,  
Urmia, Iran.

**Tel:** +98 441 3459538

**Fax:** +98 441 3469935

**Email:** [nvalizadeh2008@gmail.com](mailto:nvalizadeh2008@gmail.com)

Received: 19 April 2011

Revised: 28 May 2011

Accepted: 10 July 2011

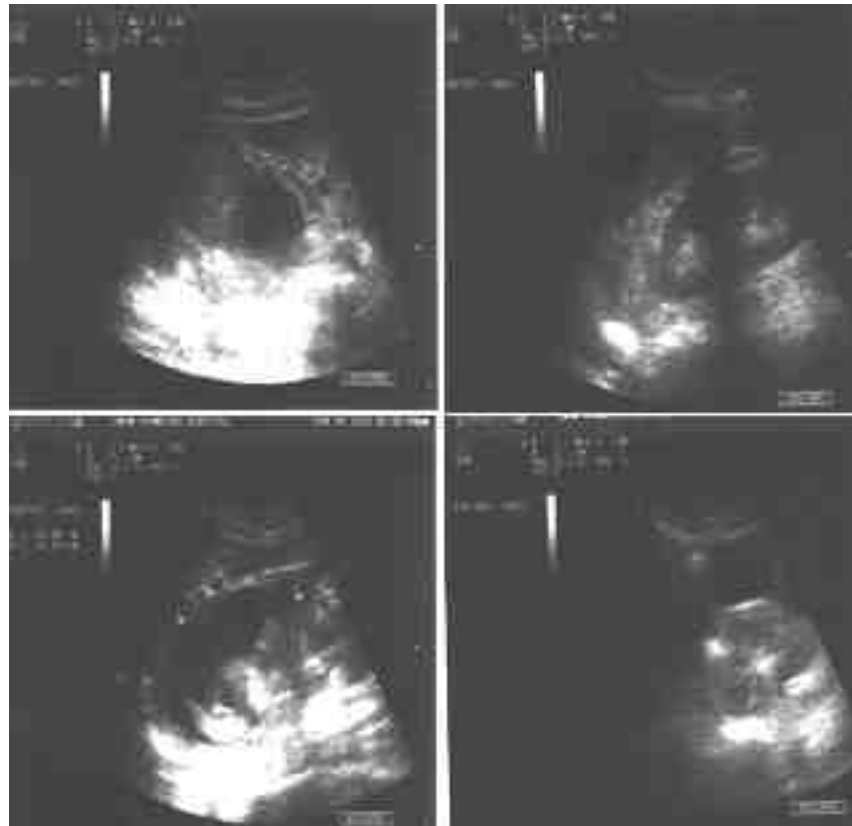
sudden onset abdominal pain, retroperitoneal hematoma and hemorrhagic shock that was resulted in surgical emergency.

### Case Description

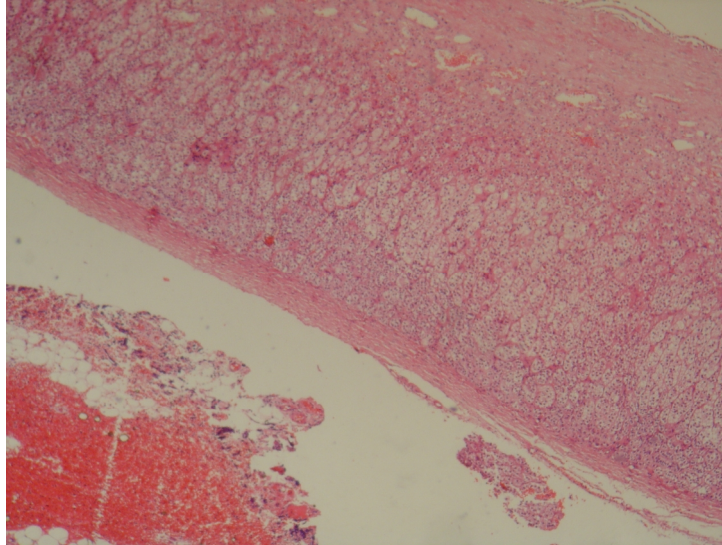
A 21-year-old female presented with right side flank pain over the 12 hours prior to admission. The severity of abdominal pain had increased slowly. She also complained from nausea and vomiting. Because of severe abdominal pain she couldn't walk from few hours prior to the admission, and was, therefore, brought by her roommates to the Emergency Department. She was conscious and pale, and had diaphoresis. Physical examination revealed a blood pressure of 80/60 and a pulse rate of 110/min. After initial resuscitation and stabilization with intravenous fluids, an abdominal ultrasonography was done in emergency room, which showed a giant cystic and solid mass measured 15×15 cm with some free fluid in abdominal cavity and large retroperitoneal hematoma (figure 1). She was transferred to operation room with the preoperative diagnosis of

hemoperitoneum. Midline laparotomy was performed. There was approximately 500 milliliter blood and clots, and a large retroperitoneal hematoma in the right side of abdominal cavity adjacent to renal lodge. Exploration of retroperitoneal hematoma revealed a large cyst with active bleeding in the right adrenal gland. The cystic mass was removed and right side adrenalectomy was done. The post operative phase of the patient was uneventful, and she was discharged with a satisfactory condition on 11<sup>th</sup> day after the surgery.

The macroscopic pathologic study showed that the gross appearance of right adrenal mass consisted of a piece of gray-brown membranous tissue with peripheral fat measuring 7×1.5×0.5 cm. The histopathologic finding included a thick fibrous capsule without prominent epithelial cells in most areas, a wall containing some normal adrenal cortex tissue, the center of the cavity containing hemorrhage, and foamy macrophages compatible with adrenal pseudocyst (figure 2). The patients did not complain during the follow ups until one year after the operation.



**Figure 1:** Abdominal Ultrasonography showing a large cystic and solid mass in right adrenal lodge with retroperitoneal hematoma and some free fluid in abdominal cavity.



**Figure 2:** Adrenal tissue with fibrotic wall without prominent epithelial cells in most areas, containing hemorrhage and foamy macrophages (hematoxylin and eosin staining, original magnification x100).

## Discussion

In previous post-mortem studies the incidence of adrenal cysts was estimated between 0.06% and 0.18% in autopsies.<sup>1,6</sup> The most frequent subtypes of adrenal cysts are pseudocysts and endothelial cysts.<sup>3</sup> Other subtypes including epithelial and parasitic cysts are less prevalent.<sup>2,3</sup> Pseudocysts which are originated from adrenal medulla or cortex are surrounded by a fibrous capsule which separates the cyst from the normal adrenal tissue.<sup>1,7,8</sup> The exact etiology of pseudocyst formation is not clear, but they might be formed secondary to cystic degeneration of a primary or vascular adrenal tumors, or following trauma or infection.<sup>2,5,8</sup> It is also suggested that pseudocysts may develop as a result of loss of cellular coverage of true cystic lesions following inflammation and hemorrhage.<sup>5</sup> There isn't a uniform agreement about the optimal management of adrenal cysts. However, it is possible to conservatively monitor small asymptomatic and nonfunctional lesions with repeated imaging studies.<sup>7</sup> Surgery is recommended for symptomatic and functional cysts as well as those with sizes larger than five cm, which increases the risk of rupture and hemorrhage, or with suspicious characteristics that increases the risk of malignant lesion or complicated cystic lesions.<sup>2,3</sup> Although recently some of surgeons choose the percutaneous drainage approach in the management of adrenal cysts, this approach cannot reliably differentiate between benign adrenal cyst and malignant lesions in all cases.<sup>3,5</sup> Moreover, recurrence of the cyst may occur in some of cases, which are treated with fine-needle aspiration.<sup>3</sup> Surgical excision of cystic lesion can also

provide adequate tissue for making accurate diagnosis.<sup>3,5</sup>

Adrenal cystic lesions may enlarge enough and rupture, and become hemorrhagic in the absence of any symptoms observed in a previously healthy adult. The condition may imitate acute abdomen and result in circulatory shock. In some cases, preoperative diagnosis may be difficult, and accurate diagnosis may be postponed till the time of exploratory laparotomy. Surgical resection of adrenal cysts and open adrenalectomy are curative and life-saving strategies in the presence of acute adrenal cyst rupture and hemorrhage. Tissue diagnosis help eliminate the concerns surrounding the malignancy of the lesion.

## Conclusion

Emergency physicians and surgeons should consider spontaneously adrenal cyst hemorrhage and rupture in the differential diagnosis of any patient with abdominal symptoms or unexplained hemorrhagic shock. Earlier diagnosis and surgical resection of these lesions is curative.

## Acknowledgment

We would like to thank our colleagues in Pathology Department, Emam-Khomaini Hospital, Urmia University of Medical Science, Dr. Farahnaz Noroozinia for pathologic examination, and Dr. Majid Olyaei, for his contribution in providing pathologic figure.

**Conflict of Interest:** None declared

## References

- 1 Favorito LA, Lott FM, Cavalcante AG. Traumatic rupture of adrenal pseudocyst leading to massive hemorrhage in retroperitoneum. *Int Braz J Urol* 2004; 30: 35-6.
- 2 Kim BS, Joo SH, Choi SI, Song JY. Laparoscopic resection of an adrenal pseudocyst mimicking a retroperitoneal mucinous cystic neoplasm. *World J Gastroenterol* 2009; 15: 2923-6.
- 3 Wedmid A, Palese M. Diagnosis and treatment of the adrenal cyst. *Curr Urol Rep* 2010; 11: 44-50.
- 4 Papaziogas B, Katsikas B, Psaralexis K, et al. Adrenal pseudocyst presenting as acute abdomen during pregnancy. *Acta Chir Belg* 2006; 106: 722-5.
- 5 Khilnani GC, Kumar A, Bammigatti C, et al. Hemorrhagic pseudocyst of the adrenal gland causing acute abdominal pain. *J Assoc Physicians India* 2008; 56: 379-80.
- 6 Khan MR, Ajmal S, Saleem T. Giant adrenal endothelial cyst associated with acute and chronic morbidity in a young female: a case report. *Cases J* 2009; 2: 8841.
- 7 Fariña LA, Antón I, Fernández GC. Large adrenal pseudocyst mimicking cystic pheochromocytoma: excision minimising laparoscopic access. *Actas Urol Esp* 2009; 33: 913-6.
- 8 Davenport M, Pollard K, Smith SEW, MacMohan MJ. Adrenal cysts—report, review and classification. *Postgraduate Med J* 1988; 64: 71-3.