

CHEST IMAGING

A. Mohammadi MD

Recurrent Pulmonary Tumoral Embolism and Sudden Death as the Presenting Symptom of Wilms' Tumor

Only 4-6% of children with renal tumor show inferior vena caval (IVC) or right atrial infiltration at presentation. Tumor emboli are even rarer, and so far, sudden death as the presenting symptom has only been described at presentation in Wilms' tumor (WT) in eight cases. We report a unique case of Wilms' tumor that presented with small pulmonary emboli and immediately after that was diagnosed before death by detection of small emboli and immediately after sudden death as massive pulmonary embolism. It seems that in cases of invasive vascular infiltration with a stable hemodynamic condition at diagnosis immediate surgery may be necessary.

Keywords: Wilms' Tumor, Pulmonary Embolism, Sudden Death

Introduction

Wilms' tumor is the most common urinary tract neoplasm of childhood.¹ Only 4-6% of children with renal tumor show inferior vena caval (IVC) or right atrial infiltration at presentation.²⁻⁴ But up to 40% of Wilms' tumors have invaded the renal vein by the time of diagnosis.³ Tumor emboli are even less frequent, and sudden death as the presenting symptom has only been described at presentation in Wilms' tumor (WT) in eight cases so far.² Although pulmonary metastases may already be present in up to one fourth of cases at the time of initial diagnosis, it is exceedingly rare for pulmonary emboli to develop as the first manifestation of Wilms' tumor.^{5,6} We report a unique case of Wilms' tumor that presented with small pulmonary emboli and immediately after developed as a massive saddle mixed tumoral embolism causing the patient's death.

Case Presentation

An 8-year-old boy was in his usual state of good health until 12 hours before the day of admission, when after vomiting he became pale and complained of shortness of breath. On physical examination, the patient was in good general condition and the vital signs were stable. Both lungs were clear to auscultation, but in inspection, mild intercostal retraction was obvious. The abdomen was distended and a firm 10×10 cm abdominal mass, which did not cross the midline was palpable on the left side of the abdomen.

During the first day of admission, apart from microscopic hematuria in the urine analysis (8-10 RBC/hpf), all other laboratory data were normal (arterial blood gas and other laboratory data, such as CBC, ESR, BUN, Cr, Na, K and PH).

CXR was obtained at admission and showed mild right side pleural effusion without pulmonary consolidation or nodular opacity (Fig. 1). Abdominal ultrasonography revealed a large well-marginated hypoechoic mass arising from the lower pole of

Assistant Professor, Department of Radiology, Imam Khomeini Hospital, Urmia University of Medical Sciences, Urmia, Iran.

Corresponding Author:
Afshin Mohammadi
Address: Department of Radiology,
Imam Khomeini Hospital, Urmia, Iran.
Tel: +98441 3447 113
Fax: +98441 3469 939
E-Mail: Mohammadi_Afshin@yahoo.com

Iran J Radiol 2010-7(3): 185-188

the left kidney.

Twenty-four hours after admission, the patient became tachypneic and complained of exacerbation of shortness of breath and chest pain. On physical examination, there was respiratory distress and intercostal retraction on inspection and pulmonary rales in the lower lobe of the right lung on auscultation.

Emergent chest and abdominal CT scan with IV and oral contrast (Spiral CT Scanner, Toshiba, X vision, 50 cc/ultravist 300 mg, IV) were performed for further evaluation of the abdominal mass and respiratory problem. Chest CT showed several pleural-based pulmonary nodules and a wedge-shaped confluence of perivascular pulmonary nodules in the lower lobe of the right lung, with lesser extent in the left lower lobe (Fig. 2). Chest CT also showed a filling defect that extended from IVC to the right atrium (Fig. 3), and a small filling defect in the right pulmonary

artery (Fig. 4). Abdominal CT with IV and oral contrast showed a huge left renal mass extending into the left renal vein and inferior vena cava (Fig. 5).

One hour after symptom aggravation and 24 hours after admission, the patient suddenly collapsed. Unfortunately, resuscitation was not successful. Autopsy confirmed the diagnosis and showed a large left renal mass extending into the left renal vein and inferior vena cava up to the right atrium accompanied with a saddle emboli consisting of a clot and tumoral cells in the pulmonary artery bifurcation (Fig. 6).

Histology revealed a diffuse anaplastic nephroblastoma. The tumor was identified as stage III (Fig. 7).

Discussion

Wilms' tumor is one of the most common tumors in infants and children typically manifesting as an asymptomatic abdominal mass or as abdominal pain, fever and hematuria.⁷

Treatment of Wilms' tumor is a real breakthrough in pediatric oncology with an overall cure rate of over

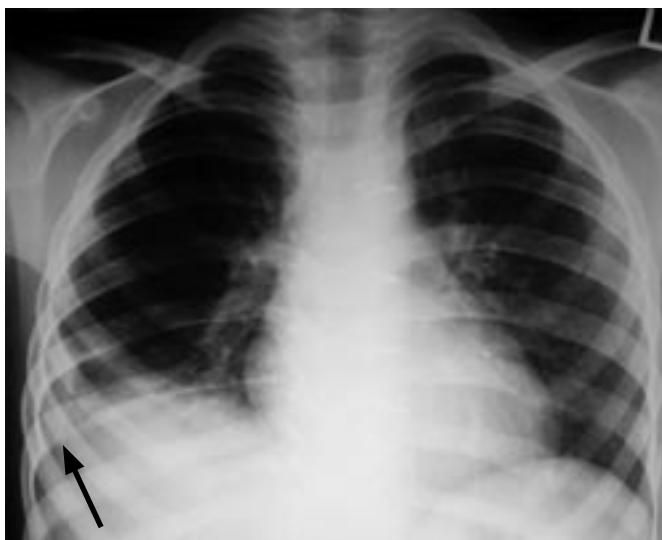

Fig. 1. An 8-year-old boy with respiratory distress. CXR shows right side blunting of the costophrenic angle (black arrow) due to pleural effusion.

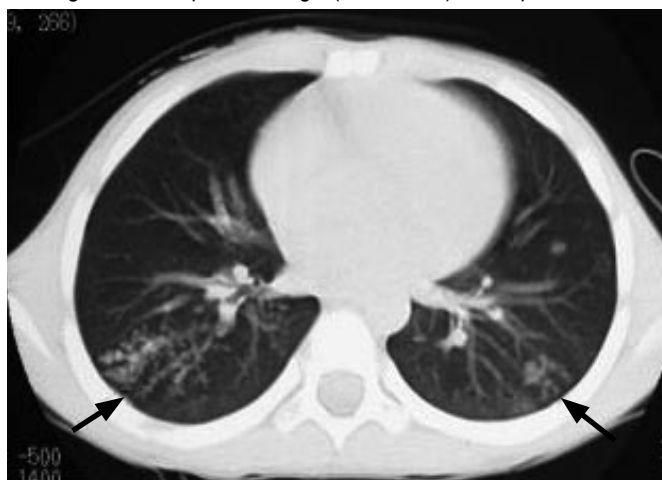

Fig. 2. Axial CT image shows bilateral nodular opacity in both right and left lower lobes (black arrows).

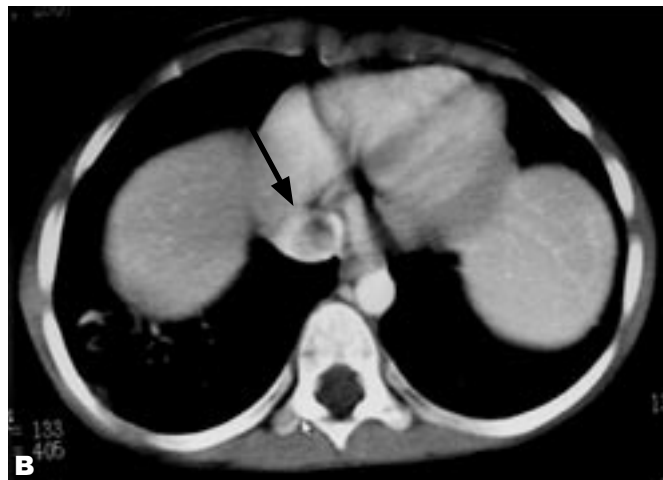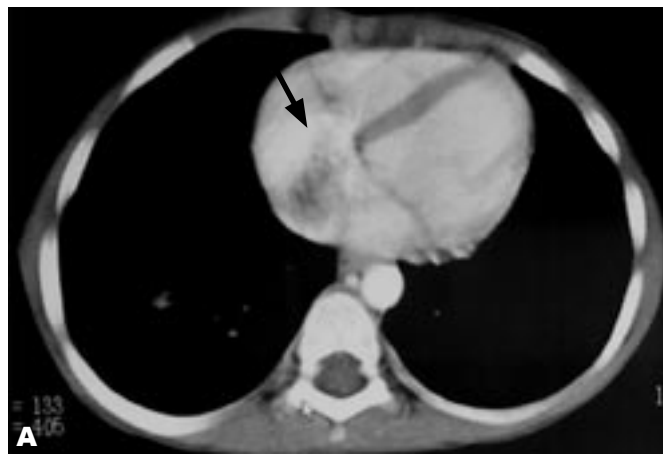


Fig. 3. A&B. Axial CT image shows a hypodense filling defect extending from IVC in to the right atrium (black arrows).

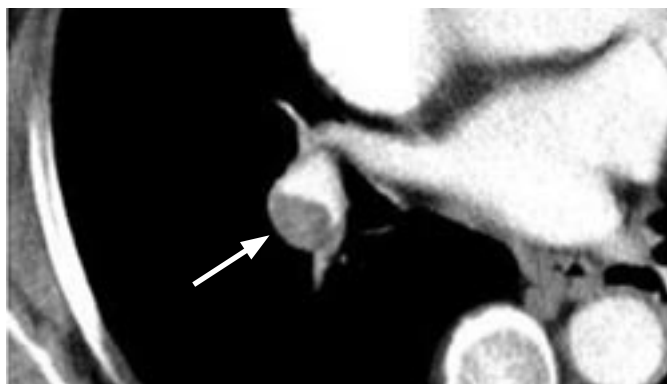

Fig. 4. Axial CT image shows a hypodense filling defect (white arrow) in the right lower lobe branch of the right pulmonary artery.

85% using relatively simple therapies. This excellent outcome is the result of close collaboration between surgeons, pediatricians, pathologists and radiation oncologists. The results that have been achieved from children with Wilms' tumor support the strong value of the multidisciplinary team approach to cancer.⁸

The initial pulmonary tumor emboli causing sudden death as the presenting symptom has only been described at presentation in Wilms' tumor in eight cases so far² (Table 1).

In adults, sudden death has been reported in 11 cases associated with malignancies such as bronchogenic carcinoma, pancreatic carcinoma, leukemia, gastric carcinoma, thyroid carcinoma, urinary bladder carcinoma, astrocytoma and only once in renal tumor.⁹

The low reported incidence of intravascular extension of tumor thrombosis (4-6%)²⁻⁴ may be due to imaging difficulties in the past years. Pulmonary embolism in children and infants is one of the difficult diagnoses on the basis of clinical findings. As WT patients often present without any symptoms, it is

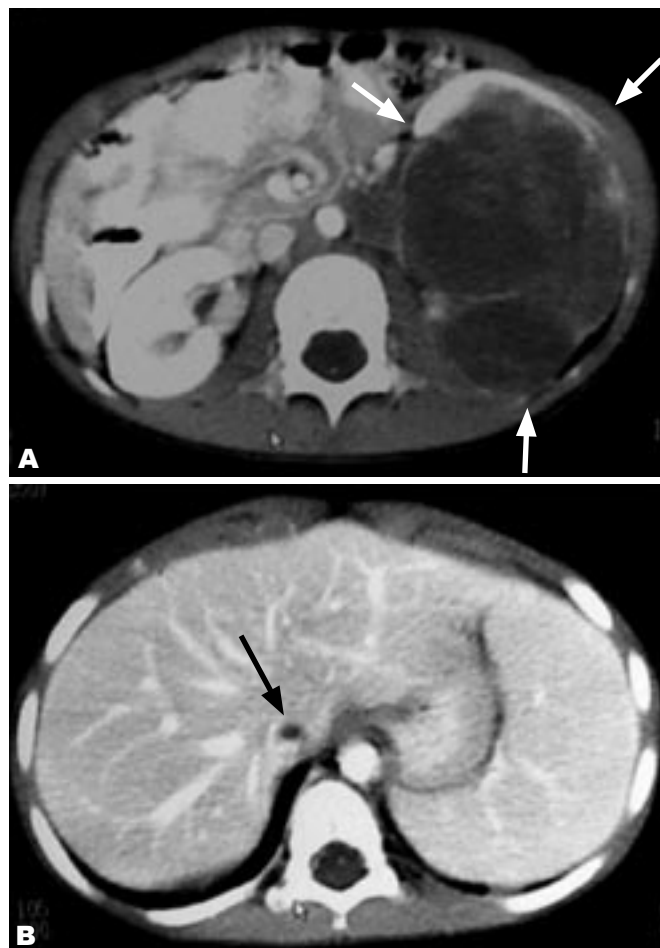


Fig. 5. Axial CT image demonstrates:
A. A large well-defined hypodense mass arising from the lower pole of the left kidney (white arrows) and low-attenuation filling defect within an enlarged left renal vein (white arrowhead) representing direct tumor extension.
B. A low-attenuation filling defect within the hepatic portion of IVC (black arrow).

unlikely to prevent sudden death due to pulmonary tumor embolism as the presenting symptom.

Trapping of most tumor cells within the pulmonary capillaries together with triggering of the coagulation

Table 1. Characteristics of Reported Pediatric Renal Tumor Cases Who Presented with Sudden Death Due to Pulmonary Embolism

Patient	Reported	Sex	Age (year)	Tumor Side	RVI	Stage at Presentation	Histology	Outcome
1	Anselmi et al., 1970	M	4	R	Yes	NFS	WT	Died
2	Zakowski et al., 1990	M	6	R	Yes	4	WT	Died
3	Zakowski et al., 1990	F	7	R	Yes	4	WT	Died
4	Bulas et al., 1991	M	6	R	Yes	4	WT	Died
5	Ceelen et al., 1997	F	3	L	Yes	4	WT	Alive
6	Lampert et al., 2001	F	4	R	Yes	NFS	WT	Died
7	Van den Heuvel-Eibrink, 2008	M	7	L	Yes	4	WT	Died
8	Van den Heuvel-Eibrink, 2008	F	5	L	Yes	3	SS	Died

RVI: Renal Vein Invasion NFS: Not Further Specified

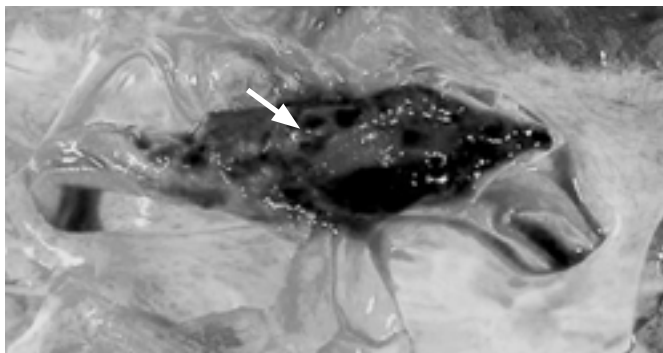


Fig. 6. Autopsy photograph shows a serpiginous mixed tumor and clot embolus at the bifurcation of the pulmonary artery.

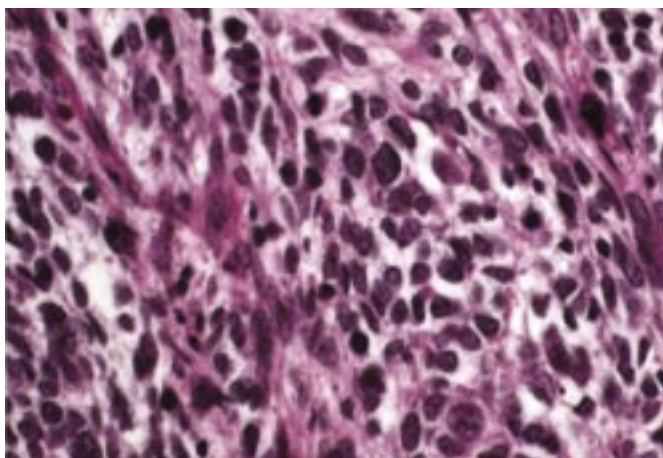


Fig. 7. Pathology revealed nests and sheets of primitive blastema with intervening mesenchyme.

cascade by malignant cells usually causes obstruction of the pulmonary vessels, which may be complete and irreversible.

Some authors believe that a presumptive diagnosis based on atypical presentation and exclusion of thromboembolic disease is adequate.³ Massive tumor embolism is a rare cause of acute respiratory distress in children. Five cases of Wilms' tumor embolization to the lung during intraoperative manipulation have been reported; one patient who was reported with symptoms of pulmonary emboli at presentation survived surgical embolectomy,⁵ two cases whose autopsy revealed massive tumoral emboli as the etiology of sudden death were diagnosed after a sudden collapse.²

Our case is the second case of tumoral embolization diagnosed before surgery or sudden death and the fourth case that pulmonary tumoral embolization is

the first presentation of Wilms' tumor.

We diagnosed all vascular and pulmonary involvements of our patient using contrast enhanced CT scan, considering that CT scan is a valuable method for examining renal vein, IVC and right atrial invasion by WT.

Although it has been shown that chemotherapy before surgery downstages the WT and reduces the risk of tumor ruptures, it is clear that treatment decisions should be made based on the characteristics and stability of the individual patients, especially for those with cardiac involvement.¹⁰

This case demonstrates that WT can embolize preoperatively. We conclude that death due to pulmonary tumor emboli in pediatric renal tumors is rare; and by reviewing the previously published literature in this issue, we think that in cases of invasive vascular infiltration at diagnosis with a stable hemodynamic condition immediate start of surgery may be necessary.

References

1. Jia HM, Zhang KR, Shu H, Tian BL, Wang WL. Presacral extrarenal Wilms' tumor in a child. *Urology* 2009 Aug;74(2):308-10.
2. van den Heuvel-Eibrink MM, Lankhorst B, Egeler RM, Corel LJ, Kollen WJ. Sudden death due to pulmonary embolism as presenting symptom of renal tumors. *Pediatr Blood Cancer* 2008 May;50(5):1062-4.
3. Ceelen W, Kerremans I, Lutz-Dettinger N, Vandebroek P, de Hemptinne B. Wilms' tumour presenting as a pulmonary embolism. *Acta Chir Belg* 1997 Jun;97(3):148-50.
4. Giannoulia-Karadana A, Moschovi M, Koutsovitou P, Tolis G, Tzortzatzou-Stathopoulou F. Inferior vena cava and right atrial thrombosis in children with nephroblastoma: diagnostic and therapeutic problems. *J Pediatr Surg*. 2000 Oct;35(10):1459-61.
5. Zakowski MF, Edwards RH, McDonough ET. Wilms' tumor presenting as sudden death due to tumor embolism. *Arch Pathol Lab Med* 1990 Jun;114(6):605-8.
6. Bulas DI, Thompson R, Reaman G. Pulmonary emboli as a primary manifestation of Wilms' tumor. *AJR Am J Roentgenol* 1991 Jan;156(1):155-6.
7. Castellino SM, Martinez-Borges AR, McLean TW. Pediatric genitourinary tumors. *Curr Opin Oncol* 2009 May;21(3):278-83.
8. Spreafico F, Bellani FF. Wilms' tumor: past, present and (possibly) future. *Expert Rev Anticancer Ther* 2006 Feb;6(2):249-58.
9. Oeberst JL, Bernard JJ, Prahlow JA. Sudden death due to undiagnosed Wilms' tumor in adult. *J ForensicSci* 2002 May;47(3):638-9.
10. Pritchard-Jones K, Pritchard J. Success of clinical trials in Childhood Wilms' tumor around the world. *Lancet* 2004 Oct 23-29;364(9444):1468-70.