

A. Mohammadi MD¹

A Retained Wooden Foreign Body in the Lung Parenchyma Presenting as Aspergiloma

Despite advances in imaging techniques, the detection of retained wooden foreign bodies remains a difficult and challenging task. The detection of wood is especially important because it may serve as a nidus for superimposed infection. The initial examination may mimic malignancy. We report a rare case of retained wooden foreign body in the lung parenchyma, which was found on CXR and CT as a thick-walled cavity. Surgical resection was performed and the wooden particle was removed. Review of literature shows that wooden foreign bodies in the lung parenchyma are quite rare and they may present with a wide variety of density. We conclude that foreign body should be considered in the differential diagnosis of unusual lung opacity.

Keywords: Wood, Foreign Body, Lung

Introduction

Foreign bodies may penetrate soft tissues through open wounds and lacerations during trauma or by direct impact.¹ Such wounds harboring foreign bodies may appear to be deceptively minor and may not be accompanied by any major symptoms. However, if these foreign bodies are left undetected in the tissues they may result in serious sequels days, months or even years after the initial trauma. Although wooden foreign bodies are very common in the soft tissue and orbital trauma, pulmonary parenchymal foreign bodies are a rare cause of pulmonary disease and also a rare differential diagnosis of lung opacity on chest radiographs.¹⁻³ Only several cases of retained pulmonary foreign body have been reported in medical journals.^{2,3} The purpose of reporting this unusual case of recurrent pneumonia and hemoptysis caused by a retained wooden foreign body is to highlight the difficulties in the detection of foreign bodies and to discuss the different imaging appearances. We report a rare case of a pulmonary parenchymal wooden foreign body diagnosed 8 years after chest trauma. In our opinion, the wooden foreign body must be resected as soon as possible.

Case Report

A 32-year-old rural woman came to our hospital due to shortness of breath, cough, purulent sputum and hemoptysis.

She had a history of recurrent respiratory tract infection that was resolved with antibiotic therapy.

She had a remote history of chest trauma due to falling from a horse 8 years earlier. She had suddenly experienced severe chest discomfort and bleeding, but she was not referred to the hospital.

Physical examination at current admission showed finger clubbing and

¹ Assistant Professor, Department of Radiology, Urmia University of Medical Sciences, Urmia, Iran.

Corresponding Author:
Afshin Mohammadi
Address: Department of Radiology,
Imam Khomeini Hospital, Modaress St.,
Urmia, Iran.
Tel: +9844 1344 7113
Fax: +9844 1346 9935
Email: mohamadi_afshin@yahoo.com

Received December 7, 2008;
Accepted after revision March 9, 2009.

Iran J Radiol 2010;7(1):23-25

pulmonary crackle in the right upper hemithorax. A scar was found on the lateral aspect of the right chest wall.

The patient had normal laboratory data (CBC, BUN/Cr, AST, ALT, BC, PPD) except for an elevated ESR and a positive CRP.

She did not have previous CXR for comparison. The evaluation of the patient for tuberculosis and Wegener granulomatosis revealed negative results.

The obtained chest radiograph showed a pulmonary thick wall cavity with surrounding consolidation and a tubular density within the cavity such as a fungus ball (Fig. 1A).

A conventional thoracic CT scan (Toshiba; Xvision, Japan) without IV contrast obtained after admission showed thicked-wall cavity in the lung with pleural thickening and pulmonary consolidation in the adjacent lung parenchyma, which contained a dense tubular opacity (Fig. 1B-D).

This was interpreted as a calcified old hematoma in a post traumatic pulmonary pseudocyst (TPPC).

The patient had no clinical improvement after anti-biomatic therapy and exacerbation of hemoptysis was observed after one week treatment.

Segmentectomy and wedge resection of the posterior segment of the right upper lobe was performed. The excised specimen contained a tubular-shape piece of wood 7×2×1 cm (Fig. 2) which was enveloped in granulation tissue and fibrosis.

Discussion

Although aspiration of a wooden foreign body into the tracheo-bronchial tree is not uncommon,⁴ pulmonary parenchymal wooden foreign bodies are quite rare. Most parenchymal wooden foreign bodies are due to trauma and the diagnosis is made on the basis of history and physical examination at the time of presentation.¹

Despite advances in imaging techniques, the detection of retained wooden foreign bodies remains a difficult and challenging task.⁵ The detection of wood is

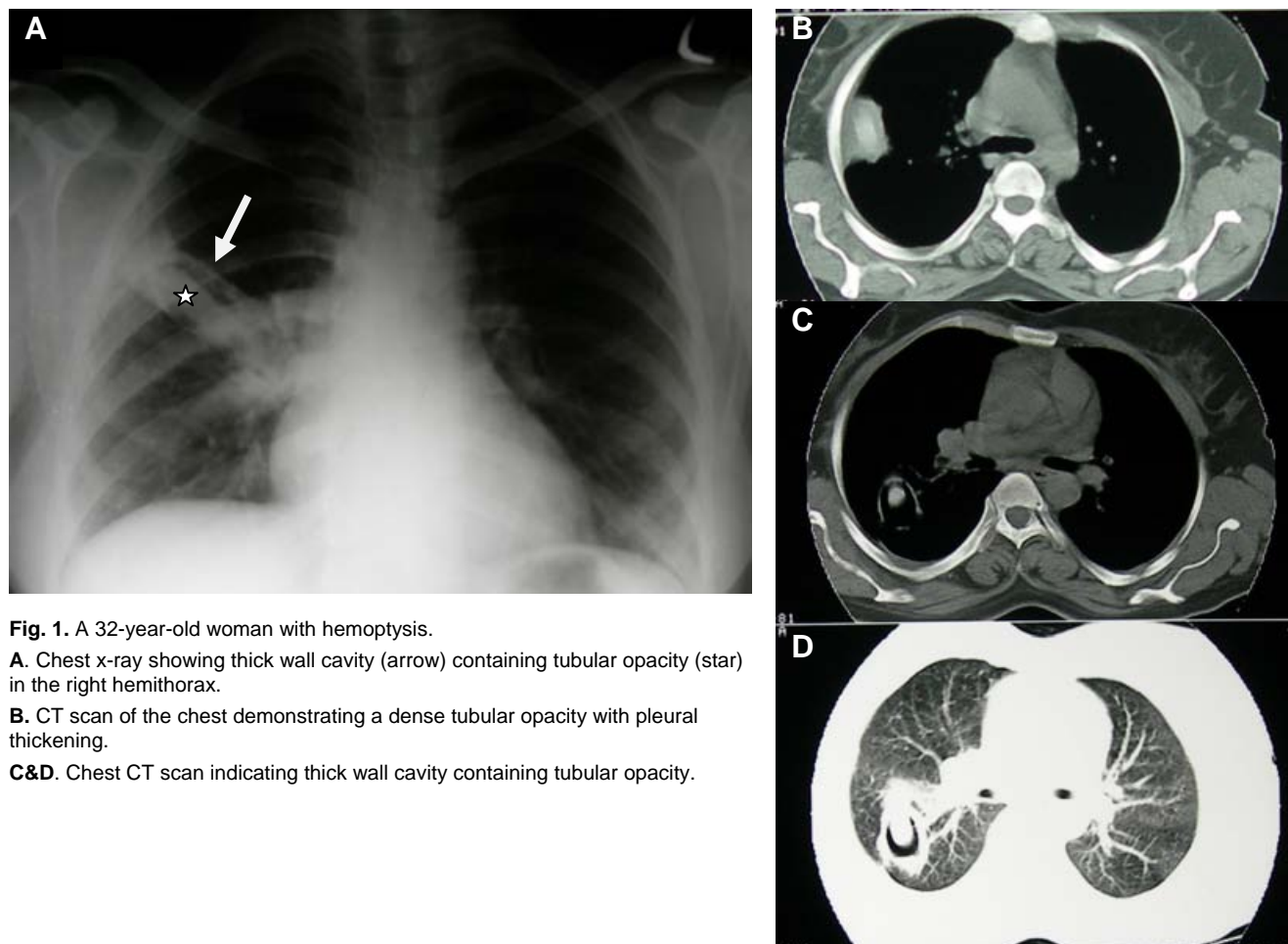


Fig. 1. A 32-year-old woman with hemoptysis.
A. Chest x-ray showing thick wall cavity (arrow) containing tubular opacity (star) in the right hemithorax.
B. CT scan of the chest demonstrating a dense tubular opacity with pleural thickening.
C&D. Chest CT scan indicating thick wall cavity containing tubular opacity.



Fig. 2. Photograph showing the piece of wood.

especially important because it may serve as an unrecognized nidus for infection. Wood is an excellent medium for micro organisms due to the porous consistency and organic nature it has. The retained wooden foreign body may result in abscess and fistula formation.⁶ The evaluation for tuberculosis and Wegener's granulomatosis was negative in this patient. The patient was unaware of the foreign body in her lung until the surgical resection of the pathology 8 years after the trauma. The injury most likely occurred while the patient accelerated down a slope lying supine on the ground and the apex of a wooden fragment implanted her chest. In the patient with recurrent unifocal pneumonia we should consider an underlying problem such as foreign body.

Wooden fragments are the largest proportion of retained foreign bodies after trauma to the human body.⁷

Radiographs have been reported to reveal wooden foreign body in only 15% of the patients.⁷ In our patient, the CXR retrospectively showed the foreign body in the pulmonary cavity.

Although the diagnosis was not made preoperatively in this patient, the CT scan showed that the abnormality had square margins and tubular appearance, which in retrospect suggests a foreign body.

CT has been proved to be useful in the evaluation of suspected wooden material. The attenuation of a retained wooden foreign body varies in relation to the content of air and fluid in the interstices of wood.

Within approximately one week, the wood absorbs blood products and exudates, and increases its attenuation.⁸ Dry wood with high air content has been re-

ported to mimic a gas collection.⁹

Bodne et al. cited three cases of wooden foreign bodies with various attenuation values, ranging from close to air in acute cases to high (near to calcium) in chronic cases.¹⁰ In our case the attenuation value of the wood particle was 190 HU which is a high density near to calcification. Traumatic pulmonary pseudocyst (TPPC) is a rare complication, sometimes encountered after thoracic trauma.¹¹ In our patient, we found that retained wooden foreign body may cause formation of traumatic pulmonary pseudocyst. In our opinion, pulmonary wooden foreign bodies must be operated as soon as possible because it would be a nidus for recurrent infection.

References

1. Al-Zahrani S, Kremli M, Saadeddin M, Ikram A, Takroni T, Zeidan H. Ultrasonography detection of radiolucent foreign bodies in soft tissue compared to computed tomography scan. *Ann Saudi Med.* 1995;15(2):110-2.
2. Tsang FH, Sihoe AD, Cheng LC. Unusual retained foreign body in the lung: a tree branch. *Eur J Cardiothorac Surg* 2007;31(2):309-10.
3. Nakata H, Egashira K, Nakamura K, Hayashi K, Mori M. Bamboo foreign bodies in lung parenchyma: CT features. *Clin Imaging* 1992 Apr-Jun;16(2):117-20.
4. Thomas V, Chandy G, Rolston DD. Foreign body in the lung for 45 years without symptoms. *Br J Dis Chest* 1986;80(3):292-4.
5. Peterson JJ, Bancroft LW, Kransdorf MJ. Wooden foreign bodies: imaging appearance. *AJR Am J Roentgenol* 2002;178(3):557-62.
6. Ochiai H, Yamakawa Y, Fukushima T, Yamada H. Neuroimaging of a wooden foreign body retained for 5 months in the temporalis muscle following penetrating trauma with a chopstick. *Neurol Med Chir* 1998;39(11):744-7.
7. Anderson MA, Newmeyer WL, Kilgore ES Jr. Diagnosis and treatment of retained foreign bodies in the hand. *Am J Surg* 1982;144(1):63-7.
8. Ginsberg LE, William DW 3rd, Mathews VP. CT in penetrating cranio cervical injury by wooden foreign bodies: reminder of a pitfall. *AJNR Am J Neuroradiol* 1993;14(4):892-5.
9. Ho VT, McGuckin JF Jr, Smergel EM. Intraorbital wooden foreign body: CT and MR appearance. *AJNR Am J Neuroradiol* 1996;17:134-6.
10. Bodne D, Quinn SF, Cochran CF. Imaging foreign glass and wooden bodies of the extremities with CT and MR. *J Comput Assist Tomogr* 1988;12(4):608-11.
11. Kocer B, Gulbahar G, Gunal N, Dural K, Sakinci U. Traumatic pulmonary pseudocysts: two case reports. *J Med Case reports* 2007 Oct 22;1:112.