

# Extranodal Diffuse Large B-Cell Lymphoma Confined to Liver in a Kidney Transplant Recipient

Khadijeh Makhdoomi,<sup>1</sup> Ali Ghaffari Moghaddam,<sup>1</sup> Ali Aishi Oskue,<sup>2</sup> Afshin Mohammadi,<sup>3</sup> Behrooz Ilkhanizadeh,<sup>4</sup> Ali Enshae,<sup>5</sup> Kamran Shateri,<sup>6</sup> Arefeh Esmaeli<sup>4</sup>

<sup>1</sup>Division of Nephrology, Department of Internal Medicine and Nephrourology and Transplant Research Center, Urmia University of Medical Sciences, Urmia, Iran

<sup>2</sup>Division of Hematology and Oncology, Department of Internal Medicine, Urmia University of Medical Sciences, Urmia, Iran

<sup>3</sup>Department of Radiology, Urmia University of Medical Sciences, Urmia, Iran

<sup>4</sup>Department of Pathology, Urmia University of Medical Sciences, Urmia, Iran

<sup>5</sup>Department of Surgery, Urmia University of Medical Sciences, Urmia, Iran

<sup>6</sup>Division of Gastroenterology, Department of Internal Medicine, Urmia University of Medical Sciences, Urmia, Iran

**Keywords.** kidney transplant, lymphoproliferative disorders, neoplasms

## INTRODUCTION

Lymphoproliferative disorders are among the most serious and potentially fatal complications of chronic immunosuppression in organ transplant recipients. The overall incidence of lymphoproliferative disease is approximately 1% per year, 30 to 50 times higher than in the general population, which is dependent on the type of transplantation, the corresponding immunosuppressive treatment, and Epstein-Barr virus (EBV) and cytomegalovirus serostatus at the time of transplantation.<sup>1</sup> Additional risk factors include recipient's age and ethnicity, history of pretransplant malignancy, and fewer human leukocyte antigens matches.<sup>2</sup> The prevalence of lymphoproliferative disorders after kidney

Posttransplant lymphoproliferative disorder (PTLD) is a well-documented complication that arises as a result of immunosuppression in the setting of solid organ or bone marrow transplantation. The disorder may be subtle and/or extranodal. We report a patient with extranodal lymphoma following kidney transplantation who had successful treatment with surgery and chemotherapy.

IJKD 2010;4:336-9  
www.ijkd.org

transplantation has been reported to be 1% to 2%.<sup>1,3</sup> The most common extranodal site is the gastrointestinal tract (stomach and ileocecal region), but virtually, any extranodal location (lungs, skin, liver, central nervous system, and the allograft itself) may be a primary site.<sup>4</sup> We report a patient with extranodal lymphoma following kidney transplantation who had successful treatment with surgery and chemotherapy.

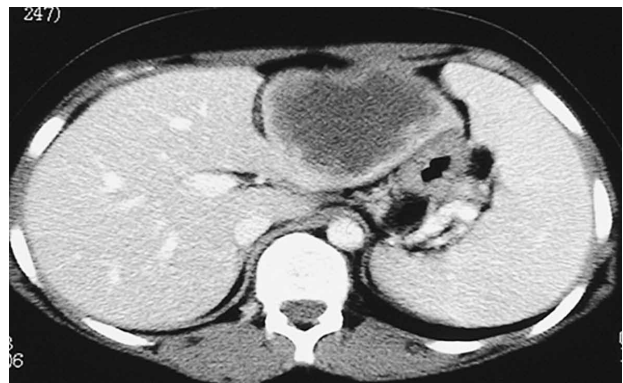## CASE REPORT

A 25-year-old woman with ESRD due to reflux nephropathy received a kidney transplant from a heart-beating female cadaveric donor and was discharged after 23 days without any immunologic or nonimmunologic complication.

Her serum creatinine level at discharge was 1.1 mg/dL. Her induction therapy was cyclosporine (Neoral, 6 mg/kg), mycophenolate mofetil (2 g/d), and prednisolone (1 mg/kg after 500 mg of methylprednisolone pulse for 3 days), and diltiazem (90 mg/d).

After 73 days, she returned with chicken pox and was treated with intravenous administration of acyclovir for 7 days. Ten months after transplantation, she was admitted with fever, epigastric pain, and anorexia. At this time, her medication consisted of cyclosporine (3.5 mg/kg), mycophenolate mofetil (2 g/d), and prednisolone (10 mg/d). Laboratory findings are shown in the Table. Upper gastrointestinal endoscopy showed chronic gastritis and pancolonoscopy detected no abnormal finding. Abdominal ultrasonography showed a hypoechoic well-defined solid mass without cystic component in the left lobe of the liver. The spleen had normal size and echogenicity. Spiral abdominal computed tomography with intravenous and oral contrast media (100 mL of iopromide, 300 mg/dL) revealed a well-defined hypodense solid mass (8 × 10 cm) in the left lobe of the liver without enhancement after contrast injection and without calcification (Figure 1).

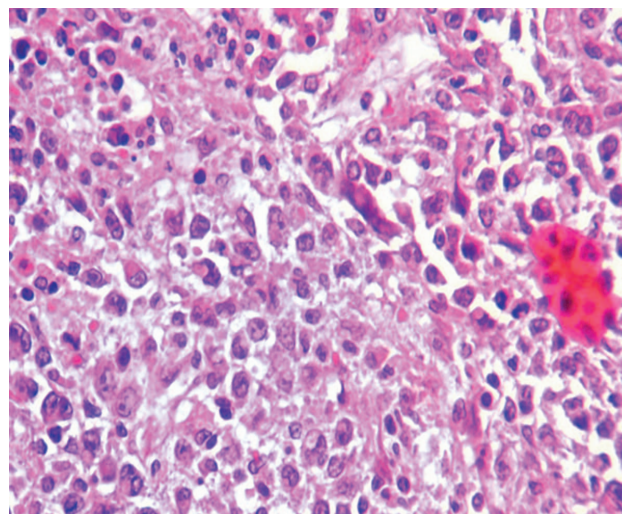
The patient underwent partial left liver lobe



**Figure 1.** Axial computed tomography showed a well-defined hypodense mass in the left lobe of the liver.

lobectomy. Macroscopic appearance of the lesion was an ill-defined creamy fleshy nodule, 7 cm in diameter, with central necrosis. Microscopic evaluation showed diffuse proliferation of large lymphoid cells with prominent eosinophilic nucleoli, occasional polylobated nuclei, and moderate mitosis (Figure 2). Immunohistochemistry showed strong positivity for CD20, 70% nuclear staining for Ki-67, and negativity for CD30 (Figure 3). The Ki-67 is a marker for proliferative activity, which was high in this case and CD30 negativity ruled out Reed-Steinberg-like polylobated nuclei.

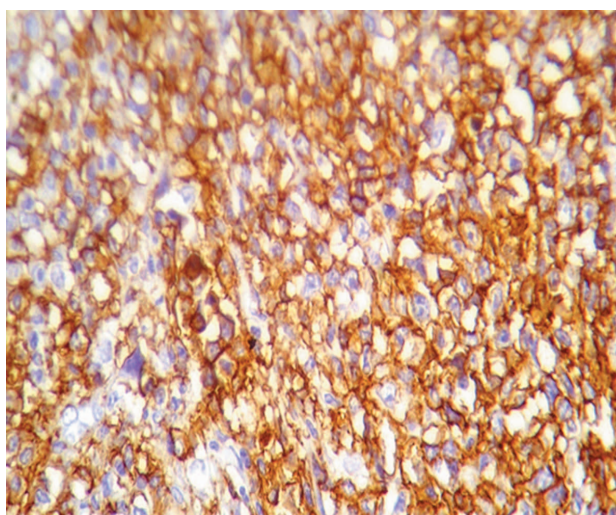
Cyclosporine and mycophenolate mofetil were discontinued because the patient was severely ill and feverish (body temperature, 39.3°C). According to the pathologic findings and because of CD20 positivity, she was started on 8 courses of chemotherapy every 21 days with ritoximab, 500 mg,



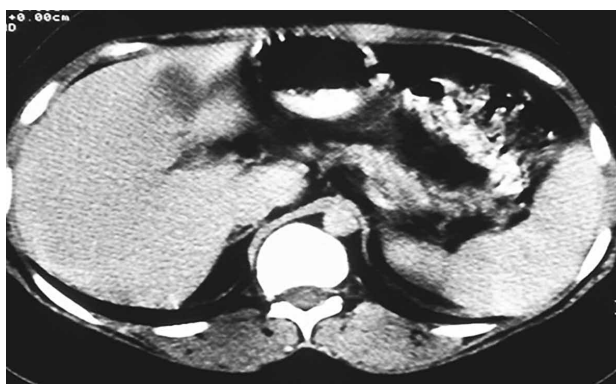**Figure 2.** Diffuse proliferation of large lymphoid cells with prominent eosinophilic nucleoli, occasional polylobated nuclei, and moderate mitosis

Laboratory Tests Results

Laboratory Test	Value
Hemoglobin, g/dL	9.8
Blood urea nitrogen, mg/dL	23
Serum creatinine, mg/dL	1.9
Serum alanine aminotransferase, IU/L	23
Serum aspartate aminotransferase, IU/L	20
Serum alkaline phosphatase, IU/L	274
Serum iron, µg/dL	80
TIBC, µg/dL	210
Serum ferritin, ng/dL	1700
Serum lactate dehydrogenase, IU/L	525
Erythrocyte sedimentation rate, mm/h	145
Protrombin time, sec	16
International normalized rate	1.5
Serum total bilirubin, mg/dL	0.51
Blood culture	Negative
Urine culture	<i>Enterobacter</i>
Serum protein electrophoresis	Negative
Cyclosporine trough level, ng/mL	145
Hepatitis C virus antibody	Negative
Hepatitis B surface antigen	Negative
Ebstein-Barr virus immunoglobulin G	Negative
Ebstein-Barr virus immunoglobulin M	Negative



**Figure 3.** Immunohistochemistry was positive for CD20, 70% nuclear staining for Ki-67, and negative for CD30.



**Figure 4.** Axial computed tomography 1 year after the end of chemotherapy (control).

cyclophosphamide, 1000 mg, hydroxy adriamycin, 80 mg, and oncovin, 2 mg, plus prednisolone, 100 mg/d, for 5 days (R-CHOP protocol). During and after chemotherapy, there were not any rises in serum creatinine level. Immunosuppressive therapy with sirolimus, 2 mg/d, and mycophenolate mofetil, 1.5 g/d, was started 2 months after all courses of chemotherapy were completed. Sixteen months after the last course of chemotherapy, she was in a good condition without any recurrences of lymphoma in the liver or any other organs (Figure 4), and her serum creatinine was 1.2 mg/dL.

## DISCUSSION

Lymphoproliferative disorders are the most common malignancies complicating organ transplantation (excluding nonmelanoma skin cancer), accounting for 21% versus 5% of all malignancies in the general population.<sup>5</sup> The

reported incidence of PTLD in the recipients of solid organ transplants ranges from 0.8% to 15% per year.<sup>5</sup> Some studies showed the overall incidence rates of 0.47% and 0.66% that were less than the other reports.<sup>7,8</sup> The time interval between transplantation to PTLD diagnosis varies (ranges from 1 to 145 months).<sup>9</sup> In our patient, the interval was less than 11 months.

The incidence rate of PTLD for EBV-seronegative recipients was 24 times higher than that for EBV-seropositive recipients. The EBV-positive PTLD tends to occur earlier than EBV-negative disease. The majority of cases occurring more than 5 years after transplant are EBV-negatives.<sup>5,9</sup> We did not have the donor EBV serology, but this case was seronegative, and it presented in less than 1 year with PTLD.

Non-Hodgkin lymphoma accounts for 65% of lymphomas in the general population, compared to 93% in transplant recipients. These tumors are mostly large-cell lymphomas, the great majority of which are of the B-cell type and are CD20 positive.<sup>5,10</sup> Diffuse large B-cell lymphoma (DLBCL) is a neoplasm of large B lymphoid cells. Morphological, biological, and clinical studies have subdivided DLBCL into subgroups and distinct entities; DLBCL may present with nodal or extranodal disease with up to 40% being at least initially confined to extranodal sites.<sup>11</sup>

Treatment of PTLD may require reduction of immunosuppression, radiation, surgical excision, monoclonal antibodies, interferon-alfa, and chemotherapy. The CHOP protocol is still the first choice for the treatment of patients with DLBCL.<sup>12</sup> Rituximab is a chimeric anti-CD20 antibody, which has been used to treat PTLD with variable success. Although reduction in immunosuppressive medications remains the first-line therapy for PTLD treatment, it is reasonable to begin active treatment with rituximab and/or chemotherapy, especially in CD20-positive patients, like this case, along with reduction in immunosuppression. Recent results have shown benefits in the association of the CHOP protocol and anti-CD20 monoclonal antibodies (rituximab), but the use of these drugs makes the treatment of patients with DLBCL rather more expensive.<sup>13-17</sup> Further prospective comparative studies are needed to confirm the efficacy of these treatment strategies as well as to clarify which subset of patients may benefit most from them.



**CONFLICT OF INTEREST**

None declared.

**REFERENCES**

1. Swinnen LJ, Swerdlow SH. Diagnosis and management of posttransplant and other iatrogenic immune deficiency lymphoproliferative disorders. In: Mauch PM, Armitage JO, Coiffie BR, Dalla-Favera R, Harris NL, editors. *Non-Hodgkin's lymphomas*. Philadelphia: Lippincott Williams & Wilkins; 2004. p. 629-39.
2. Caillard S, Lelong C, Pessione F, Moulin B. Post-transplant lymphoproliferative disorders occurring after renal transplantation in adults: report of 230 cases from the French Registry. *Am J Transplant*. 2006;6:2735-42.
3. Harris NL, Swerdlow SH, Frizzera G, Knowles DM. Post-transplant lymphoproliferative disorders. In: Jaffe ES, Harris NL, Stein H, Vardiman JW, editors. *World Health Organization classification of tumours: pathology and genetics of tumours of haematopoietic and lymphoid tissues*. Lyon, France: IARC Press; 2001. p. 264-9.
4. Kasiske BL, Vazquez MA, Harmon WE, et al. Recommendations for the outpatient surveillance of renal transplant recipients. *American Society of Transplantation. J Am Soc Nephrol*. 2000;11 Suppl 15:S1-86.
5. Penn I. Cancers complicating organ transplantation. *N Engl J Med*. 1990;323:1767-9.
6. Danovitch GM, editor. *Handbook of kidney transplantation*. 5th ed. Philadelphia: Wolters Kluwer/Lippincott Williams & Wilkins; 2010. p. 231-3.
7. Einollahi B, Lessan-Pezeshki M, Nourbala MH, et al. Posttransplant lymphoproliferative disorders in kidney transplant recipients: an Iranian multicenter experience. *Iran J Kidney Dis*. 2008;2:227-33.
8. Saadat A, Einollahi B, Ahmadzad-Asl MA, et al. Posttransplantation lymphoproliferative disorders in renal transplant recipients: report of over 20 years of experience. *Transplant Proc*. 2007;39:1071-3.
9. Chia SC, Chau YP, Tan YM. Late-onset post-transplant lymphoproliferative disease presenting as massive occult gastrointestinal haemorrhage. *Singapore Med J*. 2008;49:117-20.
10. Caillard S, Agodoa LY, Bohem EM, Abbott KC. Myeloma, Hodgkin disease, and lymphoid leukemia after renal transplantation: characteristics, risk factors and prognosis. *Transplantation*. 2006;81:888-95.
11. Stein H, Warnke RA, Chan WC, et al. *WHO classification of tumors of hematopoietic and lymphoid tissue*. 4th ed. WHO press; 2008. p. 233-7.
12. Everly MJ, Bloom RD, Tsai DE, Trofe J. Posttransplant lymphoproliferative disorder. *Ann Pharmacother*. 2007;41:1850-8.
13. Verschuuren EA, Stevens SJ, van Imhoff GW, et al. Treatment of posttransplant lymphoproliferative disease with rituximab: the remission, the relapse, and the complication. *Transplantation*. 2002;73:100-4.
14. Piro LD, White CA, Grillo-Lopez AJ, et al. Extended Rituximab (anti-CD20 monoclonal antibody) therapy for relapsed or refractory low-grade or follicular non-Hodgkin's lymphoma. *Ann Oncol*. 1999;10:655-61.
15. Jain AB, Marcos A, Pokharna R, et al. Rituximab (chimeric anti-CD20 antibody) for posttransplant lymphoproliferative disorder after solid organ transplantation in adults: long-term experience from a single center. *Transplantation*. 2005;80:1692-8.
16. Lee JJ, Lam MS, Rosenberg A. Role of chemotherapy and rituximab for treatment of posttransplant lymphoproliferative disorder in solid organ transplantation. *Ann Pharmacother*. 2007;41:1648-59.
17. Elstrom RL, Andreadis C, Aqui NA, et al. Treatment of PTLN with rituximab or chemotherapy. *Am J Transplant*. 2006;6:569-76.

Correspondence to:  
Khadijeh Makhdoomi, MD  
Department of Internal Medicine, Urmia University of Medical Sciences, Urmia, Iran  
E-mail: makhdoomikh@yahoo.com

Received November 2009

Revised May 2010

Accepted July 2010