



Radial Artery Pseudoaneurysm at the Previous Site of Invasive Monitoring

Ahmadreza Afshar, MD^{1*}, Babak Nasiri, MD²

¹Shahid Motahhari Hospital, Urmia University of Medical Sciences, Iran.

²Shahid Madani Hospital, Tabriz University of Medical Sciences, Iran.

Received 3 March 2008; Accepted 18 October 2008

Abstract

This report presents a case of left radial artery pseudoaneurysm developing at the previous site of invasive monitoring. The patient had prosthetic mitral valve replacement one month earlier, and anti-coagulation therapy had started on the first post-operative day. The patient's radial artery aneurysm with a 4-centimeter diameter was resected and the radial artery was ligated.

J Teh Univ Heart Ctr 3 (2009) 193-196

Keywords: Aneurysm, false • Mitral valve • Radial artery

Introduction

Arterial line access is utilized to manage critically ill patients for real-time hemodynamical monitoring and frequent blood samples. The radial artery is the most frequently used arterial line access with relative safety; be that as it may, complications are liable to occur.¹⁻³ Pseudoaneurysm is a rare complication, and there are reports that pseudoaneurysm develops in the setting of the arterial line infection.⁴⁻⁸ Other complications include rupture with bleeding,⁸ dissection,⁸ thrombosis,^{1,8} hematoma,^{1,7} distal embolization, hand ischemia,^{1,8} local infection,^{3,5,7} and bactremia.⁵

This report presents a case of radial artery pseudoaneurysm developing at the previous site of invasive monitoring. The patient was receiving anticoagulation therapy.

Case report

A 48-year-old man underwent prosthetic mitral valve replacement because of the mal-function of the previous prosthetic mitral valve. The first surgery had been performed

two years previously. His left radial artery was used for invasive monitoring for 72 hours. Oral anticoagulation (warfarin) was commenced 24 hours post-operatively. The patient had an otherwise uncomplicated hospital course.

One month after the surgery, however, a round pulsating aneurysm at the line of the left radial artery was discovered and it continued to expand (Figure 1). A thrill was palpable over the swelling. The radial pulse was palpable. There was no pain and tenderness over the swelling. The thumb and index finger had normal capillary filling. Allen's test indicated that the circulation of the hand depended on the ulnar artery. There was no sign of local infection such as erythema, edema, and purulent discharge. The anesthetic records of the patient did not disclose any information about the details of the gaining access to the radial artery.

Angiography showed an aneurysmal distention of the left radial artery at the distal forearm, and the distal track of the radial artery was occluded. The ulnar artery was patent (Figure 2).

Under local anesthesia, the aneurysm, which was 4 centimeters in diameter, was resected and the radial artery was ligated (Figure 3). The cultures of the aneurysm were

*Corresponding Author: Ahmadreza Afshar, Associate Professor of Orthopedic Surgery, Department of Orthopedics, Shahid Motahhari Hospital, Kashani Street, Urmia, Iran. Tel: +98 912 3131556. Fax: +98 44 12234125. Email: afshar@umsu.ac.ir

negative.

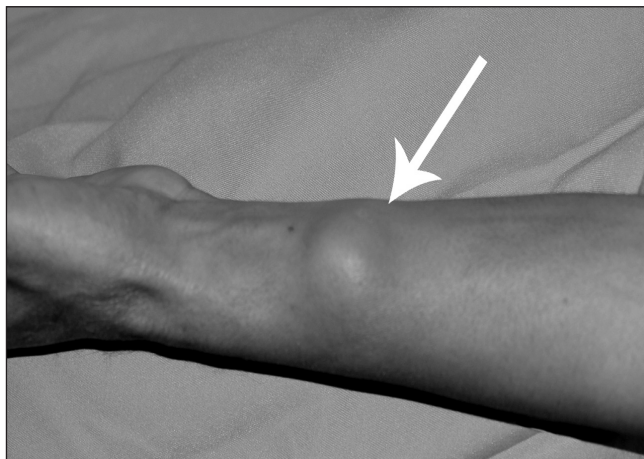

Figure 1. The swollen area due to aneurysm of the left radial artery (arrow)

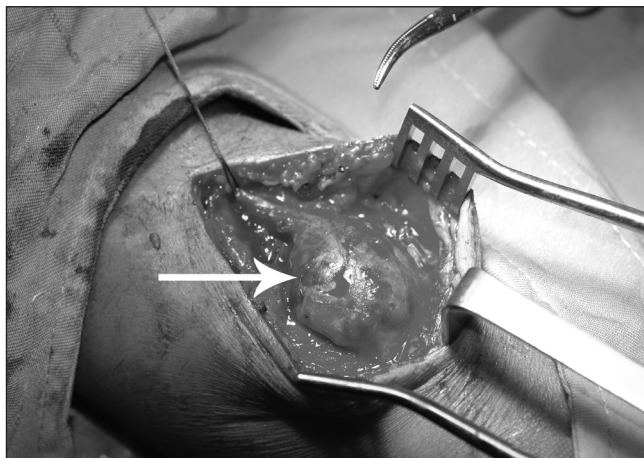


Figure 2. Angiography showing the aneurysm and occlusion of the distal track of the radial artery (arrow)

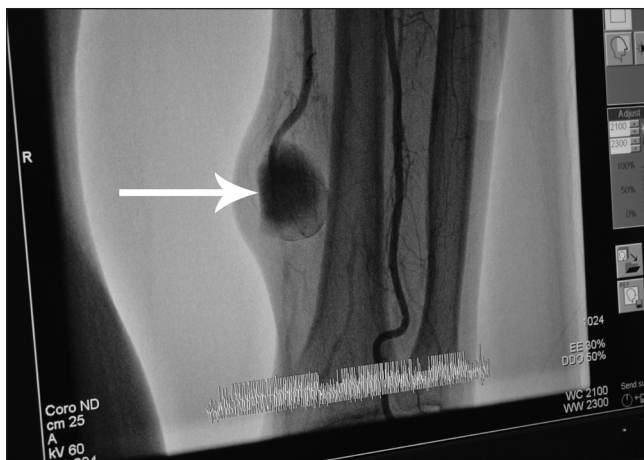

Figure 3. The aneurysm at the site of operation (arrow)

Discussion

Pseudoaneurysm is an accumulation of blood in continuity with arterial circulation unenclosed by the all three layers of the arterial wall. Usually after the removal of the catheter, hemostasis seals the hole in the arterial wall and the arterial wall repairs itself. If hemostasis is compromised, the blood dissects into the surrounding soft tissues and a pseudoaneurysm may develop.⁵

Known risk factors to the development of pseudoaneurysm are abnormal state of the vessel wall (atherosclerosis), multiple attempts at cannulation, hematoma formation, and infection at the cannulation site.^{4,6,7} Infection lasting more than 48 hours and infection with the bacterium *S. Aureus* correlate strongly with pseudoaneurysm formation.

S. Aureus may express certain enzymes such as hyaluronidase, which in combination with local inflammatory response results in enhanced arterial wall degeneration.⁵

There are reports of ischemic complications following the radial artery cannulation, ranging from mild ischemia following embolization to severe ischemia and gangrene requiring amputation.⁷ The incidence of complications increases with increasing duration of cannulation.¹

Rupture with bleeding is one of the most morbid complications of pseudoaneurysm.⁷

Most surgeons prefer to ligate the radial artery if there is back bleeding from the distal stump and there is no ischemic consequences to the hand.^{4,5,7,8} Alternatives include direct repair if the defect is small, repair with an intercalary vein graft for the larger defects,⁵ and resection of the aneurysm and reconstruction by end-to-end anastomosis.⁶ Local infection makes repair of any kind suboptimal.⁵

In the case presented herein, although angiography showed the occlusion of the distal track of the radial artery, the patient had palpable distal radial pulse. This may be described as the distal radial pulse being transmitted via the ulnar artery and palmar arch.^{1,7}

In a majority of reports, radial artery pseudoaneurysms were accompanied with the arterial line infections, especially *S. Aureus* bacterium and the hemostasis mechanism was compromised by infection.^{5,7}

Our patient had no signs of infection. The radial artery was not reconstructed because of the occluded distal segment of the artery. The development of an aneurysm in this patient may be explained by probable multiple attempts to cannulate the artery and subsequent blood leakage. Anti-coagulation therapy was an added risk factor to the hematoma formation and subsequent development of the aneurysm.

References

1. Bedford RF, Wollman H. Complications of percutaneous radial artery cannulation. *Anesthesiology* 1973;38:228-236.
2. Downs JB, Rakestein AD, Klein EF, Hawkins IF. Hazards of the



- radial-artery catheterization. *Anesthesiology* 1973;38:283-286.
3. Slogoff S, Keats AS, Arlund C. On the safety of the radial artery cannulation. *Anesthesiology* 1983;59:42-47.
 4. Christodoulou C, Guzman R. Radial artery pseudoaneurysm. *Acta Anaesthesiol Scand* 2004;48:796-797.
 5. Ganchi PA, Wilhelmi BJ, Fujita K, Lee WPA. Ruptured pseudoaneurysm complicating an infected radial artery catheter: case report and review of the literature. *Ann Plast Surg* 2001;46:647-650.
 6. Mathieu A, Dalton B, Fischer JE, Kumar A. Expanding aneurysm of the radial artery after frequent puncture. *Anesthesiology* 1973;38:401-403.
 7. McEllistrem RF, O'Tode DP, Keane P. Post-cannulation radial artery aneurysm: a rare complication. *Can J Anaesth* 1990;37:907-909.
 8. Wolf S, Mangano DT. Pseudoaneurysm, a late complication of radial artery catheterization. *Anesthesiology* 1980;52:80-81.

