

See discussions, stats, and author profiles for this publication at: <https://www.researchgate.net/publication/6235926>

Primary endobronchial actinomycosis simulating endobronchial tuberculosis in a patient with diabetes mellitus

Article in *Tuberkuloz ve toraks* · February 2007

Source: PubMed

CITATIONS

6

READS

23

2 authors, including:



[Mohammad Hossein Rahimi-Rad](#)

Urmia University

34 PUBLICATIONS 116 CITATIONS

SEE PROFILE

Some of the authors of this publication are also working on these related projects:



Asthma [View project](#)

Primary endobronchial actinomycosis simulating endobronchial tuberculosis in a patient with diabetes mellitus

Mohammad Hossein Rahimi RAD, Majid MILANI

Department of Pulmonary Disease, Urmia University of Medical Sciences, Urmia, West Azerbaijan, Iran.

ÖZET

Diabetes mellitusu olan hastada endobronşiyal tüberkülozu taklit eden primer endobronşiyal aktinomikozis

Primer endobronşiyal aktinomikozis nadirdir ve yabancı cisim aspirasyonu olmaksızın son derece beklenmedik bir durumdur. Yetmiş yaşında sigara içmeyen kadın hasta hemoptizi ve iki aydır kilo kaybı yakınmalarıyla başvurdu. Bilgisayarlı tomografide hiler kitle olması nedeniyle bronş kanseri ön tanısıyla fiberoptik bronkoskopi yapıldı. Sol üst lob bronşunda vejetasyon saptandı. Biyopsi örneğinin histolojik incelemesi aktinomiçes infeksiyonu olduğunu gösterdi. Hasta penisilin tedavisine yanıt verdi ve akciğer grafişi dört ayda tamamen düzeldi. Yabancı cisim varlığı olmaksızın diabetes mellitusla endobronşiyal aktinomikozis birlikteliği daha önce bildirilmemiştir ve endobronşiyal tüberküloz veya kanserde endobronşiyal vejetasyonların ayırıcı tanısına dahil edilmelidir.

Anahtar Kelimeler: Aktinomikozis, pulmoner, sülfür granülleri, endobronşiyal tüberküloz, diabetes mellitus.

SUMMARY

Primary endobronchial actinomycosis simulating endobronchial tuberculosis in a patient with diabetes mellitus

Mohammad Hossein Rahimi RAD, Majid MILANI

Department of Pulmonary Disease, Urmia University of Medical Sciences, Urmia, West Azerbaijan, Iran.

Yazışma Adresi (Address for Correspondence):

Mohammad Hossein Rahimi RAD, MD, Bronchoscopy Unit, Imam-khomeini Hospital, Urmia, West Azerbaijan, Iran 81351 URMIA - IRAN

e-mail: mohamadrahimirad@gmail.com

Primary endobronchial actinomycosis is rare and very uncommon without foreign body aspiration. A 70-years old nonsmoker diabetic woman was presented with hemoptysis and weight loss for two months. Fiberoptic bronchoscopy was performed because of hilar mass on her computerized tomography scan, with a presumptive diagnosis of bronchial carcinoma. It demonstrated vegetations in left upper lobe bronchus. Histologic examination of the biopsy specimen demonstrated Actinomyces infection. The patient responded well to penicillin therapy and chest X-ray completely cleared in four months. To our knowledge, the association of endobronchial actinomycosis with diabetes mellitus without presence of a foreign body has not been reported previously, and should be included in differential diagnosis with endobronchial tuberculosis or cancer in endobronchial vegetations.

Key Words: Actinomycosis, pulmonary, sulfur granules, endobronchial, tuberculosis, diabetes mellitus.

Pulmonary actinomycosis is a rare but important and challenging diagnosis to make. Even when the clinical suspicion is high, the disease is commonly confused with other chronic suppurative lung diseases and with malignancy (1). Twenty percent of cases of actinomycosis are located in the thorax. Primary endobronchial actinomycosis (EBA) is rare and very uncommon in association with foreign body aspiration (2). To our knowledge, there is no previous report of EBA in a diabetic patient without aspiration of foreign material. We present a case of primary EBA in a patient with diabetes mellitus.

CASE REPORT

A 70-years old nonsmoker woman was presented to our clinic with hemoptysis, anorexia, and weight loss for two months. She had history of diabetes mellitus for two years without history of loss of consciousness, convulsion in past, and alcohol or drug abuse. There was no history of recurrent infection or other evidence of immunodeficiency. On physical examination, heart rate was 60 beats/min, blood pressure 130/60 mmHg and temperature 36.5°C, and the dental hygiene were bad. Lung auscultation revealed diminished breath sounds with crackles and wheezing at the left upper lobe. Sputum was reported negative for acid fast bacilli three times. Chest X-ray and computerized tomography scan of the patient showed a mass at left hilum with infiltration in left upper lobe (Figure 1,2). A bronchoscopy was planned with a presumptive diagnosis of bronchogenic carcinoma or tuberculosis. It showed several vegetations in

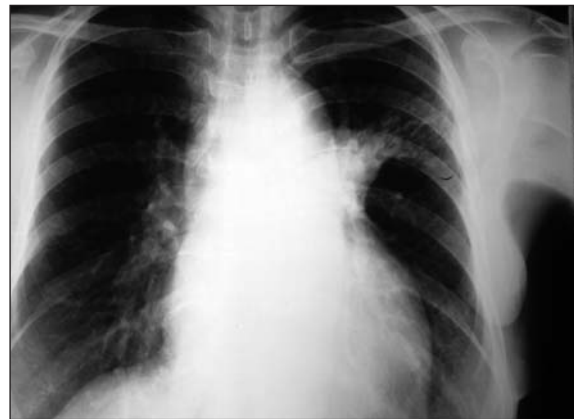

Figure 1. Plain chest X-ray shows left hilar mass like lesion with left upper lobe infiltrate mimicking tuberculosis.

the left upper bronchus with severely inflamed and edematous bronchial mucosa. At biopsy, they were firm material, profuse bleeding occurred. There was no foreign body. Before receiving the final pathologic report, chemotherapy for suspected endobronchial tuberculosis was instituted. Sputum and bronchoalveolar lavage smears reported negative for acid fast bacilli. Histologic slide stained with Hematoxylin and Eosin shows several sulfur granules containing eosinophilic clubbing on their peripheral portion (Figure 3).

After becoming aware of the etiology we stopped anti-tuberculosis therapy after taking it for two weeks. Penicillin G (4 million units q.i.d.) was initiated. She was discharged with oral penicillin V. Hemoptysis, anorexia resolved, and chest X-ray cleared gradually in the follow-up visits.

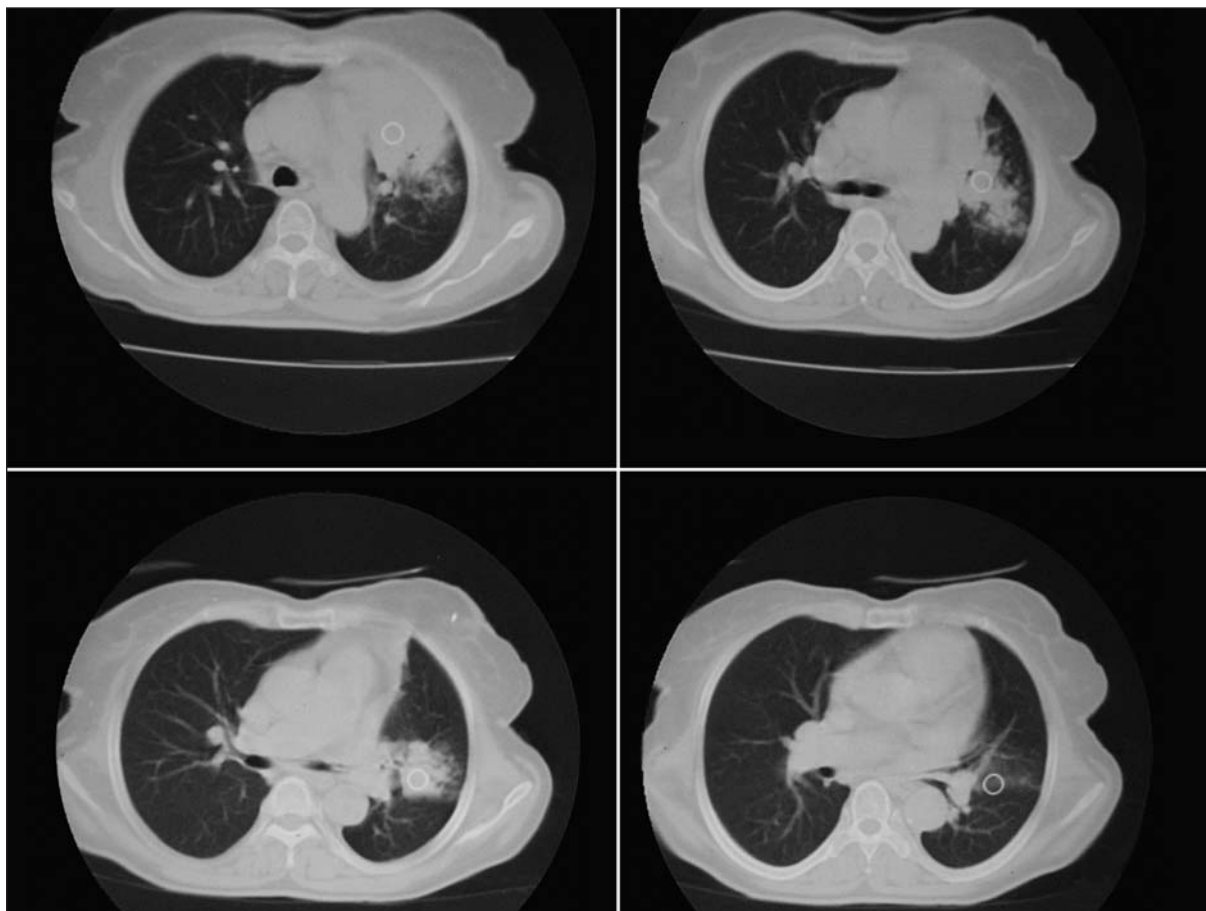


Figure 2. Chest computerized tomography scans show left hilar mass like lesion with left upper lobe infiltrate.

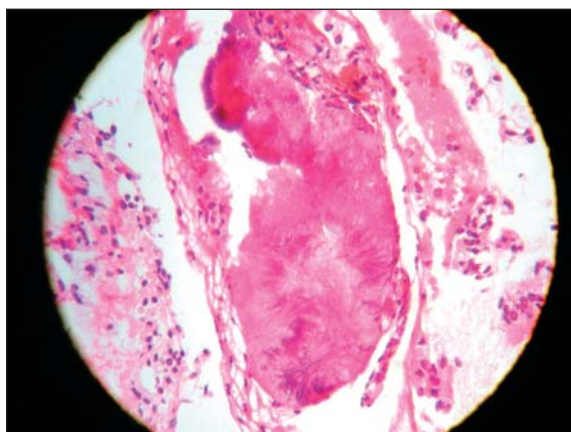


Figure 3. Photomicrograph (original magnification, x400; HE stain) shows sulfur granules surrounded by eosinophilic "clubbing" materials; this finding is typical for actinomycosis.

DISCUSSION

Actinomycosis is an infectious disease which is caused by the *Actinomyces*. These organisms are gram-positive and non-spore forming strict or facultative anaerobic rods. The organisms are not highly virulent and are found normally in the human oropharynx, particularly in persons with poor oral hygiene (3).

There are some case reports of endobronchial actinomycosis. In most reports, endobronchial foreign bodies predisposed to endobronchial actinomycosis (2,4-9). Chouabe et al. reported four cases of EBA associated with foreign bodies (2). Miracco et al. reported a patient, who had required transient intubation six months earlier, presented with a large mass, containing microscopic foci, vegetable cells, and sulfur granules, occluding the right middle lobe bronchus without parenchymal involvement (10). In two of the ca-

ses, endobronchial lesions resulted from extension of intrapulmonary diseases (11,12). Another case, evaluating unresolved pneumonia, led to the diagnosis of endobronchial lipoma with superimposed actinomycosis (13). But in present case, endobronchial entry of *Actinomyces* organisms was not accompanied foreign bodies.

Another important point in EBA is the simulating condition of endobronchial involving lesion. Common causes of endobronchial obstruction are bronchogenic carcinomas, bronchial benign tumors, and endobronchial tuberculosis. Ariel et al. reported five cases of EBA simulating bronchogenic carcinoma (14). Endobronchial tuberculosis, especially, is a common cause of endobronchial obstructive lesion in non-developed world. Lee et al. reported EBA simulating endobronchial tuberculosis in a 70 years old man (15). In endobronchial tuberculosis, typical bronchoscopic finding is the presence of white gelatinous granulation tissue. The mucosa is nodular, red, vascular and some times ulcerated. It may simulate a bronchogenic carcinoma (16).

So we thought the lesions were consistent with endobronchial tuberculosis. Rationales for starting empirical anti-tuberculosis therapy were:

1. The patient's symptoms such as hemoptysis, weight loss,
2. Diabetes mellitus is a risk factor for tuberculosis,
3. Involvement of left upper lobe is common finding in tuberculosis,
4. Endobronchial tuberculosis is highly contagious.

Definite diagnosis of pulmonary actinomycosis is usually based on demonstration of the typical filamentous microorganisms on tissue specimen (1,6,10,14). Culture is usually negative in endobronchial actinomycosis, as the microorganism is strictly anaerobic, and is frequently associated with non-aerobic contaminants. Nevertheless, since the organisms are part of the normal respiratory flora, a positive sputum culture is of little significance. The presence of sulfur granules in sputum is suggestive of diagno-

sis, but they are seldom found. We diagnosed *Actinomyces* on bronchial biopsy. The hallmark of actinomycosis is the presence of sulfur granules, but diagnosis is sometimes difficult in small and crushed biopsy samples. In one previous report, the diagnosis of EBA was done with a Wang needle aspiration of the mass when forceps biopsy was nondiagnostic (17).

Bronchoscopy is still a useful investigation however, particularly in excluding lung malignancy. EBA may manifest as irregular granular thickening and partial occlusion of bronchi, which resembles submucosal tumour, yet may only demonstrate nonspecific chronic inflammation histologically. It may also be florid disease, showing an exophytic mass with a purulent exudates and characteristic histology with sulfur granules.

In conclusion, there are two important distinguishing features of our case. The first is the endobronchial presentation of the case, which is a very rare form of the disease, with a diagnosis by bronchoscopic biopsy. The second is primary EBA presenting in a diabetic patient without foreign body, which has not been reported previously. Once the diagnosis is definite in EBA, the prognosis of the disease is excellent with antibiotic therapy. Primary EBA must be considered in the differential diagnosis of an endobronchial lesion, especially endobronchial tuberculosis in non-developed countries.

REFERENCES

1. Mabeza GF, Macfarlane J. Pulmonary actinomycosis. *Eur Respir J* 2003; 21: 545-51.
2. Chouabe S, Perdu D, Deslee G, et al. Endobronchial actinomycosis associated with foreign body: Four cases and a review of the literature. *Chest* 2002; 121: 2069-72.
3. Dicipinigaitis PV, Bleiweiss IJ, Krellenstein DJ, et al. Primary endobronchial actinomycosis in association with foreign body aspiration. *Chest* 1992; 101: 283-5.
4. Kim YS, Suh JH, Kwak SM, et al. Foreign body-induced actinomycosis mimicking bronchogenic carcinoma. *Korean J Intern Med* 2002; 17: 207-10.
5. Ho JC, Ooi GC, Lam WK, et al. Endobronchial actinomycosis associated with a foreign body. *Respirology* 2000; 5: 293-6.

6. Dalhoff K, Wallner S, Finck C, et al. Endobronchial actinomycosis. *Eur Respir J* 1994; 7: 1189-91.
7. Julia G, Rodriguez de Castro F, Caminero J, et al. Endobronchial actinomycosis associated with a foreign body. *Respiration* 1991; 58: 229-30.
8. Uzun O, Yildiz L, Findik S, Erkan L. Primary endobronchial actinomycosis simulating bronchial carcinoma in a patient with stroke. *Turkish Respiratory Journal* 2006; 7: 28-30.
9. Ocal Z, Ozdogan S, Caglayan B, et al. Endobronchial actinomycosis caused by occult foreign body aspiration. *Ann Saudi Med* 2004; 24: 210-2.
10. Miracco C, Marino M, Lio R, et al. Primary endobronchial actinomycosis. *Eur Respir J* 1988; 1: 670-1.
11. Lee M, Berger HW, Fernandez NA, Tawney S. Endobronchial actinomycosis. *Mt Sinai J Med* 1982; 49: 136-9.
12. Broquetas J, Aran X, Moreno A. Pulmonary actinomycosis with endobronchial involvement. *Eur J Clin Microbiol* 1985; 4: 508.
13. Arber N, Breuer R, Berkman N, et al. Unresolved pneumonia due to endobronchial lipoma and actinomycosis. *Eur Respir J* 1989; 2: 794-6.
14. Ariel I, Breuer R, Kamal NS, et al. Endobronchial actinomycosis simulating bronchogenic carcinoma. Diagnosis by bronchial biopsy. *Chest* 1991; 99: 493-5.
15. Lee SH, Shim JJ, Kang EY, et al. Endobronchial actinomycosis simulating endobronchial tuberculosis: A case report. *J Korean Med Sci* 1999; 14: 315-8.
16. Kashyap S, Mohapatra PR, Saini V. Endobronchial tuberculosis. *Indian J Chest Dis Allied Sci* 2003; 45: 247-56.
17. Bakhtawar I, Schaefer RF, Salian N. Utility of Wang needle aspiration in the diagnosis of actinomycosis. *Chest* 2001; 119: 1966-8.