
Case Report

Divergent Dislocation of The Elbow in An 11-Year-Old Child

Ahmadreza Afshar MD*

In this report divergent dislocation of the elbow in an 11-year-old boy and its outcome is presented. His right upper limb was trapped in a water irrigation machine and sustained an extreme pronation thrust through the hyperextended elbow. He had also suffered from a segmental fracture of both bones of the forearm and a fracture of the humerus. The median and ulnar nerves were functionless at his presentation. Considering the 16 cases described in the literature, different types of divergent dislocation of the elbow and the plausible mechanisms in producing this type of injury are reviewed.

Archives of Iranian Medicine, Volume 10, Number 3, 2007: 413 – 416.

Keywords: Elbow • dislocation • divergent dislocation • radial head

Introduction

In divergent dislocation of the elbow not only the elbow is dislocated, but also the connections between the proximal radius and ulna are disrupted. Delee is credited for the first radiologically verified case of transverse dislocation of the elbow in a six-year-old patient.¹ This very rare injury occurs predominantly in children. The author could find only 16 cases in the English literature describing the lesion in children.²⁻¹² There are varying views about the etiology and classification of this injury. In this report a case of divergent dislocation of the elbow and its outcome is presented.

Case Report

The patient was an 11-year-old boy whose right upper limb was trapped in the belt of a water irrigation machine. His limb sustained an extreme pronation thrust through the hyperextended elbow. On physical examination, the patient had a

swollen, widened elbow, and deformed forearm. Crepitus was noted in his arm, indicating that the humerus was also fractured. There was no vascular insufficiency, but the median and ulnar nerves were functionless. There was no laceration but there were skin abrasions on his forearm and arm. The radial head was palpable lateral to the distal humerus. Plain radiograph revealed a segmental fracture of both bones of the forearm, a medio-lateral (transverse) divergent elbow dislocation (Figure 1), and a fracture of the humerus (Figure 2). The radial head was lodged lateral and the olecranon was displaced posteromedial in relation to the distal humerus. The patient was taken to the operating theater and the humerus and the forearm fractures were fixed with open reduction and internal fixation using plates and screws. Then the elbow dislocation was addressed. The ulnohumeral and the radiohumeral joints were reduced easily with traction and then the radioulnar joint was reduced with squeezing the bones together. The limb was immobilized in a long arm slab, elbow in 90 degree flexion, and the forearm in supination. The slab was removed after three weeks, and physical therapy was then started. After three months the median and ulnar nerves recovered completely, indicating that their lesions were neuropraxia. After a one-year follow-up, the forearm rotation was limited to 20 degrees supination and 10 degrees pronation. The elbow's range of motion was from 30 to 120 degrees

Authors' affiliation: *Department of Orthopedics, Shaheed Motahhari Hospital, Urmia University of Medical Sciences, Urmia, Iran.

Corresponding author and reprints: Ahmadreza Afshar MD, Department of Orthopedics, Shaheed Motahhari Hospital, Kashani St., Urmia, Iran.

Tel: +98-912-313-1556, Fax: +98-441-223-4125,

E-mail: afshar@umsu.ac.ir.

Accepted for publication: 4 October 2006




Figure 1. Anteroposterior and lateral views of the right elbow and forearm showing mediolateral divergent dislocation of the elbow and segmental fracture of the both bones of the forearm.

flexion. It seems that further follow-up will not change the clinical picture of the patient.

Discussion

Divergent dislocation of the elbow is a rare subtype of elbow dislocation, which includes not only the disruption of all three joints comprising the elbow; the radiohumeral, ulnohumeral, and proximal radioulnar joints,⁶ but also there must be a lesion to the annular ligament and the interosseous membrane of the forearm.³ The injury predominantly occurs in children after a trauma.²⁻¹² Natural joint laxity is a predisposing factor in producing this type of injury in children.²

This injury has been classically classified into two types: the anteroposterior, and the mediolateral or transverse dislocations.¹⁰ Altuntas et al believe that there is only one type of divergent dislocation of the elbow, which is a posterior divergent dislocation.² This difference of opinion about the

classification derives from the fact that radiologic evaluation is difficult and standard anteroposterior or lateral view radiographs may not be fully informative in evaluating the injury. Studies on cadavers have tried to simulate the injury and its radiographic presentation, but with various results.^{2,12}

The mechanism producing this injury is still unsettled. It has been speculated that a strong proximally directed force is applied parallel to the long axis of the forearm and by the wedge of distal humerus that disrupts the annular ligament and interosseous membrane so that the divergence of the proximal radius and ulna occurs.^{2, 12, 13} Dislocation of the radial head can also be produced by a rotational (pronation) force.^{1, 3} Cadaver studies demonstrated that radial head dislocation can be produced by forced pronation of the forearm after the medial collateral ligament has been cut. Thus, with the forearm in forced pronation, the humerus is forced distally, separating the radius and ulna.¹⁴

Therefore, an axial thrust and a pronation force are involved in producing this injury, the priority and predominance of each of these forces can produce different divergent types.

Table 1 shows the summary of the literature review. As it is evident there are some discrepancies in the position of the radial head on physical examination, the authors' radiographic impressions, and the type of divergence described by the authors.

Reviewing the cases in the literature, it seems that the divergent dislocation of the elbow has different types according to the lodged position of radial head at the initial presentation, i.e.: 1) posterior divergence, 2) transverse (mediolateral)

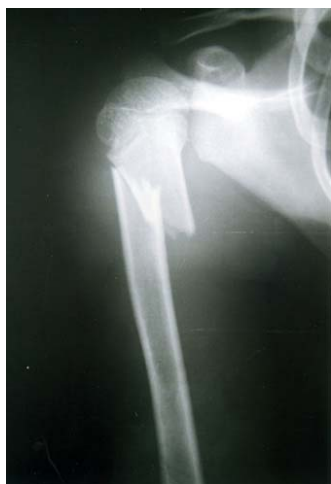

Figure 2. Fracture of the right humerus.

Table 1. Summary of the literature review.

Author	Year	No. of cases	Position of radial head on physical examination	Authors' radiographic impressions	Type of the divergence described by the authors
DeLee ¹	1981	1	Posterior	Transverse divergent dislocation of the elbow	Transverse
Carey ⁴	1984	2	1- Was not mentioned	1- Divergent dislocation of the elbow	1-Transverse
			2- Was not mentioned	2- Convergent (translocation of the radius and ulna)	2-Convergent
Andersen ³	1985	2	1- Dorsoradial	1- Transverse divergent dislocation of the elbow	1-Transverse
			2- Was not mentioned	2- Transverse divergent dislocation of the elbow	2- Transverse
McAuliffe ⁷	1988	1	Was not mentioned	Transverse divergent dislocation of the elbow	Transverse
Sovio ¹⁰	1986	1	Lateral	Divergence of the radius and ulna(direction was not mentioned)	Transverse
Holbrook ⁶	1988	1	Lateral	Divergent dislocation (direction was not mentioned)	Transverse
Hemmadi ⁵	1991	1	Lateral	Disruption of the superior radioulnar joint with posterior dislocation of the elbow	Divergent dislocation (the type was not specified)
Nakano ⁸	1992	1	Lateral	Transverse divergent dislocation	Transverse
Vicente ¹¹	1993	1	Lateral	Posterior dislocation of the elbow	Transverse
Shankarappa ⁹	1998	1	Lateral	Lateral and posterior dislocation of the radial head – posterior dislocation of the ulna	Transverse
Zaricznyj ¹²	2000	1	Lateral	Transverse (mediolateral) dislocation of the elbow	Transverse
Altuntas ²	2005	3	Was not mentioned	1-Posterior divergence	1-Posterior
				2- Anteroposterior divergence	2- Posterior
				3-Posterior divergence	3- Posterior

divergence, and 3) anteroposterior divergence. Because most of the radiographs are oblique views, usually giving a false impression, initial clinical examination and detection of the radial head position is more important for describing the type of divergent dislocation.

This patient had a mediolateral (transverse) divergent elbow dislocation. The radial head was palpable lateral to the distal humerus. The mechanism of dislocation was a severe forearm pronation and a longitudinal thrust through the hyperextended elbow.

In this injury, because of extensive capsular and ligamentous injury, closed reduction could be achieved easily but clinical suspicion should be paid to impending compartment syndrome because of major tearing of the interosseous membrane and the muscles of the forearm.^{4,5} There is no report of neurovascular injury associated with divergent dislocation of the elbow, but this patient suffered from median and ulnar nerves neuropraxia, which recovered completely after three months.

Residual disability and heterotopic ossification

or calcifications have not been reported in this injury.¹⁻¹² But this patient had residual limitation of forearm rotation and a restricted range of motion in the elbow because of extensive injury to the elbow's and interosseous ligaments.

References

- 1 DeLee JC. Transverse divergent dislocation of the elbow in a child. Case report. *J Bone Joint Surg Am.* 1981; **63**: 322 – 323.
- 2 Altuntas AO, Balakumar J, Howells RJ, Graham HK. Posterior divergent dislocation of the elbow in children and adolescents: a report of three cases and review of the literature. *J Pediatr Orthop.* 2005; **25**: 317 – 321.
- 3 Andersen K, Mortensen AC, Gron P. Transverse divergent dislocation of the elbow. A report of two cases. *Acta Orthop Scand.* 1985; **56**: 442 – 443.
- 4 Carey RP. Simultaneous dislocation of the elbow and the proximal radio-ulnar joint. *J Bone Joint Surg Br.* 1984; **66**: 254 – 256.
- 5 Hemmadi SS, Trivedi JM. Divergent dislocation of the elbow in a child (a case report). *J Postgrad Med.* 1991; **37**: 221 – 222, 222A.
- 6 Holbrook JL, Green NE. Divergent pediatric elbow dislocation. A case report. *Clin Orthop Relat Res.* 1988;

- 234: 72 – 74.
- 7 McAuliffe TB, Williams D. Transverse divergent dislocation of the elbow. *Injury*. 1988; **19**: 279 – 280.
 - 8 Nakano A, Tanaka S, Hirofuji E, Yasuwaki Y, Yamamoto T, Kubota S, et al. Transverse divergent dislocation of the elbow in a six-year-old boy: case report. *J Trauma*. 1992; **32**: 118 – 119.
 - 9 Shankarappa YK. Transverse divergent dislocation of the elbow with ipsilateral distal radius epiphyseal injury in a seven-year-old. *Injury*. 1998; **29**: 798 – 802.
 - 10 Sovio OM, Tredwell SJ. Divergent dislocation of the elbow in a child. *J Pediatr Orthop*. 1986; **6**: 96 – 97.
 - 11 Vicente P, Orduna M. Transverse divergent dislocation of the elbow in a child. A case report. *Clin Orthop Relat Res*. 1993; **294**: 312 – 313.
 - 12 Zaricznyj B. Transverse divergent dislocation of the elbow. *Clin Orthop Relat Res*. 2000; **373**: 146 – 152.
 - 13 Thompson GH. Dislocation of the elbow. In: Beaty JH, Kasser JR, eds. *Rockwood and Wilkins` Fractures in Children*. Vol 3. 5th ed. Philadelphia: Lippincott Williams and Wilkins; 2001: 705 – 739.
 - 14 Mezera K, Hotchkiss RN. Fractures and dislocations of the elbow. In: Bucholz RW, Heckman JD, eds. *Rockwood and Greens` Fractures in Adults*. Vol 1. 5th ed. Philadelphia: Lippincott Williams and Wilkins; 2001: 921 – 952.