

---

## Case Report

---

# CARPOMETACARPAL JOINT DISLOCATION OF THE THUMB ASSOCIATED WITH THE FRACTURE OF THE TRAPEZIUM

Ahmadreza Afshar MD<sup>\*</sup>, Fardin Mirzatoloei MD

---

**A 30-year-old man was referred to us with carpometacarpal joint dislocation of the thumb and fracture of the trapezium. The lesion was managed with closed reduction and percutaneous insertion of pin, resulting in good functional outcome.**

*Archives of Iranian Medicine, Volume 9, Number 3, 2006: 282 – 283.*

---

**Keywords:** Carpometacarpal dislocation • fracture • thumb • trapezium

### Introduction

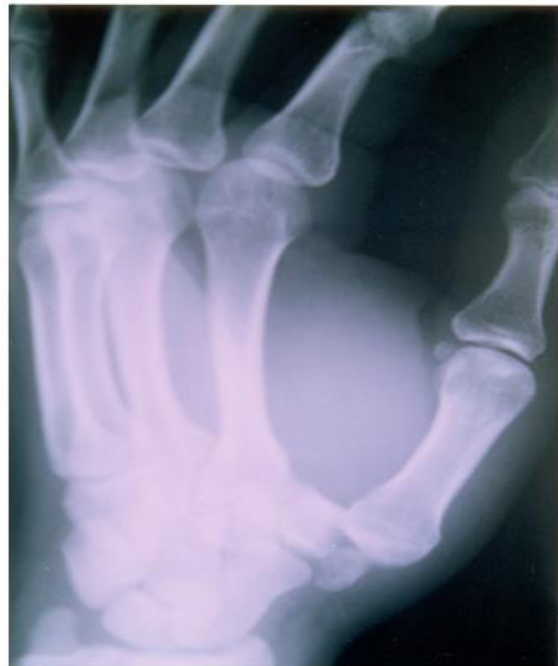
**D**islocation of the carpometacarpal (CMC) joint is a rare injury in thumb. Therefore, any associated lesion with dislocation of the CMC joint in thumb is very rare and thus, worth to be reported.<sup>1</sup> To the best of our knowledge, there are only three reports in English literature on such injury.<sup>2-4</sup>

There exist controversies on which ligaments are damaged in dislocation of the CMC joint of the thumb and on which ligaments are most important in maintaining the joint stability. The recommended treatment has ranged from closed treatment and casting to open ligament reconstruction. In this report, the experience to manage a patient with dislocation of the CMC joint of the thumb plus fracture of the trapezium is presented.

### Case Report

A 30- year-old motorcyclist man, who was hurt in a road accident, presented with pain, tenderness, and swelling of the base of his right thumb. X-ray revealed dorsal dislocation of the CMC joint of his left thumb plus fracture of the trapezium (Figure 1).

Using axillary nerve block, closed reduction of the CMC joint dislocation was done. A repeated X-ray showed reduction of the CMC joint and fracture of the trapezium, without development of any step or incongruency in the joint. The reduction was maintained by percutaneous insertion of pin through the base of the thumb metacarpal and trapezium. The thumb was immobilized with cast. After six weeks, the cast



**Figure 1.** Carpometacarpal joint dislocation of the thumb plus fracture of the trapezium.

---

**Authors' affiliation:** Department of Orthopedics, Shaheed Motahhari Hospital, Urmia, Iran.

**•Corresponding author and reprints:** Ahmadreza Afshar MD, Department of Orthopedics, Shaheed Motahhari Hospital, Kashani St., Urmia, Iran.

Fax: +98-441-223-4125, E-mail: afshar@umsu.ac.ir.

Accepted for publication: 2 November 2005

and the pin were removed. Then, the motion of the thumb CMC joint was started. The thumb and the CMC joint were further protected for another six weeks with a splint. In follow-up, the patient gained full range of motion of his CMC joint without any pain or instability.

## Discussion

Dislocation of the CMC joint of the thumb is a rare injury. The mechanism of the injury has been described as axial loading and flexion of the thumb metacarpal bone.<sup>5-6</sup> Though rare, dislocation of the CMC joint of the thumb may be associated with other injuries such as fracture of the trapezium—like in this patient.<sup>2-4</sup>

There are four ligaments that stabilize the thumb CMC joint. These include the intermetacarpal ligament, the anterior oblique ligament, the radial (dorsoradial) ligament, and the posterior oblique ligament.<sup>6</sup>

Eaton and Littler believed that the anterior oblique ligament was the key structure in stabilizing the joint.<sup>7</sup> Strauch et al found that the dorsoradial ligament is the main restraint to dorsal dislocation of the joint.<sup>6</sup>

If all ligaments are disrupted, the joint will be completely unstable, and early open ligament reconstruction is recommended.<sup>5-8</sup> If ligament reconstruction is undertaken, the function of the dorsoradial ligament and the anterior oblique ligament should be restored.<sup>6</sup>

There are evidences that in dislocation of the CMC joint of the thumb, after rupture of the dorsoradial ligament, the anterior oblique ligament, though intact, is stripped subperiosteally. Extension and pronation of the thumb tightens the stripped anterior oblique ligament.<sup>6-9</sup>

In our patient, instead of the ligament rupture, a part of the trapezium attached to the dorsoradial

ligament was fractured, and with association of the subperiosteally-stripped anterior oblique ligament, caused dislocation of the thumb CMC joint. After reduction, the stripped anterior oblique ligament was brought to its position. By the union of the trapezium fracture, the dorsoradial part of the thumb CMC joint became also stable. Therefore, if the dorsolateral part (ligament) heals in an appropriate position, the thumb CMC joint becomes stable. This experience is in agreement with the findings of Strauch et al who assert that the dorsoradial ligament is the main restraint to dorsal dislocation of the thumb CMC joint.

## References

- 1 Henry M. Fractures and dislocations of the hand. In: Bucholz RW, Heckman JD, eds. *Rockwood and Green's Fractures in Adults*. 5th ed. Volume 1. Philadelphia: Lippincott; 2001: 655 – 748.
- 2 Kukreti S, Harrington P. Carpometacarpal joint dislocation of the thumb associated with fracture of the trapezium: a case report. *Eur J Orthop Surg Traumatol*. 2004; **14**: 38 – 39.
- 3 Mody BS, Dias JJ. Carpometacarpal dislocation of thumb associated with fracture of trapezium. *J Hand Surg [Br]*. 1993; **18**: 197 – 199.
- 4 Tolat AR, Jones MW. Carpometacarpal dislocation of the thumb associated with fracture of trapezium. *Injury*. 1990; **21**: 411 – 412.
- 5 Shah J, Petal M. Dislocation of carpometacarpal joint of the thumb. *Clin Orthop*. 1983; **175**: 166 – 169.
- 6 Strauch RJ, Berhman MJ, Rosenwasser MP. Acute dislocation of the carpometacarpal joint of the thumb: an anatomic and cadaver study. *J Hand Surg [Am]*. 1994; **19**: 93 – 98.
- 7 Eaton RG, Littler JW. Ligament reconstruction for the painful thumb carpometacarpal joint. *J Bone Joint Surg*. 1973; **55**: 1655 – 1666.
- 8 Simonian PT, Trumble TE. Traumatic dislocation of the thumb carpometacarpal joint: early ligamentous reconstruction versus closed reduction and pinning. *J Hand Surg [Am]*. 1996; **21**: 802 – 806.
- 9 Wee JTK, Chandra D, Satku K. Simultaneous dislocations of the interphalangeal and carpometacarpal joints of the thumb: a case report. *J Hand Surg*. 1988; **13**: 224 – 226.