



Transforaminal lumbar interbody fusion versus instrumented posterolateral fusion In degenerative spondylolisthesis: An attempt to evaluate the superiority of one method over the other



Amir Abbas Ghasemi*

Neurosurgery Department, Urmia Medical University, Ershad Blvd, Imam Khomeini Hospital, Urmia, Iran

ARTICLE INFO

Article history:

Received 1 July 2016

Received in revised form 18 August 2016

Accepted 20 August 2016

Available online 21 August 2016

Keywords:

Transforaminal lumbar interbody fusion

Posterolateral fusion

Fusion rate

Outcome

ABSTRACT

Background: Various surgical procedures have been recommended for the treatment of degenerative spondylolisthesis, but Controversy still exists regarding the optimal surgical technique. In this study, we compared the clinical and radiologic outcome of the Transforaminal lumbar interbody fusion (TLIF) method with the Instrumented Posterolateral fusion (PLF) in these patients.

Methods: The study population in this retrospective study consisted of 145 consecutive patients of degenerative spondylolisthesis who had undergone lumbar fusion in our institute between September 2010 and October 2013. The patients were divided into two treatment groups, where either instrumented PLF with pedicle screw (180° fusion) or TLIF procedure (360° fusion) was done. The follow-up was performed clinically using the Oswestry Disability Index (ODI), visual analogue scale (VAS) and global outcome. Outcome scores were assessed at 3, 6, 12, and 24 months after surgery. Radiographs were obtained postoperatively and at regular intervals for 24 months. Perioperative outcomes such as surgery time, blood loss, length of hospital stay and incidence of surgical complications were also recorded.

Results: 80 patients underwent TLIF procedure and 65 patients were included in the instrumented PLF group. There were no significant differences between the groups with respect to age, gender, Body Mass Index, smoking and comorbid conditions ($p > 0.05$). No significant difference existed in Pre-operative VAS for back pain, VAS for leg pain and ODI between the two groups ($p > 0.05$). There were no significant group differences in the operation level, hospital stay and surgical complications (all $p > 0.05$). Blood loss, operation time and fusion success rate were significantly greater in the TLIF group than in the PLF group (all $P < 0.05$). Significant differences between groups concerning VAS for back pain, ODI and Global outcome were present at final follow-up. There was no significant difference between the two groups with respect to VAS for leg pain.

Conclusion: Our study showed that TLIF is superior to PLF with respect to functional outcome and fusion rate.

© 2016 Elsevier B.V. All rights reserved.

1. Background

Spondylolisthesis is a complex and challenging multifactorial condition. Spondylolisthesis is the forwards slippage of one vertebra on another. Degenerative spondylolisthesis differs from spondylolytic spondylolisthesis by the absence of a pars interarticularis defect (spondylolysis), i.e., in Degenerative spondylolisthesis

the whole upper vertebra (vertebral body and posterior part of the vertebra including neural arch and processes) slips relative to the lower vertebra. Degenerative changes within the facet joints are partly responsible for allowing forward slip. It is more common in people over age 50, and far more common in individuals older than 65. [1,2]. Medical treatment is usually the first line of management. Surgical options are preserved to cases with failure of conservative treatment or those with neurological deficits. The ideal surgical treatment for spondylolisthesis remains controversial. Surgical decompression alone may be performed for the treatment of low grade degenerative lumbar spondylolisthesis in some patients [3], but Surgical treatment of spondylolisthesis generally consists of a fusion procedure with or without neural decompression [4,5]. Posterolateral fusion (PLF) using pedicle screw has long been the gold

Abbreviations: VAS, visual analogue scale; ODI, Oswestry disability index; TLIF, transforaminal lumbar interbody fusion; PLF, posterolateral fusion.

* Correspondence to: Urmia University of Medical Sciences, Ershad BLVD, Imam Khomeini hospital, Neurosurgery department, Urmia, Iran.

E-mail address: dr.amirghasemi@ymail.com

standard for the surgical treatment of degenerative spondylolisthesis. However, it is difficult to achieve a solid fusion from the posterior approach because of the laminar bone removal limits the posterolateral bony host bed available for grafting. To solve this problem, other fusion procedures including anterior lumbar interbody fusion (ALIF) or “360°-fusion” e.g., PLF in combination with ALIF, posterior lumbar interbody fusion (PLIF) or Transforaminal lumbar interbody fusion (TLIF) have been introduced [6,7]. Biomechanically, TLIF provides anterior column support and a posterior tension band. Moreover, a circumferential fusion may be achieved through a single posterior approach if a lumbar interbody fusion is combined with posterolateral fusion. In theory TLIF provides several advantages when compared with PLF as it immobilizes the painful degenerated spinal segments, decompress the nerve roots, and restores disc height and root canal dimensions, as well as load bearing ability of the anterior structures. successful interbody construct reduces the postoperative segmental mobility and permits better graft incorporation [8]. Consequently, interbody fusion is recognized by many to be the treatment of choice for degenerative spondylolisthesis of the lumbar spine. Despite these theoretical advantages, Controversy still exists in regards to which technique is superior to the others for the treatment of degenerative spondylolisthesis. In this regard we decided to compare the instrumented PLF method with the TLIF, in patients with degenerative spondylolisthesis.

2. Methods

The study population in this retrospective study (an observational study using analytic retrospective study cohort design) consisted of 145 consecutive patients of degenerative spondylolisthesis who had undergone lumbar fusion in our institute between September 2010 and October 2013. Informed consent were obtained from patients before the operation. Clinical data of patients were anonymized by the author. The choice of lumbar fusion technique was individualized based on clinical needs of each patient, surgeon preferences and patients request according to the informed consent and explanation of various surgical procedures. The patients were divided into two treatment groups, where either instrumented PLF with pedicle screw (180° fusion) or TLIF procedure (360° fusion) was done. Inclusion criteria consisted of Degenerative spondylolisthesis (grade 1 or 2) at single level, patients with back and/or leg pain with or without neurological symptoms who failed to respond to at least six weeks of non-surgical treatment and at least 2 years of follow-up. Exclusion criteria consisted of: Degenerative spondylolisthesis grade 3 and 4; greater than 2 level instrumentation; Spondylolysis and other types of spondylolisthesis; Patients who have had posterolateral fusion without instrumentation; Nonunion; history of previous surgery to the lumbar spine; Concomitant deformities of the spine (scoliosis, tumor, or trauma) and osteoporosis diagnosed by means of radiography and bone mineral density examination. Primary diagnosis of spondylolisthesis was made by AP and Lateral plain X-Rays. Standing Lateral flexion and extension dynamic X-Rays performed in order to evaluate the stability of the lumbar area. Lumbosacral MRI was performed on all the cases.

All surgical operations were performed by the same surgeon using the same surgical technique. surgeries were done in prone position under controlled hypotensive general anaesthesia. At the beginning, pedicle screws were inserted for the patients by a mid-line approach. When indicated, hemilaminectomy or laminectomy was done and nerve root was followed out past its nerve root canal to ensure adequate decompression and remove any other bony or soft tissue impingement. In the TLIF group, the facet joint of the intended levels was identified and the inferior and superior facets

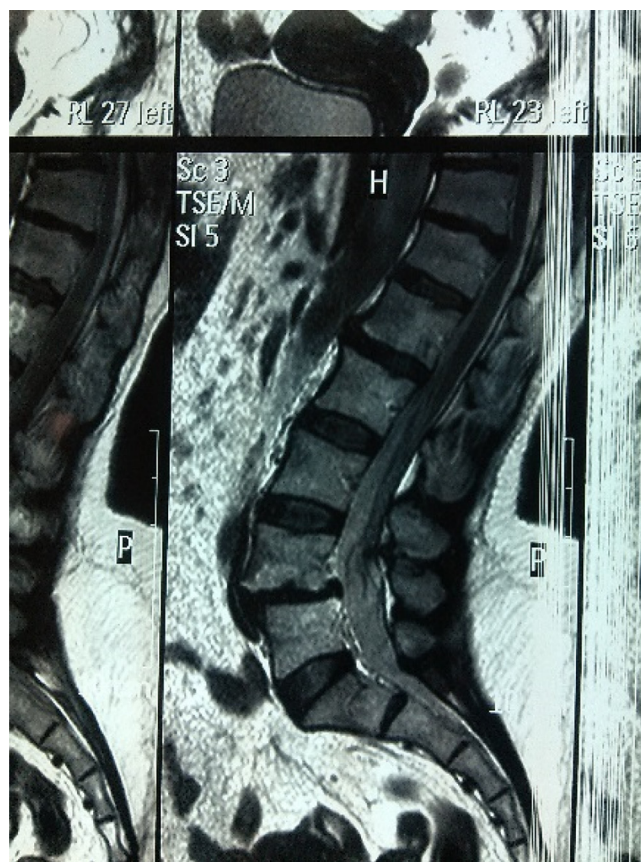

Fig. 1. Lumbosacral MRI Showing L4/L5 spondylolisthesis.

were resected to gain access to the disc space. An annulotomy was made, followed by complete discectomy and endplate preparation. The pedicle screws were used to distract. The upper nerve was identified and protected. The PEEK (polyetheretherketone) cage filled with autologous bone was placed after cleaning the disc space. Compression over the disc space was done after placement of the cage in order to create lordosis. Autograft from the lamina, spinous process and facet joint were used as bone graft and placed on the transverse process of the vertebrae fused. The suction drains were removed after the second post operative day. Sutures removal was done on the 10th post operative day. Ambulation was started on the 2nd post operative day with a lumbosacral brace which they wore for 3 months.

Patient-assessed questionnaires included the visual analogue scale (VAS) for low back pain and leg pain and the Oswestry Disability Index (ODI) for disability and quality of life. The global outcome was measured during follow-up period, on a 4 point Likert scale (helped a lot, helped only little, didn't help, made things worse). Radiographs were obtained postoperatively and at regular intervals for 24 months. The criteria used to prove solid fusion in patients were: Trabeculae seen bridging the interbody gap with isodense bone in the cage and the adjacent vertebral bodies, Anterior and/or posterior sentinel signs, No lucencies around the pedicle screws, No lucencies around the cages, Integration of the cage with the endplates and silhouetting of the cage, No evidence of motion on dynamic flexion and extension x-rays.

Perioperative outcomes such as surgery time, blood loss, length of hospital stay and incidence of surgical complications were also recorded.

The statistical analysis was performed with Statistical Package for the Social Sciences, Version 18 (SPSS, Inc., Chicago, IL, United States). Descriptive statistics for Continuous data was presented as

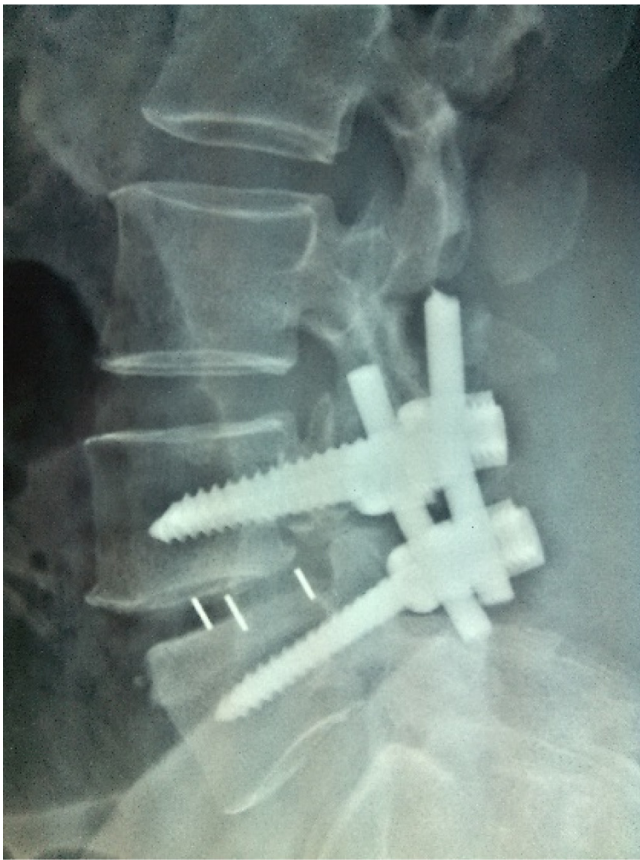

Fig. 2. A postoperative X-ray illustrating the pedicle screw construct and interbody cage used to correct the deformity.

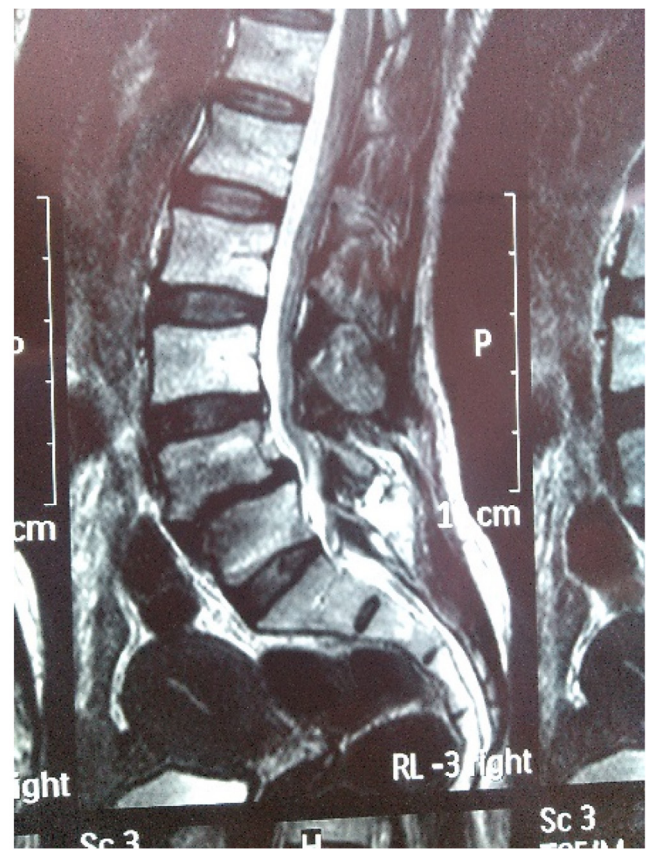

Fig. 3. Lumbosacral MRI Showing L4/L5 spondylolisthesis.

Table 1
Demographic data of patients.

variable	TLIF group (N=80)	PLF group (N=65)	P value
Age(year)	58.3 ± 9.6	59.6 ± 10.1	0.429
Gender:			0.133
Male	29	16	
Female	51	49	
Body Mass Index(kg/m ²)	28.4 ± 1.9	28.1 ± 1.2	0.270
Smoking			0.737
Yes	10	7	
No	70	58	
Comorbid conditions:			0.579
Diabetes	8	6	
Cardiovascular problem	15	10	

mean ± standard deviation. For unpaired data, the Mann-Whitney *U* test was used, and for paired data, the Wilcoxon signed rank test was used. The chi-square test was used for the comparisons between ordinal variables such as global outcome. For statistical significance, the probability value of less than 0.05 was considered. The Medical Ethical Committees of Urmia University of medical sciences approved the study.

3. Results

Eighty patients underwent TLIF procedure (Figs. 1, 2) and sixty-five patients were included in the instrumented PLF group (Figs. 3, 4). A summary of demographic and pre-operative data is presented in Table 1. There were no significant differences between the groups with respect to age, gender, Body Mass Index, smoking and comorbid conditions. Pre-operative baseline

clinical data of patients is presented in Table 2. There was a similar lack of significant group difference for all variables. Surgery related parameters are shown in Table 3. There were no significant group differences in the operation level, hospital stay and surgical complications (all $p > 0.05$). Blood loss, operation time and fusion success rate were significantly greater in the TLIF group than in the PLF group (all $P < 0.05$).

Table 4 shows the outcomes in the two groups, 2 years after surgery. There were significant differences between the groups in relation to VAS for back pain, ODI and Global outcome. These variables were significantly better in the TLIF group than the PLF group. There was no significant difference between the two groups with respect to VAS for leg pain at final follow-up.

4. Discussion

Degenerative spondylolisthesis is an acquired anterior displacement of one vertebra over the subjacent vertebra, associated with degenerative changes, without an associated disruption or defect in the vertebral ring. The majority of patients with symptomatic degenerative lumbar spondylolisthesis and an absence of neurologic deficits will do well with conservative care. Patients who present with sensory changes, muscle weakness or cauda equina syndrome, are more likely to develop progressive functional decline

Table 2
Baseline self-rated clinical data of patients.

Variable	TLIF(N=80)	PLF(N=65)	P value
VAS for back pain	7.5 ± 1.9	6.9 ± 2.7	0.119
VAS for leg pain	5.2 ± 2.3	4.9 ± 2.2	0.427
ODI	27.9 ± 11.1	29 ± 10.9	0.550

Table 3
surgery related parameters in TLIF and PLF groups.

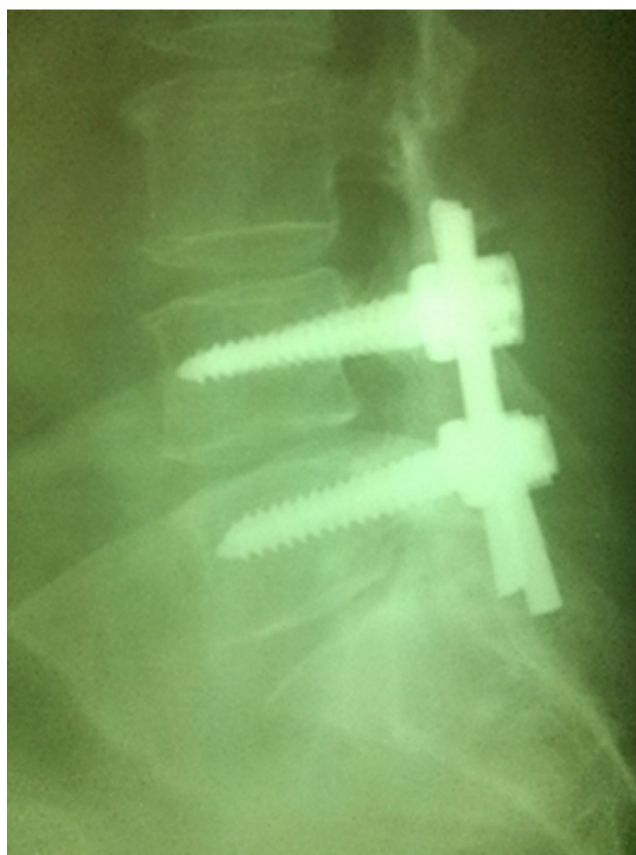
Variable	TLIF(N = 80)	PLF(N = 65)	P value
Operation level: L4/L5 L5/S1 L3/L4	53 21 6	39 19 7	0.4350.6890.490
Operation time (min)	165 ± 36	130 ± 28	0.0001
Spondylolisthesis Grade: 1 2	72 8	59 6	0.872
Blood loss (ml)	810 ± 232	657 ± 186	0.0001
Hospital stay (day)	6.2 ± 3.4	5.7 ± 2.9	0.348
Complications: Infection Durotomy Root injury	3 4 2	2 3 1	0.6890.9120.689
Fusion success (%)	92	81	0.049

Table 4
Outcome scores of patients at final follow-up.

Variable	TLIF(N = 80)	PLF(N = 65)	P value
VAS for back pain	1.9 ± 0.8	2.3 ± 1.4	0.032
VAS for leg pain	2.4 ± 1.6	2.7 ± 2.0	0.317
ODI	10.9 ± 7.3	15.4 ± 9.5	0.001
Global Outcome: –helped a lot–helped only little–didn't help–made things worse	69 6 4 1	41 13 7 4	0.001

without surgery [9]. The surgical treatment of choice for the management of degenerative spondylolisthesis remains a matter of controversy [10]. Surgical decompression with fusion is recommended for the treatment of patients with symptomatic spinal stenosis and degenerative lumbar spondylolisthesis to improve clinical outcomes [11].

Although Several comparative studies of different fusion techniques have been performed in lumbar conditions, but there is insufficient evidence to make a recommendation for or against the use of either decompression with posterolateral fusion or 360° fusion in the surgical treatment of patients with degenerative lumbar spondylolisthesis. Swan et al. [12], compared instrumented posterolateral fusion with circumferential fusion in patients with radiographically unstable isthmic spondylolisthesis in a non-randomized prospective cohort study and realized significantly better outcomes with 360° fusion at 6 months and 1 year, however, between-group differences attenuated appreciably after 24 months. Park et al. [13], retrospectively compared the outcomes of patients undergoing either decompression alone or decompression with fusion and fixation for the treatment of degenerative spondylolisthesis. this study showed that in patients with stable degenerative lumbar spondylolisthesis, results of unilateral laminectomy and bilateral decompression may be similar to instrumented fusion for functional outcomes and lower extremity pain scores. Martin et al. [14] conducted a systematic review designed to identify and analyze comparative studies that examined the surgical management of degenerative lumbar spondylolisthesis, specifically the differences in outcomes between fusion and decompression alone, and between instrumented fusion and non-instrumented fusion. This paper showed that fusion leads to a better clinical outcome compared with decompression alone and the use of adjunctive instrumentation leads to improved fusion status and less risk of pseudarthrosis. Their data does not demonstrate any difference in clinical outcomes between instrumented and noninstrumented fusions. In a retrospective comparative study, Ha et al. [15] evaluated the effects of posterior lumbar interbody fusion (PLIF) after posterolateral fusion (PLF) on patients undergoing surgical treatment for degenerative spondylolisthesis. Forty patients, who underwent single level decompression and posterior instrumentation at L4-5, were followed for at least 2 years. This study showed that the addition of PLIF to unstable segments may improve the surgical outcome for degenerative spondylolisthesis and appears to improve disc height. Rousseau et al. [16] conducted a retrospective comparative study of 24 consecutive patients undergoing decompression and transpedicular fixation to treat symptomatic degenerative lumbar spondylolisthesis. The

**Fig. 4.** Lateral X- ray of L4/L5 spondylolisthesis operated on with laminectomy and pedicular screw construct.

authors concluded that posterior decompression and fusion is successful in treating degenerative lumbar spondylolisthesis and that the additional circumferential fusion yields significant improvement in functional outcomes. Andersen et al. [17] randomized patients with a variety of degenerative conditions to posterolateral fusion with or without pedicle screw instrumentation and found no significant differences in pain outcomes at 5 years. Fritzell et al. [18], randomized 222 patients with degenerative low back pain to posterolateral in situ fusion, instrumented PLF and 360° fusion and 72 patients to a nonsurgical group. The clinical outcomes were the same among the 3 fusion groups at 2-years.

In our study, we observed better clinical outcome in the TLIF group compared to the PLF group after 2 years. Hoy et al [19], performed a randomized study comparing TLIF with a PLF procedure, and found no significant difference with respect to functional outcome. There was no significant difference between the two groups with respect to VAS for leg pain. This result is in contrast to the finding of Høy et al. (They observed slightly more leg pain in the TLIF group at 2-year follow-up).

The radiologic successful fusion rate in this study (92% in TLIF group and 81% in PLF group) is close to the 90% to 100% reported by another studies [20,21].

Operation time and blood loss were significantly higher in the TLIF group, but did not prolong their hospital stay. In our study, the complication rate in the TLIF group was not significantly higher than the PLF group. This may be due to the fact that all the operations were performed by an experienced surgeon in a single-center. Our study had several limitations that must be considered while interpreting its results, including its retrospective, nonrandomized design. In addition, there was a possibility of selection bias as the surgeon tended to choose TLIF for some patients and PLF for the others.

5. Conclusion

With Our study showed that TLIF is superior to PLF with respect to functional outcome and fusion rate.

Conflicts of interest

There are no conflicts of interest.

Acknowledgement

We are thankful to our colleague Dr. Behshad Behfar who provided expertise that greatly assisted the research.

References

- [1] M. Alam, W. Bari, Omar S. Incidence, diagnosis and management of adult cases presenting with symptomatic lumbar spondylolisthesis in a tertiary care hospital, *Int. J. Res. Med. Sci.* 4 (1) (2016) 38–41.
- [2] L. Kalichman, D.J. Hunter, Diagnosis and conservative management of degenerative lumbar spondylolisthesis, *Eur. Spine J.* 17 (2008) 327–335.
- [3] M.A. Murat, T. Cansever, A. Yilmaz, H. Cavuşoğlu, I. Yuçe, et al., Midterm outcome after a microsurgical unilateral approach for bilateral decompression of lumbar degenerative spondylolisthesis: clinical article, *J. Neurosurg. Spine* 16 (1) (2012) 68–76.
- [4] Giovanni la rosa, Pedicle screw fixation for isthmic spondylolisthesis: does posterior lumbar interbody fusion improve outcome over posterolateral fusion? *J. Neurosurg. (Spine)* 2 (2003) 143–150.
- [5] J.W. Brantigan, A. Neidre, Achievement of normal sagittal plane alignment using a wedged carbon fiber reinforced polymer fusion cage in treatment of spondylolisthesis, *Spine* 3 (2003) 186–196.
- [6] P. Ekman, H. Möller, T. Tullberg, P. Neumann, R. Hedlund, Posterior lumbar interbody fusion versus posterolateral fusion in adult isthmic spondylolisthesis, *Spine* 32 (2007) 2178–2183.
- [7] J. Zhao, X. Wang, T. Hou, S. He, One versus two BAK fusion cages in posterior lumbar interbody fusion to L4–L5 degenerative spondylolisthesis: a randomized, controlled pro-spective study in 25 patients with minimum two-year follow-up, *Spine* 27 (2002) 2753–2757.
- [8] D.L. Yan, F.X. Pei, J. Li, C.L. Soo, Comparative study of PLIF and TLIF treatment in adult degenerative spondylolisthesis, *Eur. Spine J.* 17 (10) (2008) 1311–1316.
- [9] A. Pearson, E. Blood, J. Lurie, T. Tosteson, W.A. Abdu, et al., Degenerative spondylolisthesis versus spinal stenosis: does a slip matter? Comparison of baseline characteristics and outcomes (SPORT), *Spine* 35 (3) (2010) 298–305.
- [10] S.G. Osman, Endoscopic transforaminal decompression, interbody fusion, and percutaneous pedicle screw implantation of the lumbar spine: a case series report, *Int. J. Spine Surg.* 6 (1) (2012) 157–166.
- [11] F.S. Kleinstueck, T.F. Fekete, A.F. Mannion, D. Grob, F. Porchet, et al., To fuse or not to fuse in lumbar degenerative spondylolisthesis: do baseline symptoms help provide the answer? *Eur. Spine J.* 21 (2) (2012) 268–275.
- [12] J. Swan, E. Hurwitz, F. Malek, et al., Surgical treatment for unstable low-grade isthmic spondylolisthesis in adults: a prospective controlled study of posterior instrumented fusion compared with combined anterior-posterior fusion, *Spine* 6 (2006) 606–614.
- [13] J.H. Park, S.J. Hyun, S.W. Roh, S.C. Rhim, A comparison of unilateral laminectomy with bilateral decompression and fusion surgery in the treatment of grade I lumbar degenerative spondylolisthesis, *Acta Neurochir.* 154 (7) (2012) 1205–1212.
- [14] C.R. Martin, A.T. Gruszczynski, H.A. Braunsfurth, S.M. Fallatah, J. O'Neil, et al., The surgical management of degenerative lumbar spondylolisthesis: a systematic review, *Spine* 32 (16) (2007) 1791–1798.
- [15] K.Y. Ha, K.H. Na, J.H. Shin, K.W. Kim, Comparison of posterolateral fusion with and without additional posterior lumbar interbody fusion for degenerative lumbar spondylolisthesis, *J. Spinal Disord. Tech.* 21 (4) (2008) 229–234.
- [16] M.A. Rousseau, J.Y. Lazennec, E.C. Bass, G. Saillant, Predictors of outcomes after posterior decompression and fusion in degenerative spondylolisthesis, *Eur. Spine J.* 14 (1) (2005) 55–60.
- [17] T. Andersen, F.B. Christensen, E.S. Hansen, Pain 5 years after instrumented and noninstrumented posterolateral lumbar spinal fusion, *Eur. Spine J.* 12 (2003) 393–399.
- [18] P. Fritzell, O. Hagg, P. Wessberg, et al., Chronic low back pain and fusion: a comparison of three surgical techniques: a prospective multicenter randomized study from the Swedish lumbar spine study group, *Spine* 27 (2002) 1131–1141.
- [19] K. Høy, C. Bünger, B. Niederman, Transforaminal lumbar interbody fusion (TLIF) versus posterolateral instrumented fusion (PLF) in degenerative lumbar disorders: a randomized clinical trial with 2-year follow-up, *Eur. Spine J.* 22 (9) (2013) 2022–2029.
- [20] R.H. Wu, J.F. Fraser, R. Härtl, Minimal access versus open transforaminal lumbar interbody fusion: meta-analysis of fusion rates, *Spine (Phila Pa 1976)* 35 (26) (2010) 2273–2281.
- [21] C.S. Lee, C.J. Hwang, D.H. Lee, Y.T. Kim, H.S. Lee, Fusion rates of instrumented lumbar spinal arthrodesis according to surgical approach: a systematic review of randomized trials, *Clin. Orthop. Surg.* 3 (1) (2011) 39–47.