

RESEARCH ARTICLE

Correlation of Reconstructed Scaphoid Morphology with Clinical Outcomes

Ahmadreza Afshar, MD; Afshin Mohammadi, MD; Kian Zohrabi, MD; Nasrin Navaeifar, MD; Sam H. Sami, MD; Hassan Taleb, MD

Research performed at Urmia University of Medical Sciences, Urmia, Iran

Received: 9 July 2015

Accepted: 17 August 2015

Abstract

Background: Scaphoid malunion alters the carpal kinematics and impairs clinical outcome because of pain, weakness, restricted range of motion and predisposing the wrist joint to early osteoarthritis. The aim of this study was to evaluate the influence of the scaphoid morphological angles on clinical outcomes in patients with reconstructed scaphoid by non-vascularized bone graft.

Methods: Seventeen male patients with the mean age of 31.7 ± 3.7 years and mean non-union time of 31.5 ± 14.7 months were enrolled in this retrospective study. Average follow up was 48.8 ± 9.4 months. At the last follow-up, the patients were evaluated clinically for pain, wrist range of motion, grip strength, and wrist functional status. They were also evaluated radiologically by wrist radiographs and computerized tomography (CT). The overall clinical outcomes were evaluated by the Cooney wrist function score. The morphology of the reconstructed scaphoids was evaluated by the lateral intrascaphoid angle, anteroposterior intrascaphoid angle, dorsal cortical angle, measuring the length (mm), and height-to-length ratio on CT scan. The radiological measurements were compared against the overall clinical outcomes.

Results: There were 7 excellent, 7 good, 3 fair clinical results. The mean Cooney wrist function score was 83 ± 4 . The mean lateral intrascaphoid angle was 34.8 ± 1.4 degrees, mean anteroposterior intrascaphoid angle was 33.4 ± 2.2 degrees, mean dorsal cortical angle was 158.3 ± 4.8 degrees, mean scaphoid length was 22.1 ± 0.7 mm, and mean scaphoid height-to-length ratio was 0.74 ± 0.04 . There were no significant statistical correlations between the lateral intrascaphoid angles, anteroposterior intrascaphoid angles, dorsal cortical angles, scaphoid lengths and scaphoid height-to-length ratios and Cooney wrist scores in the patients.

Conclusion: In the current study, all the patients had some degree of scaphoid malunion; however, the radiological measurements of the reconstructed scaphoids did not correlate with the clinical outcomes.

Keywords: Intrascaphoid angle, Scaphoid fracture, Scaphoid non-union, Scaphoid mal-union, Scaphoid morphology

Introduction

The treatment aims for scaphoid non-unions are to relief pain, achieve osseous union across the fractured site, reconstruct the scaphoid morphology and increase function of the wrist. Hence, scaphoid malunion and the change in the scaphoid morphology should be given due attention because it affects the kinematic of the wrist joint and impairs the clinical outcome because of pain, weakness, restricted range of motion (ROM) and predisposes the wrist joint to early osteoarthritis (1-12).

In the current study we first determined the scaphoid morphological angles in the patients with reconstructed

scaphoid by non-vascularized bone graft, and then we evaluated the hypothesis of whether there is a correlation between the scaphoid morphological angles and clinical outcomes.

Material and Methods

In this retrospective study, we reviewed our hospital database and looked for the patients with the middle third scaphoid non-unions who were treated by non-vascularized bone graft via the Matti-Russe technique, between March 2008 and March 2015 (13). The diagnosis and indications for surgery were based on standard wrist radiographs. All the surgeries were

Corresponding Author: Ahmadreza Afshar, Department of Orthopedics, Imam Khomeini Hospital, Modares Street, Ershad Boulevard, Urmia, Iran
E-mail: afshar_ah@yahoo.com



THE ONLINE VERSION OF THIS ARTICLE
ABJS.MUMS.AC.IR

performed by one surgeon. The institutional review board approved the study.

From a total of 68 patients, 17 male patients with the mean age of 31.7 ± 3.7 (range: 22-45) years and mean non-union time of 31.5 ± 14.7 months were enrolled into our study after signing informed consent forms. Twelve surgeries were performed on the right side and 5 surgeries were performed on the left side. Also, none of the patients had a history of being operated on. The mean post operative follow-up was 48.8 ± 9.4 (range: 20-75) months. All the surgeries were performed by the volar approach according to the Matti-Russe technique without internal fixation (13).

At the final follow-up each patient's pain was evaluated by the visual analogue scale (VAS) (range: 0 to 10). The pain was also graded as: none, mild (occasional and on strenuous activity), moderate (tolerable and on light work), and severe (intolerable and unable to work because of pain) according to the Cooney wrist function score (14). Wrist range of movement (ROM) of the affected side was measured and its percentage to the normal side was calculated. Wrist ROM was the sum of flexion, extension, radial deviation and ulnar deviation movements. Grip strength (kg) of the affected side and its percentage to the normal side (Jamar dynamometer, Sammons Peterson, Bolingbrook, IL, U.S.A.) was also measured. The functional status of the wrist was determined and graded as return to regular work, restriction in work, able to work but unemployed, and unable to work because of pain according to the Cooney wrist function score. The pain grade, wrist ROM, grip strength and functional status of the wrist scores were added to calculate a total Cooney wrist function score that ranges from 0 to 100 and the higher scores indicate more favorite outcome (14).

Osseous union, presence or absence of avascular necrosis and presence or absence of post traumatic

osteoarthritis of the wrists was verified by the wrist radiographs. The morphology of the reconstructed scaphoids and normal contralateral scaphoids were evaluated by measuring the lateral intrascaphoid angle [Figure 1], anteroposterior intrascaphoid angle [Figure 2], dorsal cortical angle [Figure 3], length (mm) and height-to-length ratio on computerized tomography (CT) scan images [Figure 4]. The measurements of the reconstructed scaphoids were compared with the normal contralateral scaphoids. The intrascaphoid angles were measured by the intersection of the two perpendicular lines drawn from the distal and proximal scaphoid articular surfaces on the sagittal and coronal CT cuts (15). In the 17 contralateral normal scaphoids the lateral intrascaphoid angle was 30.7 ± 1 degrees, anteroposterior intrascaphoid angle was 37.9 ± 1.8 degrees, mean dorsal cortical angle was 139.1 ± 1 degrees, mean scaphoid lengths was 23.1 ± 0.6 mm and scaphoid height-to-length ratio was 0.64 ± 0.02 .

The interviews and examinations were performed by one of the authors who did not perform the surgeries. All the radiologic measurements were accomplished by a radiologist. T student and Wilcoxon signed ranks tests were used to compare the data. P values less than 0.05 were considered statistically significant.

Results

Table 1 shows the clinical outcomes and radiological measurements of the 17 patients. There were 7 excellent, 7 good, and 3 fair clinical results. The mean Cooney wrist function score was 83 ± 4 and the mean VAS score was 0 ± 0.81 . All the patients had different radiological measurements from their normal sides. The mean lateral intrascaphoid angle was 34.8 ± 1.4 degrees, mean anteroposterior intrascaphoid angle was 33.4 ± 0.2 degrees, mean dorsal cortical angle was 158.3 ± 4.8 degrees, mean scaphoid lengths was 22.1 ± 0.7 mm and mean scaphoid

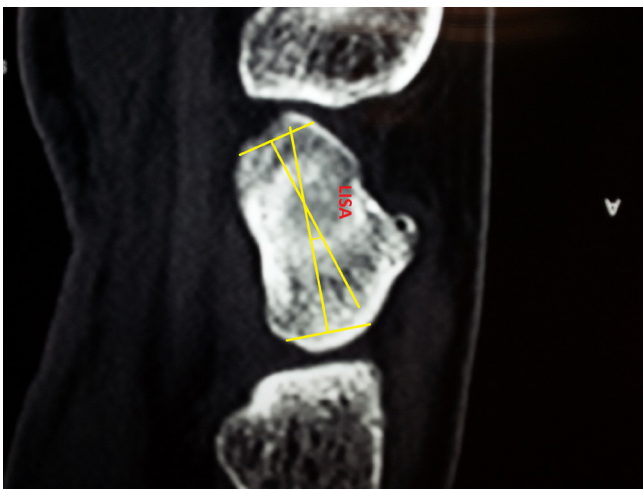


Figure 1. The lateral intrascaphoid angle (LISA) was measured by the intersection of the two perpendicular lines drawn from the distal and proximal scaphoid articular surfaces on sagittal CT cuts.

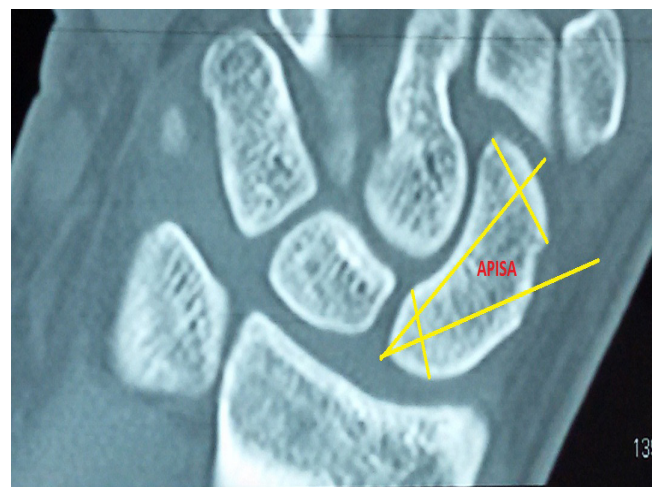

Figure 2. The anteroposterior intrascaphoid angle (APISA) was measured by the intersection of the two perpendicular lines drawn from the distal and proximal scaphoid articular surfaces on coronal CT cuts.

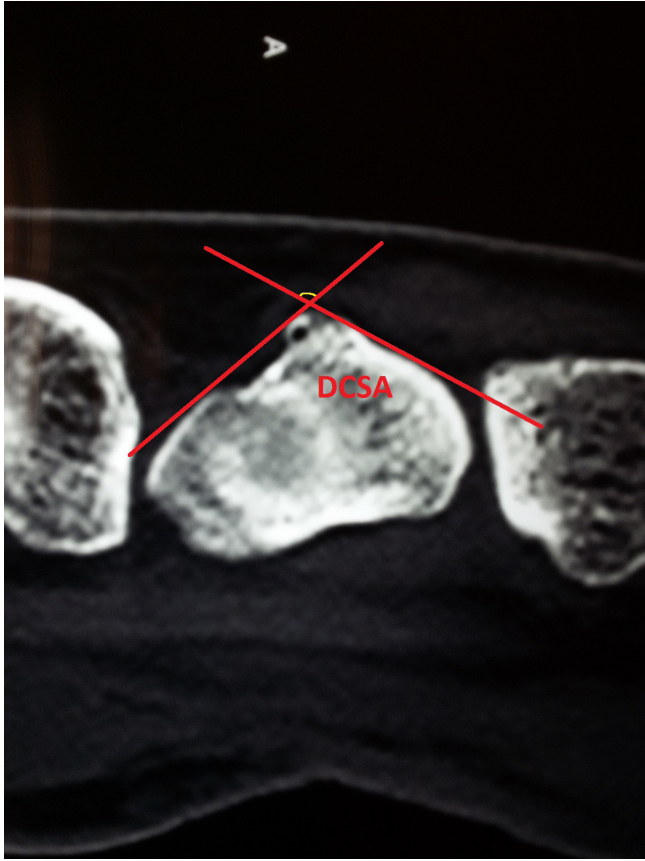


Figure 3. Measurement of the dorsal cortical angle (DSCA) on CT scan.

height-to-length ratio was 0.74 ± 0.04 . None of the patients had avascular necrosis on plain radiographs; however, all the patients had evidences of wrist osteoarthritis. There were no significant statistical correlation between the scaphoid radiologic measurements and Cooney wrist scores [Table 2].

Discussion

In the current study we determined the scaphoid morphological angles in the patients with reconstructed scaphoid by non-vascularized bone graft and investigated the correlation between the morphology of the reconstructed scaphoids with their clinical outcomes. Intrascaphoid malunion has a direct effect on the wrist kinematics. Increased lateral intrascaphoid angle produces "hump back" deformity of the scaphoid due to shortened volar cortex. A change in the morphology of the scaphoid affects the relations between the carpal bones and changes the intercarpal angles including: capitulate angle, radiolunate angle, scapholunate angle and produces the dorsal intercalated segmental instability (DISI) (1-12,16). The scaphoid humpback deformity may be evaluated by the three measurements of the lateral intrascaphoid angle, dorsal cortical angle and scaphoid height-to-length ratio on CT scan (17,18).

The standards for the measurement of the lateral

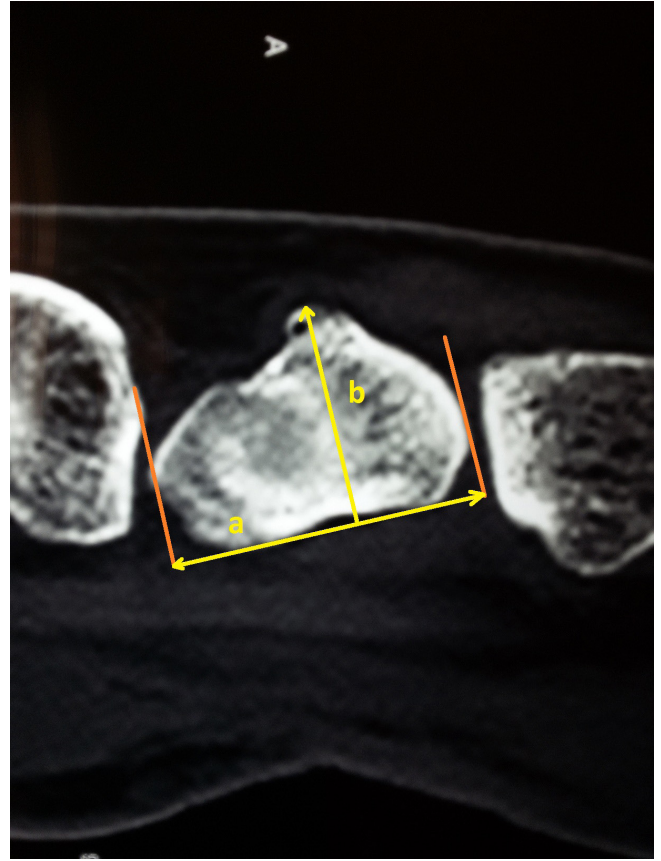


Figure 4. Measurement of the height-to-length ratio on CT scan.

and anteroposterior intrascaphoid angles are not well defined (15). In normal individuals Amadio et al. measured the lateral intrascaphoid angle 24 ± 5 degrees and anteroposterior intrascaphoid angle 40 ± 4 degrees (15). In the normal scaphoids of our study the mean lateral intrascaphoid angle was 34.8 ± 1.4 degrees and mean anteroposterior intrascaphoid angle was 33.4 ± 2.2 degrees.

Some authors have suggested that scaphoid malunion is associated with a poor clinical outcome (8,15). Scaphoid malunion has been considered when the lateral or anteroposterior intrascaphoid angles exceed the contralateral normal side; however, there is no consensus on what are the acceptable amounts of the scaphoid radiologic malunion angles (9,15,16).

Amadio et al. found a satisfactory clinical outcome in 83% of patients and post traumatic arthritis in 22% with good scaphoid alignment. But in the patients with lateral intrascaphoid angle more than 35 degrees there were 24% satisfactory clinical outcome and 54% post traumatic arthritis. Amadio et al. found that the measurement of the lateral intrascaphoid angle was the best discriminator of clinical outcome and a lateral intrascaphoid angle of 45 degrees was a cut off point for satisfactory and unsatisfactory outcomes (15). However, the lateral intrascaphoid angle has a poor

Table 1. The clinical outcomes and radiological measurements of the 17 patients

Case	Age/Sex	occupation	Operated side	Non-union time (months)	Follow up (months)	Lateral intrascaphoid angle (operated side/ normal side)	Antroposterior intrascaphoid angle (operated side/ normal side)	Dorsal cortical angle (operated side/ normal side)	scaphoid length (operated side/ normal side)	height / length (operated side/ normal side)	Final Pain (VAS Score)	post op Pain (MYO Score)	Functional status	Wrist's range of movement (percentages of normal side)	Grip strength (kg) (percentages of normal side)	Cooney score at final follow up
1	29/M	Accountant	R	12	20	37/34	34/40	156/144	22.5/22.5	0.69/0.62	0	None	Returned	170(85%)	50(100%)	90(Excellent)
2	42/M	Driver	R	12	72	39/30	28/31	172/136	21/24	0.86/0.63	0	None	Returned	160(84%)	55(106%)	90(Excellent)
3	45/M	Shopkeeper	R	60	71	34/30	34/38	150/138	21/22.5	0.71/0.62	0	None	Returned	180(92%)	47(112%)	90(Excellent)
4	32/M	Dentist	R	9	47	34/30	34/36	152/138	22.5/22.5	0.67/0.62	0	None	Returned	180(92%)	42(93%)	80(Good)
5	23/M	Shopkeeper	R	36	50	28/29	40/40	174/144	24/24	0.71/0.67	0	None	Returned	163(82%)	40(89%)	80(Good)
6	23/M	Worker	R	24	39	37/29	24/32	178/140	24/26.5	0.75/0.58	7	Moderate	Restricted	170(86%)	46(92%)	65(Fair)
7	29/M	Worker	L	18	31	32/26	31/39	158/142	19/23	0.95/0.7	0	None	Returned	180(86%)	25(100%)	90(Excellent)
8	45/M	Teacher	L	96	63	37/32	35/39	150/134	21.5/22.5	0.72/0.64	0	None	Returned	165(79%)	50(83%)	80(Good)
9	26/M	Civil engineer	L	24	46	36/34	40/40	148/136	21.5/21.5	0.7/0.65	0	None	Returned	195(89%)	55(138%)	90(Excellent)
10	28/M	Plumber	R	24	75	34/35	40/42	158/140	24/24	0.67/0.6	0	None	Returned	205(105%)	80(107%)	100(Excellent)
11	29/M	Electrician	R	12	23	36/34	38/40	148/140	22.5/22.5	0.71/0.67	0	None	Returned	185(95%)	40(89%)	80(Good)
12	41/M	Teacher	R	97	64	40/25	30/41	166/142	24/25.5	0.71/0.63	0	None	Returned	125(61%)	45(90%)	75(Fair)
13	35/M	Technician	L	24	48	36/32	35/40	148/137	22.5/23	0.69/0.63	0	None	Returned	160(80%)	30(55%)	75(Fair)
14	24/M	Shopkeeper	R	0.07	69	33/27	27/42	162/138	20/23	0.75/0.63	0	None	Returned	195(93%)	42(105%)	90(Excellent)
15	33/M	Bank Clerk	R	72	68	34/32	32/37	148/138	22.5/23	0.71/0.63	0	None	Returned	165(80%)	55(92%)	80(Good)
16	22/M	Businessman	R	2.5	24	34/32	35/37	154/136	22.5/22.5	0.71/0.64	0	None	Returned	165(92%)	40(89%)	80(Good)
17	27/M	Student	L	12	20	34/32	36/37	170/142	21/21	0.83/0.71	0	None	Returned	165(80%)	30(75%)	80(Good)

M: male

Operated side: R; right; L: left.

Wrist range of movement is the sum of flexion, extension, radial deviation and ulnar deviation movements.

Final pain, wrist range of movement and grip strength were evaluated at the final follow up examination.

Visual Analogue Scale (VAS) ranges from 0 to 10. (0, no pain; 1-3, mild pain; 4-6, moderate pain; 7- 10, severe pain).

The pain was graded as none, mild (occasional and on strenuous activity), moderate (tolerable and on light work), and severe (intolerable and unable to work because of pain) according to the Cooney wrist function score.

The functional status of the wrist was graded as: return to regular work, restriction in work, able to work but unemployed and unable to work because of pain.

Cooney's scores from 0 to 100 and the higher scores indicate more favorite outcome. (Excellent, 90-100; good, 80-90; fair 65-80; poor, 0-65).

reproducibility (17,19). Jiranek et al. also correlated their clinical findings with the lateral intrascaphoid angle. In their study there was no significant difference in the subjective results comprising function, pain, and decrease in performance among patients who had a lateral intrascaphoid angle more than 45 degrees and those who had no such deformity (20).

Lee et al. used the height-to-length ratio to measure scaphoid malunion and evaluated the midterm clinical outcomes of scaphoid malunions. In their study there was no significant difference between the malunited scaphoids and well-united scaphoids at a minimum 5-year follow-up (9).

Forward et al. classified scaphoids as the malunion group if their height-to-length ratios were more than 0.6, and compared with the union group that had a

height-to-length ratio of less than 0.6. There were no differences in the clinical scores between the two groups and there were no significant relationships between the clinical results and the radiologic parameters of scaphoid alignment such as height-to-length ratio, lateral intrascaphoid angle, and dorsal cortical angle in the short term (21).

Megerle et al. have found that the radiolunate angle as an indicator of carpal instability had a significant relationship with the clinical results of scaphoid malunion (3). In the current study we used the measurements of the scaphoid because we think that the other changes in wrist angles are secondary to the morphology of the scaphoid. All the patients had different radiological measurements from their normal sides; hence, all the patients had some degrees of malunion. However, in

Table 2. Correlation between the scaphoid radiologic measurements and Cooney wrist scores

Scaphoid radiologic measurements	Lateral intrascaphoid angle	Anteroposterior intrascaphoid angle	Dorsal cortical angle	Scaphoid lengths	Scaphoid height-to-length ratio
P values and r coefficients	P= 0.46, r =-0.19	P= 0.19, r = 0.33	P= 0.34, r = -0.24	P= 0.08, r =0.43	P= 0.64, r =0.12

our study, as well as several previous studies, there was no relationship between the radiologic parameters of scaphoid alignment and the clinical results (3,9).

In the current study, there were excellent, good, and fair clinical results among the 17 patients. The fair results in the patients with osseous union may be explained by the fact that the clinical results depend on multiple factors including the morphology of the scaphoid, presence or absence of initial chondral and ligamentous damages (1-12). The presence of the initial chondral and ligamentous damages are out of the control of the surgeons and the surgery itself may intensify the damages (1,2) In the current study all the patients had degrees of osteoarthritis in their wrist radiographs; however, radiological osteoarthritis does not necessarily correlate with clinical outcomes (1,2).

This study had several limitations. It was a retrospective and short term study. A large number of the patients were not available or had not given informed consent to participate in the study. The radiologic measurements were two-dimensional; therefore, the interpretation of the three dimensional patterns of scaphoid malunions were rough estimations. Further studies about the carpal kinematics with scaphoid malunion based on in vivo three-dimensional analysis are needed (11).

We can conclude that the clinical outcomes of the treatments for scaphoid nonunion depend on multiple

factors. The morphology of the reconstructed scaphoid because of nonunion may have a limited influence on the clinical outcome at short term follow-up. It is necessary to define an acceptable range of severity of scaphoid malunion that has little chance for progression to carpal instability and osteoarthritis (9).

Ahmadreza Afshar MD

Kian Zohrabi MD

Nasrin Navaeifar MD

Hassan Taleb MD

Department of Orthopedics, Urmia University of Medical Sciences, Urmia, Iran

Afshin Mohammadi MD

Department of Radiology, Urmia University of Medical Sciences, Urmia, Iran

Sam H. Sami MD

Department of Orthopedics, Shafa Yahyaian Hospital, Iran University of Medical Sciences, Tehran, Iran

References

- Barton NJ. The late consequences of scaphoid fractures. *J Bone Joint Surg Br.* 2004; 86(5):626-30.
- Barton NJ. Twenty questions about scaphoid fractures. *J Hand Surg Br.* 1992; 17(3):289-310.
- Megerle K, Harenberg PS, Germann G, Hellmich S. Scaphoid morphology and clinical outcomes in scaphoid reconstructions. *Injury.* 2012; 43(3):306-10.
- Hung LK. Scaphoid malunion. *J Orthop Surg (Hong Kong).* 2002; 6(2):104-8.
- Capito AE, Higgins JP. Scaphoid overstuffing: the effects of the dimensions of scaphoid reconstruction on scapholunate alignment. *J Hand Surg Am.* 2013; 38(12):2419-25.
- Buijze GA, Ochtman L, Ring D. Management of scaphoid nonunion. *J Hand Surg Am.* 2012; 37(5):1095-100.
- Dias JJ, Singh HP. Displaced fracture of the waist of the scaphoid. *J Bone Joint Surg Br.* 2011; 93(11):1433-9.
- Fisk GR. An overview of injuries of the wrist. *Clin Orthop Relat Res.* 1980; 149(6):137-44.
- Lee CH, Lee KH, Lee BG, Kim DY, Choi WS. Clinical outcome of scaphoid malunion as a result of scaphoid fracture nonunion surgical treatment: A 5-year minimum follow-up study. *Orthop Traumatol Surg Res.* 2015; 101(3):359-63.
- Sendher R, Ladd AL. The scaphoid. *Orthop Clin North Am.* 2013; 44(1):107-20.
- ten Berg PW, Dobbe JG, Strackee SD, Streekstra GJ. Quantifying Scaphoid malalignment based upon height-to-length ratios obtained by 3-dimensional computed tomography. *J Hand Surg Am.* 2015; 40(1):67-73.
- Watanabe K. Analysis of carpal malalignment caused by scaphoid nonunion and evaluation of corrective

- bone graft on carpal alignment. *J Hand Surg Am.* 2011; 36(1):10-6.
13. Green DP. The effect of avascular necrosis on Russe bone grafting for scaphoid nonunion. *J Hand Surg Am.* 1985; 10(5):597-605.
 14. Cooney WP, Bussey R, Dobyns JH, Linscheid RL. Difficult wrist fractures; perilunate fracture-dislocation of the wrist. *Clin Orthop Relat Res.* 1987; 214(3):136-47.
 15. Amadio PC, Berquist TH, Smith DK, Ilstrup DM, Cooney WP 3rd, Linscheid RL. Scaphoid malunion. *J Hand Surg Am.* 1989; 14(4):679-87.
 16. Fernández DL, Martin CJ, González del Pino J. Scaphoid malunion. The significance of rotational malalignment. *J Hand Surg Br.* 1998; 23(6):771-5.
 17. Bain GI, Bennett JD, MacDermid JC, Slethaug GP, Richards RS, Roth JH. Measurement of the scaphoid humpback deformity using longitudinal computed tomography: intra- and interobserver variability using various measurement techniques. *J Hand Surg Am.* 1998; 23(1):76-81.
 18. El-Karef EA. Corrective osteotomy for symptomatic scaphoid malunion. *Injury.* 2005; 36(12):1440-8.
 19. Ring D, Patterson JD, Levitz S, Wang C, Jupiter JB. Both scanning plane and observer affect measurements of scaphoid deformity. *J Hand Surg Am.* 2005; 30(4):696-701.
 20. Jiranek WA, Ruby LK, Millender LB, Bankoff MS, Newberg AH. Long-term results after Russe bone-grafting: the effect of malunion of the scaphoid. *J Bone Joint Surg Am.* 1992; 74(8):1217-28.
 21. Forward DP, Singh HP, Dawson S, Davis TR. The clinical outcome of scaphoid fracture malunion at 1 year. *J Hand Surg Eur Vol.* 2009; 34(1):40-6.