

# Case Report: Scleral Metastasis of Esophageal Squamous Cell Carcinoma

Rahim Mahmoodlou · Fahimeh Asadi Amoli · Ata Abbasi ·  
Seyed Arman Seyed Mokhtari · Sajjad Pourasghary

Received: November 5, 2017  
© The Author(s) 2018. This article is an open access publication

## ABSTRACT

In this report, a case of ocular scleral metastasis was reported in a patient with a past history of esophageal squamous cell carcinoma. The patient was a 58-year-old male who was admitted to Urmia Imam Khomeini Hospital, Urmia, Iran, 8 years ago with progressive dysphasia. Seven years after initial diagnosis and treatment of esophageal cancer, the patient had no signs or symptoms of the disease. But 2 months ago, he was referred to the hospital due to ocular swelling, redness and watering. Pathologic

examination of the excised lesion at Farabi Hospital reported metastasis of squamous cell carcinoma to the connective tissue of the sclera.

**Keywords:** Iran; Metastasis; SCC; Scleral

## INTRODUCTION

Esophageal cancer is a highly aggressive neoplasm, with a common metastases pattern of the adjacent lymph nodes, the lung and also the liver. However, ophthalmic metastasis is very rare and is associated with a very weak prognosis [1]. Unless considerable involvement of the globe is present, such instances of metastases tend to remain unnoticed [2]. Most metastatic cancers to the globe usually occur in the posterior segments of the optic cavity, often behind the iris and the cornea; according to previous studies, metastases to the sclera are very rare [3–5]. Ocular metastases generally account for 1–13% of total reported eye tumors. According to literature, only four cases of ocular metastasis of esophageal origin have been reported, two of which were squamous cell carcinoma (SCC) and the rest were esophageal adenocarcinomas [6]. In this report, a case of ocular scleral metastasis was reported in a patient with a past history of esophageal SCC. Informed consent was obtained from the participant as permission to author this report.

---

**Enhanced content** To view enhanced content for this article, go to <http://www.medengine.com/Redeem/OD1DF06022F19868>.

---

R. Mahmoodlou  
Department of General Surgery, Urmia University of  
Medical Sciences, Urmia, Iran

F. Asadi Amoli  
Department of Pathology, Tehran University of  
Medical Sciences, Tehran, Iran

A. Abbasi  
Department of Pathology, Urmia University of  
Medical Sciences, Urmia, Iran

S. A. Seyed Mokhtari · S. Pourasghary (✉)  
Student Research Committee, Urmia University of  
Medical Sciences, Urmia, Iran  
e-mail: sajadpourasghary96@gmail.com

## CASE REPORT

The patient was a 58-year-old male who was admitted to Urmia Imam Khomeini Hospital, Urmia, Iran, 8 years ago with progressive dysphasia. The patient underwent upper gastrointestinal (GI) endoscopy which revealed an ulcerative esophageal mass, approximately 30 cm from the incisors. Biopsies were taken from the lesion and the pathologic diagnosis of the lesion revealed SCC. The patient underwent total esophagectomy without thoracotomy surgery. After surgery, the patient received 20 sessions of standard chemotherapy with fluorouracil (5-FU) and cisplatin.

Seven years after initial diagnosis and treatment of esophageal cancer, the patient had no signs or symptoms of the disease. However, 2 months ago, he was referred to the hospital following ocular swelling, redness and excessive watering. Systemic and ophthalmologic examinations revealed no abnormal findings. Examination of the globe by an ophthalmologist revealed a 1 × 1-cm mass in the nasal sclera of the left eye. The patient's field of vision and visual acuity were normal. Intraocular pressure in both sides as well as the slit lamp test were also normal. On the nasal side of the cornea of the left eye, a considerable mass with vascular engorgement and scleral attachment was observed. Biopsy was obtained from the lesion for pathologic evaluation. MRI without contrast of the orbit is presented in Fig. 1. Since PET scans are solely available in Tehran, it was not possible to perform this method of imaging on the current patient.

## PATHOLOGIC EXAMINATION

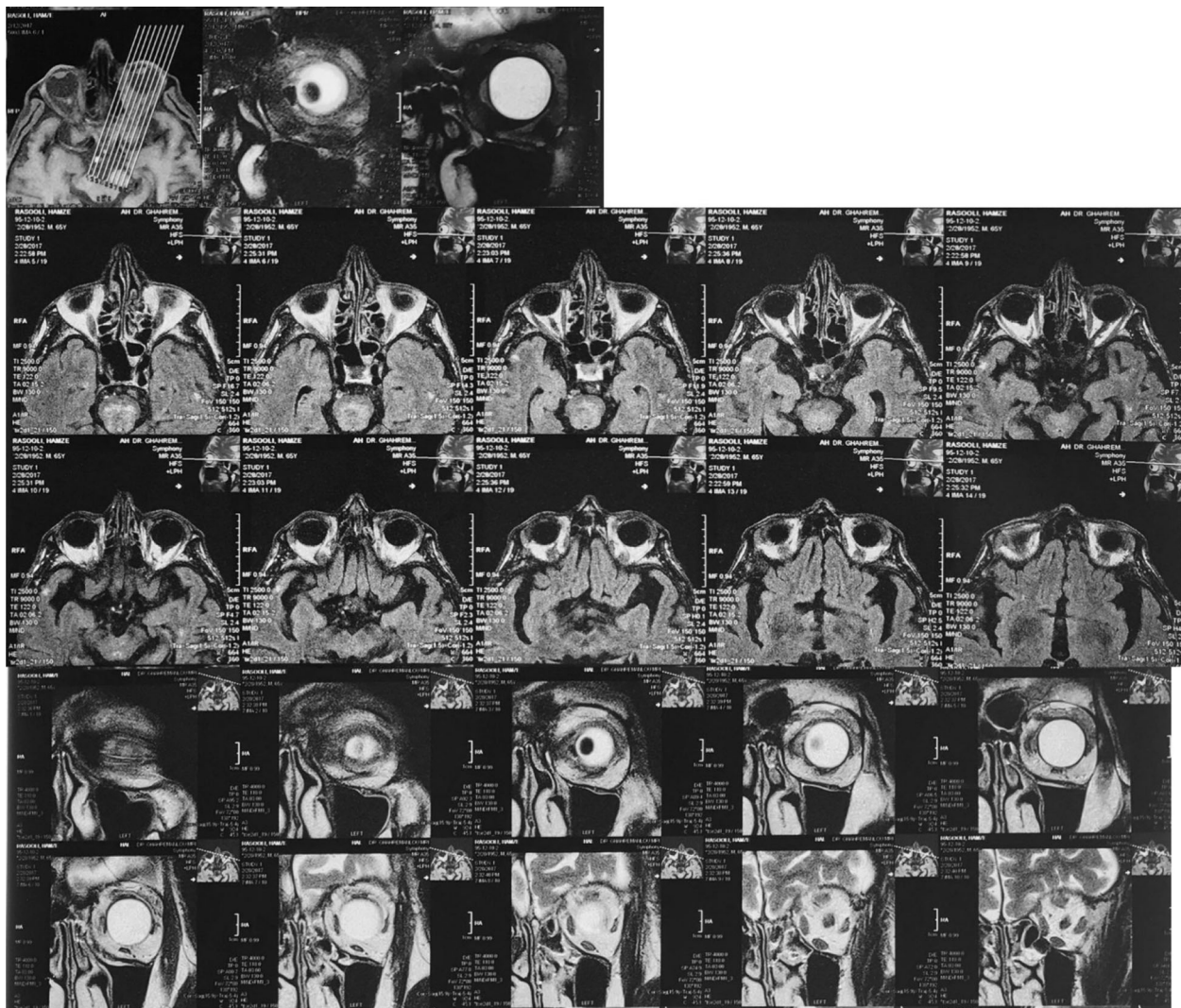
Microscopic evaluation of the ocular lesion biopsy specimen revealed nests of atypical squamous cells with nuclear enlargement and atypia, prominent nucleoli and various mitotic figures with infiltration into the sub-epithelial area (SCC; Fig. 2). The overlying squamous epithelium was unremarkable. For

complementary examinations, the patient was referred to Farabi Hospital, Tehran, Iran, and a referral eye center in the region. At that center, surgery was performed to excise the conjunctiva and cornea of the left eye. Pathologic examination of the excised lesion at Farabi Hospital also reported metastasis of SCC to the connective tissue of the sclera.

## DISCUSSION

Unlike metastases in the intraocular cavity, metastasis to the sclera is one of the rarest cases of systemic cancer metastases, accounting for 1–13% of all eye cancers [7]. However, predicting the incidence of these cancers is challenging. In recent years, the incidence of ocular metastasis has increased due to improved treatment methods of systemic cancers, as well as the development of novel diagnostic equipment, which have also increased survival rates [8]. Most of metastatic carcinomas to the eye arise from the lung, breasts and prostate [9], and metastases originating from the GI tract account for only 6–7% of all reported cases. According to the literature, there are only four reported cases of ocular metastasis of GI origin [6, 10].

The main initial symptoms of ocular involvement include double vision, eye protrusion, loss of visual acuity and field, pain and watering which may show a progressive pattern or have an acute onset [11]. The main goal in treating eye metastasis is to relieve the patient's discomfort. The treatment of ocular metastases includes radiotherapy, chemotherapy, laser surgery, anti-vascular endothelial growth factor administration and finally eye enucleation. Enucleation is not recommended in the early stages and should be considered as a last resort [12]. Regardless of the type of primary tumor, survival of patients with a metastatic ocular lesion is very weak. In a recent study, the mean and the 2-year survival rates were 1.3 and 27%, respectively. No significant relationship has been found between patient survival and



**Fig. 1** Orbit MRI without contrast (1.5T MRI, ^ channel coil). A heterogeneous mass, about  $15 \times 12$  mm, can be seen in the pre-septal space of the medial part of the left orbit with extension to the medial rectus muscle

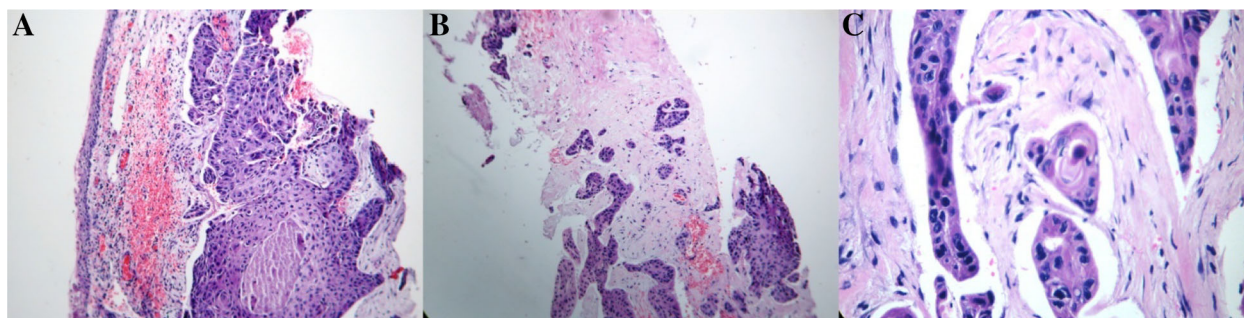
primary tumor type [13]. In another study, mean survival rate was 7.4 months [14].

## CONCLUSION

In this paper, we reported a patient with a previous history of esophageal cancer 7 years ago, which had now presented with ocular

metastasis. Ocular metastasis of a GI origin is a very rare phenomenon and can be a challenging clinical situation, which also highlights the fact that physicians should be very aware of patients' medical history and consider "metastasis" as an important differential diagnoses in patients with a history of malignancy, whether in the near or distant past.





**Fig. 2** a, b Connective tissue with infiltration of malignant squamous cells (squamous cell carcinoma, SCC) in the sub-epithelial area without involvement of surface

epithelium (H&E,  $\times 10$ ). c Higher magnitude of the previous figures showing SCC infiltration with large hyperchromatic nuclei within stroma (H&E,  $\times 40$ )

## ACKNOWLEDGEMENTS

**Funding.** No funding or sponsorship was received for this study or publication of this article.

**Authorship.** All named authors meet the International Committee of Medical Journal Editors (ICMJE) criteria for authorship for this article, take responsibility for the integrity of the work as a whole and have given their approval for this version to be published.

**Disclosures.** Rahim Mahmudlou, Fahimeh Asadi Amoli, Ata Abbasi, Seyed Arman Seyed Mokhtari and Sajjad Pourasghary have nothing to disclose.

**Compliance with Ethics Guidelines.** Informed consent was obtained from the participant for being included in the case report.

**Open Access.** This article is distributed under the terms of the Creative Commons Attribution-NonCommercial 4.0 International License (<http://creativecommons.org/licenses/by-nc/4.0/>), which permits any noncommercial use, distribution, and reproduction in any medium, provided you give appropriate credit to the original author(s) and the source, provide a link to the Creative Commons license, and indicate if changes were made.

## REFERENCES

1. Kato H, Nakajima M. Treatments for esophageal cancer: a review. *General Thorac Cardiovasc Surg.* 2013;61(6):330–5.
2. Shields JA, Shields CL, Kiratli H, Potter PD. Metastatic tumors to the iris in 40 patients. *Am J Ophthalmol.* 1995;119(4):422–30.
3. Freedman MI, Folk JC. Metastatic tumors to the eye and orbit: patient survival and clinical characteristics. *Arch Ophthalmol.* 1987;105(9):1215–9.
4. Bloch RS, Gartner S. The incidence of ocular metastatic carcinoma. *Arch Ophthalmol.* 1971;85(6):673–5.
5. Freedman MI, Folk JC. Metastatic tumors to the eye and orbit: patient survival and clinical characteristics. *Ophthalmic Plast Reconstr Surg.* 1988;4(3):180.
6. Lee JY, Lee HJ, Jung MS, Kim SY. Metastatic esophageal squamous cell carcinoma to the orbit and periorbit masquerading as periorbital abscess. *Korean J Ophthalmol KJO.* 2010;24(2):123–5.
7. Ahmad SM, Esmali B. Metastatic tumors of the orbit and ocular adnexa. *Curr Opin Ophthalmol.* 2007;18(5):405–13.
8. Dieing A, Schulz CO, Schmid P, Roever AC, Lehenbauer-Dehm S, Jehn C, et al. Orbital metastases in breast cancer: report of two cases and review of the literature. *J Cancer Res Clin Oncol.* 2004;130(12):745–8.
9. Goldberg RA, Rootman J, Cline RA. Tumors metastatic to the orbit: a changing picture. *Surv Ophthalmol.* 1990;35(1):1–24.

10. Font RL, Ferry AP. Carcinoma metastatic to the eye and orbit III. A clinicopathologic study of 28 cases metastatic to the orbit. *Cancer*. 1976;38(3):1326–35.
11. Moss HM. Expanding lesions of the orbit. A clinical study of 230 consecutive cases. *Am J Ophthalmol*. 1962;54:761–70.
12. Giuliari GP, Sadaka A. Uveal metastatic disease: current and new treatment options. *Oncol Rep*. 2012;27(3):603–7 (Review).
13. Char DH, Miller T, Kroll S. Orbital metastases: diagnosis and course. *Br J Ophthalmol*. 1997;81(5):386–90.
14. Ferry AP, Font RL. Carcinoma metastatic to the eye and orbit. I. A clinicopathologic study of 227 cases. *Arch Ophthalmol*. 1974;92(4):276–86 (Chicago, Ill: 1960).