

Hematoma Block Versus General Anesthesia in Distal Radius Fractures in Patients Over 60 Years in Trauma Emergency

Ali Tabrizi,^{1,*} Fardin Mirza Tolouei,¹ Ebrahim Hassani,² Hassan Taleb,³ and Asghar Elmi⁴

¹Orthopedics Surgery Department, Imam Khomeini Hospital, Urmia University of Medical Sciences, Urmia, Iran

²Department of Anesthesiology, Imam Khomeini Hospital, Urmia University of Medical Sciences, Urmia, Iran

³Orthopedics Surgery Department, Imam Khomeini Hospital, Urmia University of Medical Sciences, Urmia, Iran

⁴Orthopedics Surgery Department, Shohada Educational Hospital, Tabriz University of Medical Sciences, Tabriz, Iran

*Corresponding author: Ali Tabrizi, Orthopedics Surgery Department, Imam Khomeini Hospital, Urmia University of Medical Sciences, Urmia, Iran. Tel: +98-9143130829, E-mail: Ali.tab.ms@gmail.com

Received 2016 July 04; Revised 2016 October 31; Accepted 2016 November 22.

Abstract

Background: Distal radius fractures are among common fractures in the elderly. Regarding the age, background diseases, and possible risks, analgesia method is of great importance in this group.

Objectives: The aim of this study was to compare two analgesia methods including hematoma block and general anesthesia in people over 60 years in the orthopedic emergency department.

Methods: 68 elderly patients referring to the emergency department of a medical teaching center were selected based on the inclusion criteria for a non-randomized clinical trial. The patients were placed in two groups of 34, which were matched for age and sex. Hematoma block was used as the analgesic method in one group and general anesthesia was used in the other group. These two groups were compared for pain intensity, analgesia duration, and anesthesia side effects. The SPSS software (Statistical Package for the Social Sciences, version 17.0, SPSS Inc., Chicago, Ill, USA) was used for data analysis.

Results: 68 elderly patients (mean age of 70.3 ± 6.6) with a dislocated distal radius fracture which required closed reduction were examined. The duration of manipulation and surgery and discharging time were significantly different between two groups and they were all lower in the hematoma blocked group. Pain intensity evaluation indicated a statistically significant difference during initial hours after fracture reduction and fixation so that pain intensity was less in elderly patients under hematoma block than patients who underwent general anesthesia in one and six hours after surgery. Need for narcotic was 35.2% in the general anesthesia group which also showed a significant between-group difference.

Conclusions: Hematoma block analgesia used in distal radius fractures of the elderly is a very safe and effective method that seems preferable to general anesthesia in emergency departments.

Keywords: Distal Radius Fractures, General Anesthesia, Hematoma Block

1. Background

Distal radius fractures are of most common fractures resulting from osteoporosis among old women and men (1). The occurrence of these fractures in ages over 70 increases a lot and makes 18% of total fractures. Age and sex are two important predictive factors of distal radius fractures (1, 2). These fractures occur mostly in old women with low energy trauma (3, 4). Based on existing reports, the risk of distal radius fractures in ages over 60 is 15% and 2% in women and men, respectively. Distal radius fractures in adults are treated through manipulation and reduction in emergency departments (3, 4).

Different methods are used to induce analgesia to reduce the patient's pain during treatment interventions. These methods include intravenous regional anesthesia (IV RA), demand-valve nitrous oxide, hematoma block, intramuscular sedation, conscious sedation, and general anesthesia (5).

There are some risks accompanied by each of these analgesic methods. Drug-induced reactions and background heart diseases endanger patients undergoing all

anesthesia methods. Hematoma block method is used rarely in emergency departments while general anesthesia and conscious sedation are often utilized for distal radius fractures manipulation. Hematoma block in children has been associated with good outcomes. In a late study by Bear et al. (6), the use of hematoma block for the reduction of pediatric distal radius fractures provided good radiographic alignment, patient satisfaction, and pain control compared to procedural sedation and could significantly decrease procedural sedation time and resources. However, this method has not been studied among the elderly while it is important for elderly people with several underlying diseases to use appropriate anesthesia methods. Performing general anesthesia and sedation is accompanied by more risks in people over 60 who have different systemic diseases (3, 4).

2. Objectives

Therefore, the aim of this study was to compare hematoma block with general anesthesia and sedation in

over 60 patients with distal radius fractures.

3. Methods

A total of 68 patients over 60 years with displaced distal radius fracture who needed manipulation were examined in a non-randomized clinical trial during 2014 - 2015 at Imam Khomeini hospital affiliated to Urmia University of Medical Sciences, Urmia, Iran. The criteria for selecting patients included presence of isolated displaced distal radius fracture, absence of trauma in other regions, absence of deformity and previous fractures in distal radius, and the age of over 60. Addicted and alcoholic people and those who had been diagnosed with coagulopathy, respiratory disease, and lung disease were excluded from the study. These patients were categorized into two groups which were matched for age, sex, and fracture type. All these patients had the indication for distal radius fracture treatment by manipulation and percutaneous pinning. Hematoma block was used in one group for analgesia.

Patient's history was taken before anesthesia and previous diseases were examined. Venous catheter was placed for all patients and they were all monitored for the heart function. Vital signs stability was evaluated in terms of pulse rate, respiratory rate, blood pressure, and oxygen saturation. The patients in the general anesthesia group were qualified to meet American society of anesthesiologists criteria of physical status 1&2. General anesthesia was induced in all patients using propofol 1.5 - 2 mg/kg, and fentanyl 1 - 2 mg/kg, while sevoflurane (1% - 1.5%) and N₂O (66%) in-oxygen was applied during general anesthesia. In hematoma block method, 10 mL of lidocaine 1% was injected into the fracture after aspiration of fracture hematoma. 10 mL of lidocaine 1% was injected into styloid radius and ulnar side as pinning locations. The maximum dose of 5 mg/kg was used for patients. The area had been sterilized using povidone iodine 7.5% before injection. All patients observed fasting conditions for at least 8 hours. Manipulation intervention and pinning were carried out 15 minutes after hematoma block. 1.5 mm pins, two from radial side and one from ulnar side, were used to fix the fractures, and immobilization by cast was performed for all the patients. For the patients in the control group, acetaminophen-codeine tablets (Acetaminophen 500 mg/hydrocodone 5 mg) were prescribed for the pain after surgery, and 25 mg intravenous Pethidine was injected in case of severe pain. Pain intensity in patients was graded based on visual analogue scale (VAS) defined by Hawker et al., in which the score 0 shows no pain and the score 10 indicates the worst imaginable pain. Sleep disturbance within 24 hours before the day of hospitalization

was also described using a 10-point scale in which the score 0 meant no sleep disturbance and the score 10 indicated the greatest sleep disturbance. VAS-based pain grades were recorded one hour after surgery and continued every 6 hours until 24 hours.

The study was conducted based on the considerations of the ethics committee of Urmia University of Medical sciences. Before starting the study, informed consent was obtained from every patient. This study has been submitted in IRCT (Iranian randomized clinical trial) numbered IRCT201608199857N3.

3.1. Statistical Methods

Frequency, percentage, and mean \pm standard deviation were used as descriptive statistics. In order to compare the qualitative data between two groups, Chi-square or Fisher's exact test was used, and in the case of quantitative data, the distribution normality was first tested in two groups and then, independent T-test was utilized for making comparisons. Besides, the repeated measures test was used in the case of repeated-measures quantitative data. The SPSS software (Statistical Package for the Social Sciences, version 17.0, SPSS Inc., Chicago, Ill, USA) was used for data analysis and $P < 0.05$ was considered to be statistically significant.

4. Results

68 elderly patients (mean age of 70.3 ± 6.6 years) with displaced distal radius fracture who needed closed reduction were studied. These patients were placed in two groups of 34 patients. The patients' demographic findings are shown in [Table 1](#). The two groups were matched for age, sex, and other concurrent diseases so that the analyses showed there were no significant differences between the groups in terms of these cases. The comparison of pain during initial hours after fracture reduction demonstrated significantly less pain intensity in the group that was under treatment by hematoma block ($P < 0.001$). According to [Figure 1](#), pain was less intense during the first hours in the hematoma block group, but there is no between-group difference in pain after 24 hours.

Sleep disturbance assessment in patients after reduction and fixation in the group undergoing hematoma block on day one after surgery gave the average score of 2.7 ± 1.5 , while in the general anesthesia group this score was 6.6 ± 0.8 ; these data showed a significant difference between the two groups in sleep disturbance ($P = 0.001$). The measurement of side effects including nausea and vomiting after surgery showed also significant differences. In 6 of hematoma blocked patients (17.6%), nausea and vomiting were seen. In contrast, these signs occurred in 19 cases

of general anesthesia group (55.8%), which showed a significant between-group difference ($P = 0.03$). According to Table 2, manipulation duration was not significantly different between the two methods, but hospitalization duration was significantly less in hematoma block method and the patients who underwent with this technique were discharged in a short time. Loss of reduction was the same between the two groups and there were no observable differences. Other side effects of surgery did not show any between-group difference. Five patients in the general anesthesia group required hospitalization in intensive care unit because of heart problems after surgery. On the other hand, none of the patients in hematoma block group needed to be hospitalized in intensive care unit. In hematoma blocked patients, there was no infection or compartment syndrome. In the case of two patients (5.8%), despite hematoma block was done like other patients, complete analgesia was not induced. Therefore, general anesthesia was used because they were unable to endure the pain and reduction state.

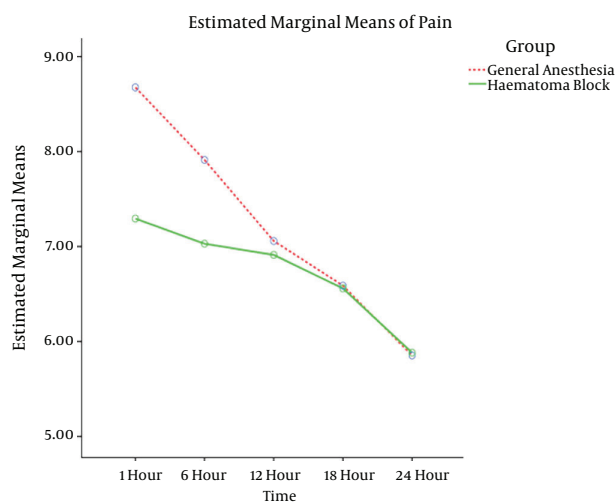


Figure 1. Comparison of Changes of Pain Intensity Scores at Different Time Points Between Two Hematoma Block and General Anesthesia Methods

5. Discussion

Pain control is achieved by different methods in patients with distal radius fracture referring to emergency departments to receive analgesia for manipulation and fixation. Regarding background diseases, general anesthesia is accompanied by concerns about its side effects (3, 4). Evaluation and comparison of various methods have been performed in previous studies on people with distal radius fracture, but elderly people are of special impor-

tance. An analgesia method which is easy, efficient, and requires short hospitalization is especially important for the elderly (1-5). There are concerns about the safety of analgesia methods. There is as much chance of infection, local anaesthetic toxicity, and compression by volume of local anaesthetic leading to compartment syndrome; thus, little attention has been paid to hematoma block (7). However, the probability of such events is very low, and these side effects have been reported for special occasions. Basu et al. (8) reported a 74 year old lady with osteomyelitis who had fracture reduction under hematoma block. Erik et al. (9) reported a case of Lidocaine toxicity following hematoma block after they used 10 ml of 2% Lidocaine in a 94 year old, 40 kg woman. Meinig et al. (10, 11) measured venous plasma levels of lidocaine in eight patients following fracture hematoma block and showed high systemic concentrations of lidocaine near to toxic thresholds in plasma. Younge (11) has reported a case of compartment syndrome following hematoma block for wrist fracture. But no complication was observed in the patients studied in our study. Depending on the type of treatment including reduction and percutaneous fixation, these effects are likely to occur in patients under general anesthesia. Except for the blood toxicity by Lidocaine, the other side effects are not dedicated to hematoma block anesthesia.

Today, the local anesthesia is used in orthopedic interventions (12). Funk (13) have compared general anesthesia and hematoma block in 40 people and showed that patients under hematoma block experienced pain during manipulation while patients under general anesthesia had no pain. In another study by Myderrizi and Mema (5), there has not been any remarkable difference between two methods in pain intensity after hematoma block and 15 minutes waiting for analgesic effect induction. It should be noted that surgery duration showed a significant difference between the two groups in our study. We also waited long enough for analgesia to be induced in the elderly patients in the current research based on a previous study, so that no noticeable difference was observed between two methods during the surgery. One of the positive points in hematoma block is that it allows the analgesia to be continued after the surgery because according to our findings in this study, patients in the general anesthesia group had experienced severe pain after complete consciousness and needed more analgesics. On the contrary, patients undergoing hematoma block required fewer analgesic drugs after the first analgesia.

The oldest study on this subject was conducted by Kendall et al. in 1997 in which 72 patients with distal radius fracture undergoing surgery by hematoma block or Bier's block were evaluated. They showed that analgesia through Bier's block method resulted in better outcomes

Table 1. Comparison of Demographic Characteristics Between Hematoma Block Group and General Anesthesia Group in Elderly Patients With Distal Radius Fracture

Variable	Hematoma Block Group	General Anesthesia Group	P Value
Age, y	73.7 ± 9.6	74.6 ± 10.8	0.2
Sex (male/female)	15.19	14.2	0.1
Heart disease	14 (41.1)	15 (44.1)	0.5
Diabetes	18 (51.4)	16 (47)	0.1
Respiratory disease	3 (8.8)	2 (5.8)	0.8

Table 2. Comparison of Hospitalization Duration and Side Effects Between Hematoma Block and General Anesthesia Groups in Elderly Patients Undergoing Surgery Treatment for Distal Radius

Variable	Hematoma Block Group	General Anesthesia Group	P Value
Manipulation duration (minute)	4.5 ± 2.6	4.8 ± 2.3	0.1
Surgery duration (minute)	16.5 ± 9.4	34.3 ± 6.5	0.02
Hospitalization duration (day)	1.2 ± 1.1	2.5 ± 2.3	0.01
Need for ICU	-	5 (14.7)	0.04
Loss of reduction	8 (23.5)	10 (29.4)	0.6

and the mean pain intensity during surgery in patients under Bier's block showed a significant difference compared to patients under hematoma block; however, in that study, there had not been sufficient time to induce local analgesia in hematoma block technique; thus, patients experienced a little pain during manipulation (14, 15). Eventually, they reported no difference between the two methods based on the final results. Since none of those methods needed general anesthesia, there has not been any special side effect for them. It is noteworthy that Bier's block method is technically more difficult and requires suitable education and also is more time consuming.

In a similar study performed by Funk et al. (13), results did not demonstrate any functional difference between hematoma block and general anesthesia. A study carried out by Kendall indicated that efficiency of hematoma block method in reducing Colles fracture resulted in an increase in the popularity of this analgesia method from 7% in 1989 to 24% in 1994. Additionally, the findings of a study performed by Handoll et al. (16) in 2002 indicated the safety of this method in the emergency departments and traumatic patients and revealed that this technique has had much less risk compared to general anesthesia in the emergency departments (16). Hematoma block has been even a completely safe and effective method to induce analgesia in tarsal fractures (8). In pediatric forearm fracture reduction, according to the Constantine et al. (17) study, the use of a hematoma block as an adjunct to procedural sedation with ketamine and midazolam for forearm fracture reduc-

tion conferred no additional benefit and did not decrease observed pain scores, excess sedation time, or total ketamine dose administered. On the contrary, the findings of our study represented the high benefit of hematoma block relative to general anesthesia in older patients. In Shaik et al. (18) study, failure rate of hematoma block was 10.5% and block failure rate was significantly high in lower limb fractures (19.5%) when compared to upper limb fractures (4.05%). Similar to our findings in this study, intolerance of hematoma block analgesia was 5.8%. In the study of Jafarian et al. (19), a modified Bier's block method versus the traditional one performed on patients undergoing surgery of upper limb bones showed considerable pain relief at surgical and tourniquet sites during the operation until one hour thereafter. In another study by Jafarian et al. (20), pneumatic arm tourniquet as an adjunct to intravenous regional anesthesia (IVRA) provided acceptable analgesia, especially in the elderly, although it needs to be more considered in future studies. However, it should be noted that it is technically more difficult and time-consuming for emergencies.

In the latest study by Myderrizi and Mema in 2011 (5) conducted on patients with distal radius fractures, hematoma block was safer and more efficient than general anesthesia and intravenous injection of anesthesia drugs for closed reduction of distal radius fracture although treatment failure was not different between two methods. In the study of Fathi et al. (21) regarding pain control in acute distal radial fracture reduction, ultrasound guided

haematoma block was recognized as a safe and effective method compared to procedural sedation and analgesia. Four patients (5.5%) in the procedural sedation and analgesia group showed early adverse effects. In this study, however, there was not any late complication.

Also, in the current study, which has focused on the elderly for the first time, hematoma block was identified as an effective analgesic method for treating distal radius fractures in old people and benefited them with the reduced hospitalization time. Besides, continuation of analgesia for some hours after fracture reduction is one of the strong points of hematoma block as confirmed in our study which in turn decreases the need for various analgesic drugs after being discharged from emergency operation room. This feature distinguished hematoma block method significantly from general anesthesia method. Moreover, interference with background diseases which are common among the elderly was not occurred with this method.

5.1. Limitation of Study

There were physical differences among patients. Also, obesity was a reason for failure in hematoma block analgesia. In these patients, we would have to use general anesthesia. Thus, obese patients were excluded from the study. Another limitation of the study was the patients' intolerance of fracture reduction and fixation in operation room despite complete analgesic in hematoma block method. It could be due to differences in individuals' mental health.

5.2. Conclusion

Hematoma block analgesia is a very safe and effective method in distal radius fractures of old people and seems to be superior to general anesthesia in emergency departments.

Footnote

Funding/Support: This study was financially supported by Urmia University of Medical Sciences.

References

- Oyen J, Diamantopoulos AP, Haugeberg G. Mortality after distal radius fracture in men and women aged 50 years and older in southern Norway. *PLoS One*. 2014;**9**(11):112098. doi: [10.1371/journal.pone.0112098](https://doi.org/10.1371/journal.pone.0112098). [PubMed: [25380128](https://pubmed.ncbi.nlm.nih.gov/25380128/)].
- Cummings SR, Melton LJ. Epidemiology and outcomes of osteoporotic fractures. *Lancet*. 2002;**359**(9319):1761-7. doi: [10.1016/S0140-6736\(02\)08657-9](https://doi.org/10.1016/S0140-6736(02)08657-9). [PubMed: [12049882](https://pubmed.ncbi.nlm.nih.gov/12049882/)].
- Bartl C, Stengel D, Bruckner T, Gebhard F. The treatment of displaced intra-articular distal radius fractures in elderly patients. *Dtsch Arztebl Int*. 2014;**11**(46):779-87.
- Padegimas EM, Osei DA. Evaluation and treatment of osetoporotic distal radius fracture in the elderly patient. *Curr Rev Musculoskelet Med*. 2013;**6**(1):41-6. doi: [10.1007/s12178-012-9153-8](https://doi.org/10.1007/s12178-012-9153-8). [PubMed: [23329371](https://pubmed.ncbi.nlm.nih.gov/23329371/)].
- Myderrizi N, Mema B. The hematoma block an effective alternative for fracture reduction in distal radius fractures. *Med Arh*. 2011;**65**(4):239-42. doi: [10.5455/medarh.2011.65.239-242](https://doi.org/10.5455/medarh.2011.65.239-242). [PubMed: [21950232](https://pubmed.ncbi.nlm.nih.gov/21950232/)].
- Bear DM, Friel NA, Lupo CL, Pitetti R, Ward WT. Hematoma block versus sedation for the reduction of distal radius fractures in children. *J Hand Surg Am*. 2015;**40**(1):57-61. doi: [10.1016/j.jhsa.2014.08.039](https://doi.org/10.1016/j.jhsa.2014.08.039). [PubMed: [25306504](https://pubmed.ncbi.nlm.nih.gov/25306504/)].
- Alioti RJ, Furia JP, Marquardt JD. Hematoma block for ankle fractures: a safe and efficacious technique for manipulations. *J Orthop Trauma*. 1995;**9**(2):113-6. doi: [10.1097/00005131-199504000-00004](https://doi.org/10.1097/00005131-199504000-00004). [PubMed: [7776029](https://pubmed.ncbi.nlm.nih.gov/7776029/)].
- Basu A, Bhalaik V, Stanislas M, Harvey IA. Osteomyelitis following a haematoma block. *Injury*. 2003;**34**(1):79-82. doi: [10.1016/S0020-1383\(02\)00087-6](https://doi.org/10.1016/S0020-1383(02)00087-6). [PubMed: [12531382](https://pubmed.ncbi.nlm.nih.gov/12531382/)].
- Dorf E, Kuntz AF, Kelsey J, Holstege CP. Lidocaine-induced altered mental status and seizure after hematoma block. *J Emerg Med*. 2006;**31**(3):251-3. doi: [10.1016/j.jemermed.2005.12.021](https://doi.org/10.1016/j.jemermed.2005.12.021). [PubMed: [16982355](https://pubmed.ncbi.nlm.nih.gov/16982355/)].
- Meinig RP, Quick A, Lobmeyer L. Plasma lidocaine levels following hematoma block for distal radius fractures. *J Orthop Trauma*. 1989;**3**(3):187-91. doi: [10.1097/00005131-198909000-00001](https://doi.org/10.1097/00005131-198909000-00001). [PubMed: [2809817](https://pubmed.ncbi.nlm.nih.gov/2809817/)].
- Younge D. Haematoma block for fractures of the wrist: a cause of compartment syndrome. *J Hand Surg Br*. 1989;**14**(2):194-5. doi: [10.1016/0266-7681\(89\)90124-1](https://doi.org/10.1016/0266-7681(89)90124-1). [PubMed: [2746120](https://pubmed.ncbi.nlm.nih.gov/2746120/)].
- Safari S, Rahimzadeh P, Haghighi M. Local infiltration anesthesia: does it really work?. *Ann Transl Med*. 2015;**3**(18):275. doi: [10.3978/j.issn.2305-5839.2015.09.24](https://doi.org/10.3978/j.issn.2305-5839.2015.09.24). [PubMed: [26605321](https://pubmed.ncbi.nlm.nih.gov/26605321/)].
- Funk L. A prospective trial to compare three anaesthetic techniques used for the reduction of fractures of the distal radius. *Injury*. 1997;**28**:209-12. doi: [10.1016/S0020-1383\(96\)00183-0](https://doi.org/10.1016/S0020-1383(96)00183-0).
- Kendall JM, Allen P, Younge P, Meek SM, McCabe SE. Haematoma block or Bier's block for Colles' fracture reduction in the accident and emergency department-which is best?. *J Accid Emerg Med*. 1997;**14**(6):352-6. doi: [10.1136/emj.14.6.352](https://doi.org/10.1136/emj.14.6.352). [PubMed: [9413772](https://pubmed.ncbi.nlm.nih.gov/9413772/)].
- Kendall JM, Allen PE, McCabe SE. A tide of change in the management of an old fracture?. *J Accid Emerg Med*. 1995;**12**(3):187-8. doi: [10.1136/emj.12.3.187](https://doi.org/10.1136/emj.12.3.187). [PubMed: [8581243](https://pubmed.ncbi.nlm.nih.gov/8581243/)].
- Handoll HH, Madhok R, Dodds C. Anaesthesia for treating distal radial fracture in adults. *Cochrane Database Syst Rev*. 2002(3):003320. doi: [10.1002/14651858.cd003320](https://doi.org/10.1002/14651858.cd003320).
- Constantine E, Tsze DS, Machan JT, Ebersson CP, Linakis JG, Steele DW. Evaluating the hematoma block as an adjunct to procedural sedation for closed reduction of distal forearm fractures. *Pediatr Emerg Care*. 2014;**30**(7):474-8. doi: [10.1097/PEC.0000000000000164](https://doi.org/10.1097/PEC.0000000000000164). [PubMed: [24977996](https://pubmed.ncbi.nlm.nih.gov/24977996/)].
- Shaik NA, Rao SS, Chiruvella S, Rao MS, Reddy SV. Effectiveness of butorphanol as an adjuvant to lidocaine for haematoma or periosteal block: A prospective, randomised, double blind study. *Indian J Anaesth*. 2013;**57**(2):150-5. doi: [10.4103/0019-5049.111841](https://doi.org/10.4103/0019-5049.111841). [PubMed: [23825814](https://pubmed.ncbi.nlm.nih.gov/23825814/)].
- Jafarian A, Hassani V, Jesmi F, Ramezani K, Javaheri F, Shariatzadeh H. Efficacy of a Modified Bier's Block in Patients Undergoing Upper Limb Bone Surgery. *Anesth Pain Med*. 2015;**5**(1):22007. doi: [10.5812/aapm.22007](https://doi.org/10.5812/aapm.22007). [PubMed: [25789235](https://pubmed.ncbi.nlm.nih.gov/25789235/)].
- Jafarian AA, Imani F, Salehi R, Najd Mazaher F, Moini F. Simple Arm Tourniquet as an Adjunct to Double-Cuff Tourniquet in Intravenous Regional Anesthesia. *Anesth Pain Med*. 2016;**6**(3):29316. doi: [10.5812/aapm.29316](https://doi.org/10.5812/aapm.29316). [PubMed: [27635387](https://pubmed.ncbi.nlm.nih.gov/27635387/)].
- Fathi M, Moezzi M, Abbasi S, Farsi D, Zare MA, Hafezimeghadam P. Ultrasound-guided hematoma block in distal radial fracture reduction: a randomised clinical trial. *Emerg Med J*. 2015;**32**(6):474-7. doi: [10.1136/emmermed-2013-202485](https://doi.org/10.1136/emmermed-2013-202485). [PubMed: [25016389](https://pubmed.ncbi.nlm.nih.gov/25016389/)].