

Repeated small bowel resection in a patient with Buerger's disease and intestinal involvement

Ali Enshaei, Babak Hajipour, Naser Masoudi

Abstract

Buerger's disease, also called thromboangiitis obliterans, is a recurrent and an uncommon vaso-occlusive inflammatory disease, which typically affects small and medium-sized arteries, veins and nerves of the upper and lower extremities. Mesenteric and multisystem involvement of two or more organs is extremely rare. Here we report the case of a 39-year-old male heavy smoker who had undergone four repetitive laparotomies and multiple small bowel resections for ischaemic involvement of Buerger's disease. He had below-the-knee amputation of the right leg and finger of the left hand because of that disease before bowel involvement. Histopathological findings revealed that the arteries and veins of the resected small intestine were occluded with organised thrombi. Inflammatory cell infiltration was recognised mainly in the intima of distal branches of mesenteric artery. These findings were compatible with previous findings in histopathological examinations of amputated extremities.

Keywords: Buerger's disease, Thromboangiitis obliterans, Small intestine.

Introduction

Buerger's disease, also called thromboangiitis obliterans (TAO), is a recurrent vaso-occlusive disease. Typically, the disease affects middle-aged male smokers and involves small and medium-sized arteries, veins and nerves of the upper and lower extremities.¹ Systemic manifestations involving mesenteric, cerebral, and coronary arteries are exceptional and multisystem involvement of two or more organs is extremely rare. The disease usually affects medium and small arteries and veins of the upper and lower extremities. Visceral artery involvement is rarely reported.² Use or exposure to tobacco plays a central role in the initiation and progression of the disease. By using an antigen-sensitive thymidine-incorporation assay, one study³ showed that patients with TAO have an increased cellular sensitivity to types I and III collagen compared to that in patients with arteriosclerosis obliterans or healthy

males. It is possible that there is an abnormal sensitivity or allergy to some components of tobacco and that this sensitivity in some way leads to an inflammatory small vessel occlusive disease.⁴

Here we report a case of Buerger disease with ischaemic intestinal involvement that led to four laparotomies and multiple small bowel resections. There were multiple perforations in the small bowel due to terminal arteries that were occluded by a thrombus. Previous histopathological examinations of vessels of amputated extremities also had the same findings.

Case Report

A 39-year-old man was admitted with acute abdominal pain. Onset of symptoms had begun 8 hours earlier. He was a known case of Buerger's disease and had history of repeated amputations due to ischaemic necrosis in lower and upper extremities. Lumbar and thoracic sympathectomies were done for him. The patient had smoked about 30 cigarettes per day for 25 years, but had no other risk factors for atherosclerotic disease.

His right lower extremity was amputated from below the knee 5 years earlier and hand fingers 3 years before the admission for acute abdominal pain. Previous angiographic and histopathological examinations of amputated extremities revealed Buerger's disease. He didn't stop smoking after sympathectomies and had not

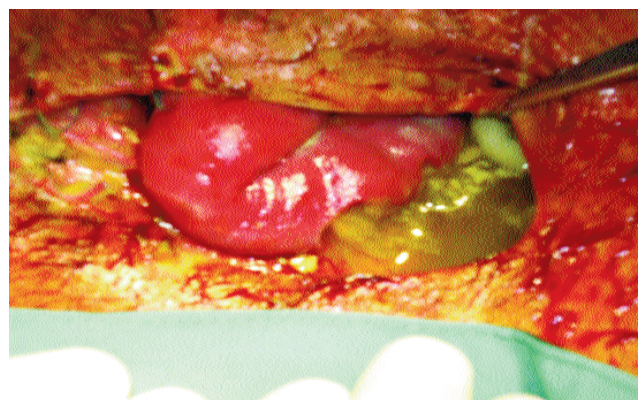

Figure-1: Multiple ischaemic necrosis and perforations in small bowel.

.....
Department of Surgery, Urmia University of Medical Sciences, Urmia, Iran.

Correspondence: Babak Hajipour. Email: hajipourb@yahoo.com

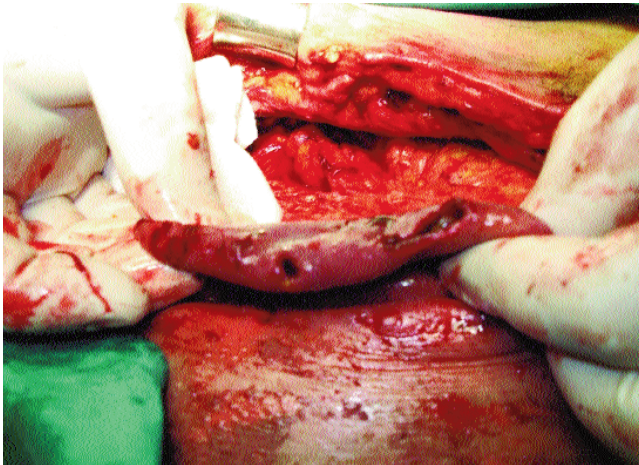


Figure-2: Multiple ischaemic necrosis and perforations.

used daily oral anticoagulant medicine. He was referred to our department because of a being a known case of Buerger's disease with abdominal pain and acute abdomen and he had all diagnostic criteria's of this disease.

In recent admission his abdominal pain, with muscle guarding, laboratory tests, abdominal X-ray and monographic examinations suggested small bowel ischaemia. The patient underwent emergency laparotomy and 25cm of distal ileum near 20cm to illio-caecal valve were resected due to ischaemic gangrene and end-to-end illio-ileal anastomosis was done. The patient did not stop smoking during hospitalisation. Seven days after operation, bilious discharge occurred from abdominal drain that had not responded to conservative treatments, and it increased after ten days. Reoperation was done and there were four multiple bursting perforations in anti-mesenteric side of small bowel 6cm near the previous anastomotic site. Perforations had 3 to 4 cm distance from each other (Figures-1, 2). Resection of involved ilium near 30cm was done and for the proximal part of ilium created illiostomy.

Six days after second operation bilious discharge from drain and abdominal midline sutures occurred again and increased daily and led to third laparotomy. Third operation finding were the same as at second operation; there were multiple perforations with 3 to 5cm distance from each other between illiostomy and jejunum that led to resection and end-to-end anastomosis. The patient was under parenteral nutrition for one month and after one month abdominal wall dehiscence and small bowel perforation occurred that led to fourth operation. Intraoperative findings were

the same as on previous surgeries.

The patient expired two months after multiple small bowel perforations and septic complications. Resected small bowel histopathological examinations revealed ischaemic perforations on anti-mesenteric sides and showed terminal branches of mesenteric arteries with thrombosis and they were swollen and infiltrated with neutrophils and thickening of the intima.

Discussion

Mesenteric involvement of Buerger's disease is very rare. Preoperative diagnosis of disease is difficult in patients presenting with acute abdomen. Buerger's disease may affect at any time during the disease process, but usually occurs years after the onset of the disease. However, most diagnosed cases had significant peripheral vascular involvement before affecting mesenteric vessels.^{5,6} The small intestine is the most frequently involved site of Buerger's disease.

The diagnosis of mesenteric Buerger's disease is often difficult as it relies heavily on exclusion of other conditions. The clinician's best tool for successful diagnosis is a high index of suspicion. The small bowel is involved more frequently than the colon and most lesions are segmental.⁷

The clinical presentation of mesenteric ischaemia in Buerger's disease is not specific and causes acute or chronic abdominal pain, diarrhoea, weight loss, intestinal occlusion or acute peritonitis requiring prompt surgical intervention.⁸ The non-specific presentation poses a diagnostic challenge. Even after identifying mesenteric ischaemia as the cause of gastrointestinal symptoms, establishing the correct diagnosis requires a thorough clinical, radiological, laboratory and histopathological work-up.

In our case although the patient received anti-coagulant treatment but the ischaemia extended to other segments of the intestine. Repeated resection of the intestine was inevitable as in the first operation there was no ischaemic area after resection. Extended resection of the intestine was not acceptable in the first operation as it could have caused short bowel syndrome in future.

Conclusion

Diagnosis of gastrointestinal involvement of Buerger's disease is difficult in early stages and has poor prognosis. If patients with established or suspicious clinical manifestation of extremity Buerger's disease complain of gastrointestinal symptoms, early interventional diagnosis is suggested for the prevention of intestinal damage.

References

1. Iwai T, Inoue Y, Umeda M, Huang Y, Kurihara N, Koike M, et al. Oral bacteria in the occluded arteries of patients with Buerger disease. *J Vasc Surg.* 2005;42:107-15.
 2. Olin JW. Thromboangiitis obliterans (Buerger's disease). *N Engl J Med.* 2000; 343:864-9.
 3. Adar R, Papa MZ, Halpern Z, Mozes M, Shoshan S, Sofer B, et al. Cellular sensitivity to collagen in thromboangiitis obliterans. *N Engl J Med.* 1983; 308:1113-6.
 4. Magalhães Ede P, Trevisan M, Mochizuki M, Sachetto Z, Samara AM, Fernandes SR Intestinal ischemia as a single manifestation of thromboangiitis obliterans: a case report. *Angiology.* 2005; 56:789-92.
 5. Krupski WC, Selzman CH, Whitehill TA. Unusual causes of mesenteric ischemia. *Surg Clin North Am.* 1997; 77:471-502.
 6. Kobayashi M, Kurose K, Kobata T, Hida K, Sakamoto S, Matsubara J. Ischemic intestinal involvement in a patient with Buerger disease: case report and literature review. *J Vasc Surg.* 2003; 38:170-4.
 7. Borlaza GS, Rapp R, Weatherbee L, Demetropoulos K. Visceral angiographic manifestation of thromboangiitis obliterans. *South Med J.* 1979; 72:1609-11.
 8. Sauvaget F, Debray M, Hervé de Sigalony JP, Fichelle JM, Farge D, Lémann M, et al. Colonic ischemia reveals thromboangiitis obliterans. *Gastroenterology.* 1996; 110:900-3.
-