

Comparative Study of Radiographic and Laboratory Findings Between Beta Thalassemia Major and Beta Thalassemia Intermedia Patients With and Without Treatment by Hydroxyurea

Amin Abolhasani Foroughi¹; Hosein Ghaffari¹; Sezaneh Haghpanah²; Masoume Nazeri³; Roghieh Ghaffari⁴; Marzieh Bardestani⁵; Mehran Karimi^{2,*}

¹Medical Imaging Research Center, Nemazee Hospital, Shiraz University of Medical Sciences, Shiraz, IR Iran

²Hematology Research Center, Shiraz University of Medical Sciences, Shiraz, IR Iran

³Department of Neurology, Motahhari Clinic, Shiraz University of Medical Sciences, Shiraz, IR Iran

⁴Department of Pediatric, Urmia University of Medical Sciences, Urmia, IR Iran

⁵Department of Library and Information Science, College of Humanities, Khuzestan Science and Research Branch, Islamic Azad University, Ahvaz, IR Iran

*Corresponding Author: Mehran Karimi, Hematology Research Center, Shiraz University of Medical Sciences, Shiraz, IR Iran. Tel/Fax: +98-7136473239, E-mail: Karimim@sums.ac.ir

Received: September 14, 2014; Revised: December 24, 2014; Accepted: January 13, 2015

Background: In patients with thalassemia, chronic anemia causes bone marrow expansion and consequently skeletal manifestation in spine, skull, face and rib bones.

Objectives: We aimed to compare chest radiographic findings and facial bone deformity in patients with thalassemia major (TM) and intermedia.

Patients and Methods: In this cross sectional study, 86 consecutive thalassemia patients referring to the Thalassemia clinic in Shiraz, Southern Iran were evaluated during 2012. Patients were divided into three groups including TM and thalassemia intermedia (TI) with and without taking hydroxyurea (HU). Findings of chest radiography (trabeculation, rib widening and paraspinal masses) as well as facial bone deformity were evaluated by an expert radiologist. Besides, laboratory findings were measured regarding hemoglobin, ferritin, NRBC and platelet count.

Results: All radiologic findings were significantly higher in patients with TI compared to TM ($P < 0.05$). In patients with TI, only trabeculation was observed with a higher frequency in patients with HU compared to those without HU (68% vs. 27.3%, $P = 0.008$). In the regression model, from all variables evaluated, only NRBC showed a significant correlation with trabeculation (Exp B = 1.014, CI: 1.004-1.025, $P = 0.008$) and age showed a significant correlation with paravertebral mass (Exp B = 1.147, CI: 1.03-1.27, $P = 0.013$).

Conclusions: In patients with TM, bone widening, trabeculation, paraspinal masses and facial bone deformity were lower than patients with TI, which can be related to effectiveness of therapy with blood transfusion irrespective of its adverse effects in TM patients.

Keywords: Beta-Thalassemia; Hydroxyurea; Mass Chest X-Ray

1. Background

Thalassemia is the most prevalent congenital anemia worldwide. Beta Thalassemia is a type of anemia characterized by defect in synthesis of Beta hemoglobin chains. The imbalance in beta chain synthesis leads to unstable red blood cells (RBC) and hemolytic anemia. Prolonged hypoxia is a cause of increased erythropoiesis, which leads to splenomegaly and Extra medullary hematopoiesis (EMH). Bone marrow hyperplasia is a cause of several skeletal abnormalities such as face deformity, paraspinal mass, rib widening and skull deformity (1-3). Depending on the severity of Beta chain involvement, three types of beta thalassemia exist. Beta TM defined by severe hemolytic anemia starting in childhood, and patients die in early childhood without transfusion, whereas TI is a kind of anemia that patient can maintain hemoglobin levels about 6-7 g/dL without transfusion. The less severe type is thalassemia minor,

which has no significant manifestations except for low blood hemoglobin levels (3-5).

TM and TI patients depending on the severity of treatment and blood transfusion, may have a broad spectrum of skeletal related abnormalities. Some skeletal related abnormalities may be osteopenia, erosion, scoliosis, cord compression, paraspinal mass, fracture, rib erosion, rib widening and cortical thinning (3, 6-13). Most skeletal manifestations are related to extramedullary hematopoiesis (EMH) caused by patients anemia. Improvement in normal RBC count can reduce EMH (14).

Blood transfusion can reduce patients need for EMH, so it can reduce skeletal related manifestations in TM, but it has risk of iron overload secondary to repeated long time blood transfusion (7, 15). TI patients have higher level of hemoglobin and less need for blood transfusion. Improvement of anemia by treatment with

hydroxyurea is a known therapy for these patients (15-20). Hydroxyurea is an antimetabolite drug, which can reduce speed of skeletal changes, rib widening and erosion (16, 21) by increasing hemoglobin F level. Up to this time, some studies were performed on the effects of hydroxyurea treatment on skeletal manifestations, but no study compared skeletal manifestations of TM and TI (12, 16, 19, 21-28).

2. Objectives

The purpose of this study was to compare chest x-ray (CXR) manifestations of TM patients who received long time blood transfusion and CXR findings of TI patients with and without treatment by hydroxyurea.

3. Patients and Methods

In this cross sectional study, 100 consecutive thalassemia patients (major and intermedia) referred to the Thalassemia Clinic of Dastgheib hospital, a governmental referral center in Southern Iran, entered the study during 2012. The risk of CXR and the need of blood sampling were explained for patients and a written consent was taken from each patient or their parents. This study was approved by the medical ethics committee of Shiraz University of Medical Sciences based on the research project number of 91-01-01-4778. The exclusion criteria were chronic concomitant disease, unwilling to participate in the study and those patients who were from cities with high florid level in drinking water. Finally, 86 thalassemia patients were enrolled. Diagnosis of beta-thalassemia was based on complete blood count, Hb electrophoresis and clinical status. All patients with TI were transfusion-independent, but patients with TM were transfusion-dependent with frequency of every 2-4 weeks. CXRs were taken by a single expert technologist with direct digital calibrated X-ray equipment (Coong waveVidix II, Seoul-Dongjak South Korea). All radiographies were reported by a single expert radiologist blinded to the type of thalassemia. Patients were divided into three groups: patients with thalassemia intermedia who received hydroxyurea 8-15 mg/kg/day for at least 10 years (group1, n = 25), those with TI who did not receive hydroxyurea (group2, n = 22) and those with TM without treatment by hydroxyurea (group3, n = 39). We reviewed CXRs with special attention to skeletal changes including coarse trabeculation, paraspinal masses, rib widening and facial bone deformity. Serum ferritin levels were measured by Enzyme Linked Fluorescent Assay (VIDAS machine, France). Besides, complete blood count was measured by a Sysmex KX-21 analyzer (TOA system, Japan). All laboratory instruments were calibrated.

3.1. Statistical Analysis

The data were analyzed using SPSS version 17 (SPSS Inc., Chicago, IL, USA). Kolmogorov Smirnov test was used

to test normality of evaluated variables. Comparison of quantitative variables was performed between the two groups by student t test, and among the three groups by ANOVA after checking ANOVA assumptions. Post-hoc Turkey test was used for pair comparisons. Qualitative parameters were compared by Chi-square test between the two groups. Multiple logistic regressions were used for detecting independent factors affecting the occurrence of radiologic findings. P value less than 0.05 was considered statistically significant.

Sample size calculation: Considering an estimation for prevalence of radiographic findings in thalassemia patients of about 25%, precision=9%, and confidence interval of 95%, 89 patients were calculated as sample size. As mentioned above we considered 100 consecutive patients based on inclusion criteria and 14 patients were excluded based on exclusion criteria. Finally, 86 patients participated.

4. Results

From 86 patients, 37 were male and 49 were female. Comparisons of demographic variables and laboratory data between the three groups are demonstrated in Table 1. The three evaluated groups showed significant differences regarding all variables except splenectomy. All radiographic manifestations as well as facial bone deformity showed statistically significant differences between patients with TI and TM (Table 2). In comparison of the two groups of β -TI patients, patients taking HU only showed a significantly higher frequency of trabeculation compared with those not taking HU ($P = 0.008$) (Table 3) (Figure 1).

Univariate analysis was conducted to determine the correlation of demographic and laboratory variables with radiographic findings and facial bone deformity in patients with β -TI (Table 4). Investigated variables included gender, age, hemoglobin, RBC, platelet, NRBC and ferritin level. Trabeculation showed significant associations with platelet ($P = 0.012$), NRBC ($P = 0.002$) and ferritin level ($P = 0.028$). In patients with parasternal mass, statistically significant correlations were observed with age ($P = 0.005$) and NRBC ($P = 0.041$). Rib widening and facial bone deformity showed significant correlations with ferritin level ($P = 0.015$ and $P = 0.009$, respectively).

In the second step, multiple logistic regressions were performed to determine independent influencing factors on trabeculation and parasternal mass in patients with β -TI. In the regression model, only NRBC showed significant correlation with trabeculation (Exp B = 1.014, CI: 1.004-1.025, $P = 0.008$) and age showed significant correlation with paravertebral mass (Exp B = 1.147, CI: 1.03-1.27, $P = 0.013$) (Figure 2). Regarding facial bone deformity, we performed univariate analysis for gender, age, hemoglobin, RBC, platelet, WBC and ferritin level, which showed no significant associations with each of the variables ($P > 0.05$).

Table 1. Comparison of Demographic and Laboratory data Between the Three Groups of Patients with β -Thalassemia^{a,b,c}

Parameters	Group 1 ^d	Group 2 ^e	Group 3 ^f	P Value
Male	16 (64)	11 (50)	10 (25.6)	0.008
Age, y	26.7 \pm 7.8	20.7 \pm 7.2	24.2 \pm 5.7	0.016
Hemoglobin, g/dL	8.7 \pm 1.4	9.7 \pm 1.1	9.4 \pm 0.7	0.005
RBC, No. $\times 10^6$	3.4 \pm 0.6	4.3 \pm 0.7	3.7 \pm 0.3	< 0.001
MCV, fL	83.3 \pm 9.8	70 \pm 7.8	79.1 \pm 3.8	< 0.001
MCH, pg	25.8 \pm 3.8	21.6 \pm 2.9	25.9 \pm 1.2	< 0.001
WBC, No.	31278 \pm 30947	12357 \pm 9521	10072 \pm 6666	< 0.001
Nucleated RBC (per 100 WBC)	212.5 \pm 220	60.3 \pm 132	-	0.009
Platelet, No.	584954 \pm 244910	384922 \pm 275632	329157 \pm 172050	< 0.001
Ferritin, ng/cc	762 \pm 602	518 \pm 461	2094 \pm 1786	< 0.001
Duration of splenectomy, y	14 \pm 8.9 ^g	14 \pm 5.4 ^h	16.3 \pm 9.2 ⁱ	0.632

^a Data are presented as No. (%) or Mean \pm SD.

^b Abbreviations: MCH, mean corpuscular hemoglobin; MCV, mean corpuscular volume; RBC, red blood cell; WBC, white blood cell.

^c In paired comparison of different variables between the three groups, significant differences were observed as follows; Age: groups 1 and 2; Hemoglobin: groups 1 and 2, groups 1 and 3; RBC: groups 1 and 2, groups 2 and 3; MCV: groups 1 and 2, groups 2 and 3; MCH: groups 1 and 2, groups 2 and 3; WBC: groups 1 and 2, groups 1 and 3; Platelet: groups 1 and 2, groups 1 and 3; Ferritin: groups 1 and 3, groups 2 and 3.

^d β -thalassemia intermedia with hydroxyurea (n = 25).

^e β -thalassemia intermedia without hydroxyurea (n = 22).

^f β -thalassemia major (n = 39).

^g n = 23.

^h n = 17.

ⁱ n = 18.

Table 2. Comparing the Frequency of Radiographic Findings and Facial Bone Deformity Between Patients with β -Thalassemia Intermedia and Major^a

Radiographic Findings and Facial Bone Deformity	β -Thalassemia Intermedia	β -Thalassemia Major	Total	P Value
Trabeculation	23 (48.9)	1 (2.6)	24 (27.9)	< 0.001
Para vertebral mass	15 (31.9)	0 (0)	15 (17.4)	< 0.001
Rib Widening	15 (31.9)	5 (12.8)	20 (23.3)	0.043
Facial bone deformity	33 (70.2)	14 (35.9)	47 (54.7)	0.002

^a Data are presented as No. (%).

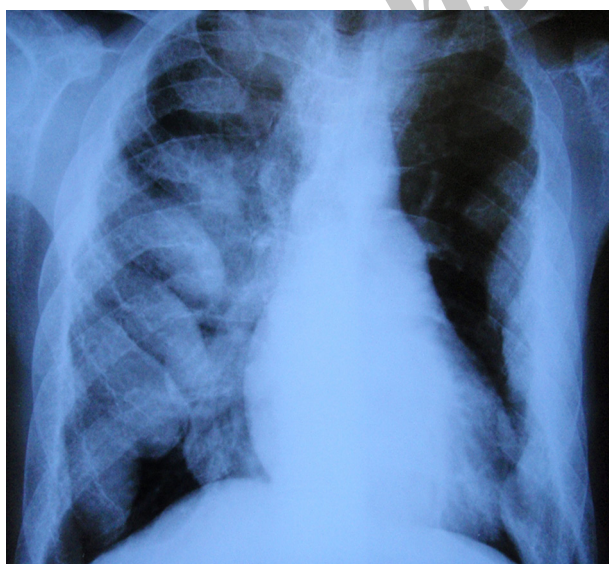
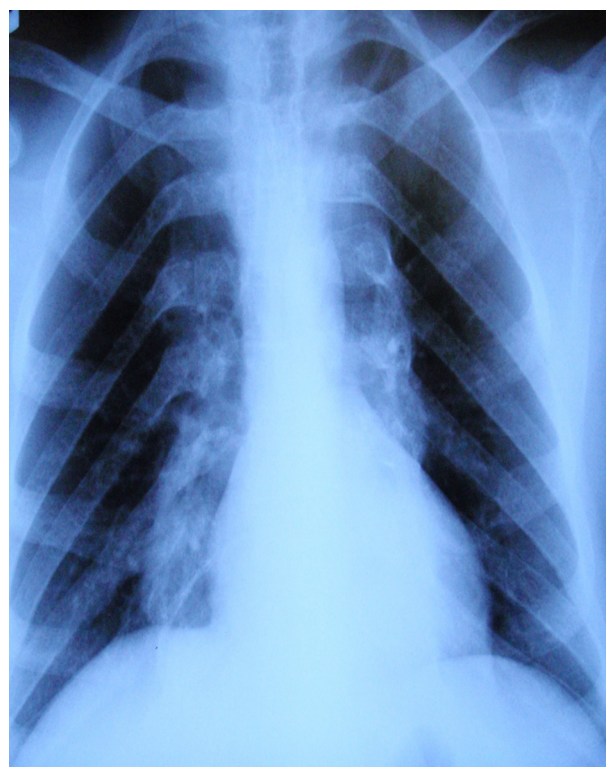
Table 3. Comparing the Frequency of Radiographic Findings and Facial Bone Deformity Between β -Thalassemia Intermedia Patients With and Without Taking Hydroxyurea^a

Radiographic Findings and Facial Bone Deformity	β -Thalassemia Intermedia With Hydroxyurea	β -Thalassemia Intermedia Without Hydroxyurea	P Value
Trabeculation	17 (68)	6 (27.3)	0.008
Paravertebral mass	8 (32)	7 (31.8)	1
Rib Widening	10 (40)	5 (22.7)	0.230
facial bone deformity	20 (80)	11 (59.1)	0.201

^a Data are presented as No. (%).

Table 4. Univariate Analysis of Some Covariates Associated With Radiographic Findings of Patients With β -Thalassemia Intermedia ^{a,b}

Variables	Age, y	Platelet	NRBC, %	Ferritin
Trabeculation				
Yes		618800 \pm 309070	235 \pm 231	863 \pm 638
No		403391 \pm 209470	51.5 \pm 99.9	450 \pm 361
P Value		0.012	0.002	0.028
Parasternal mass				
Yes	29.3 \pm 5.6		255 \pm 263	
No	21.9 \pm 8		90 \pm 136	
P Value	0.005		0.041	
Rib Widening				
Yes				956 \pm 592
No				491 \pm 461
P Value				0.015
Facial bone deformity				
Yes				779 \pm 598
No				370 \pm 269
P Value				0.009

^a Data are presented as Mean \pm SD.^b Only significant data have been shown.**Figure 1.** Chest X-Ray of a 28-Year Old Man With Thalassemia Intermedia Who was Receiving Hydroxyurea; Rib Widening and Coarse Trabeculation Are Evident.**Figure 2.** Chest X-Ray of a 28-Year Old Man With Thalassemia Intermedia Who Was Receiving Hydroxyurea, Paraspinal Masses are Evident.

5. Discussion

In this study, frequency of trabeculation was higher in patients with treatment by hydroxyurea in respect to TI patients without treatment by HU; it may be related to longer lasting anemia in this group or different response of patients to treatment by hydroxyurea secondary to genetic properties. Older age of patients in TI patients with treatment by HU means that they tolerate anemia more, so skeletal changes can be more expected in them and it may not be related to use of hydroxyurea; also, treatment of these patients with low dose hydroxyurea may not have significant effect on lowering the chance of trabeculation and bone widening. Cario et al. described a case of TI treated by hydroxyurea with no aggravation of EMH despite a session of therapy with blood transfusion(22). In TI patients with treatment by HU, paraspinal masses were not lower than TI patients without treatment by HU; in TI patients with treatment by HU rib widening and facial bone deformity were higher than TI patients without treatment by HU, which was not statically significant. Other studies showed that treatment with hydroxyurea could improve sense of well-being, also reduce EMH depending on genetic properties and severity of the symptoms (15, 20).

In patients with TM, bone widening, trabeculation and paraspinal masses were lower than patients with TI; other

studies showed similar results (2, 22). It can be due to long time treatment of TM patients by blood transfusion and efficacy of this type of treatment to lower EMH; however, blood transfusion has several life threatening complications. Ferritin level was lower in TI patients with treatment by hydroxyurea and TI patients without treatment by hydroxyurea in respect to TM. Alebouyeh et al. reported similar results and they described, it is related to blood transfusion session, more utilization of Iron for RBC synthesis and stop of EMH in TI taking hydroxyurea (15).

In this study, TI patients with treatment by hydroxyurea had higher age, higher nucleated RBC and lower hemoglobin level compared to TI patients without treatment by hydroxyurea. In TI patients with treatment by hydroxyurea, RBC count was the least, MCV and MCH were the highest levels; it is in line with another study performed by Cario et al. (22). From independent factors, only NRBC had a significant correlation with trabeculation in TI patients with treatment by hydroxyurea; we do not have any explanation for this. Facial bone deformity in the three groups was not correlated with age, gender, hemoglobin, platelet, RBC count and ferritin level. Facial bone deformity was more in TI; it is in line with a study performed by Berjis et al. (29). In our study, the mean age of TI patients who were receiving hydroxyurea was higher than the two other groups; this can influence skeletal changes secondary to longer lasting anemia, so further investigations with age-matched groups are needed.

The most frequent chest radiographic and facial bone deformity was seen in TI treated with hydroxyurea. It could be related to the chronicity of anemia, genetic effect in response to hydroxyurea, and therapy with low dose hydroxyurea, higher age of this group and duration of therapy. In patients with TM, bone widening, trabeculation and paraspinal masses were lower than patients with TI, it can be related to effectiveness of therapy with blood transfusion irrespective of its adverse effects in TM patients.

Authors' Contributions

Amin Abolhasani Foroughi contributed to drafting and editing the manuscript. Hosein Ghaffari contributed to writing and data collection. Sezaneh Haghpanah edited the manuscript and performed the statistical analysis. Masoume Nazeri, Roghieh Ghaffari and Marzieh Bardestani contributed to data collection. Mehran Karimi contributed to study design, concept and editing the manuscript.

Funding/Support

This thesis was supported by deputy dean of School of Medicine based on the research project number 91-01-01-4778 of Dr. Hosein Ghaffari, and sponsored by Shiraz University of Medical Sciences.

References

- Cappellini MD, Cohen A, Eleftheriou A, Piga A, Porter J, Taher A.

Guidelines for the Clinical Management of Thalassemia. 2nd Revised ed Nicosia (CY); 2008.

- Muncie HL, Jr., Campbell J. Alpha and beta thalassemia. *Am Fam Physician*. 2009;**80**(4):339-44.
- Tunaci M, Tunaci A, Engin G, Ozkorkmaz B, Dincol G, Acunas G, et al. Imaging features of thalassemia. *Eur Radiol*. 1999;**9**(9):1804-9.
- Baldini M, Marcon A, Cassin R, Ulivieri FM, Spinelli D, Cappellini MD, et al. Beta-thalassaemia intermedia: evaluation of endocrine and bone complications. *Biomed Res Int*. 2014;**2014**:174581.
- Karimi M, Cohan N, De Sanctis V, Mallat NS, Taher A. Guidelines for diagnosis and management of Beta-thalassemia intermedia. *Pediatr Hematol Oncol*. 2014;**31**(7):583-96.
- Habibzadeh F, Yadollahie M, Haghshenas M. Extra-medullary haematopoiesis in beta-thalassaemia. *J Postgrad Med*. 2005;**51**(1):45-6.
- Haidar R, Mhaidli H, Taher AT. Paraspinal extramedullary hematopoiesis in patients with thalassemia intermedia. *Eur Spine J*. 2010;**19**(6):871-8.
- Jensen CE, Tuck SM, Agnew JE, Koneru S, Morris RW, Yardumian A, et al. High prevalence of low bone mass in thalassaemia major. *Br J Haematol*. 1998;**103**(4):911-5.
- Karimi M, Ghiam AF, Hashemi A, Alinejad S, Soweid M, Kashef S. Bone mineral density in beta-thalassemia major and intermedia. *Indian Pediatr*. 2007;**44**(1):29-32.
- Papavasiliou C, Konstantoulakis M, Priovolos J, Labrakos E, Agrogianis B, Manettas E, et al. The anterior costal margin mass in patients with thalassaemia major. *Clin Radiol*. 1979;**30**(5):521-4.
- Scutellari PN, Bigli S, Franceschini F, Orzincolo C. [Skeletal changes in intermediate beta-thalassemia. Clinical and radiological study]. *Minerva Med*. 1982;**73**(9):457-66.
- Sproat IA, Dobranowski J, Chen V, Ali M, Woods D. Presacral extramedullary hematopoiesis in thalassemia intermedia. *Can Assoc Radiol J*. 1991;**42**(4):278-82.
- Wong Y, Chen F, Tai KS, Yip LK, Tsang KW, Chan FL, et al. Imaging features of focal intrahepatic extramedullary haematopoiesis. *Br J Radiol*. 1999;**72**(861):906-10.
- Berdoukas V, Farmaki K, Carson S, Wood J, Coates T. Treating thalassaemia major-related iron overload: the role of deferiprone. *J Blood Med*. 2012;**3**:119-29.
- Aleboyyeh M, Moussavi F, Haddad-Deylami H, Vossough P. Hydroxyurea in the treatment of major beta-thalassaemia and importance of genetic screening. *Ann Hematol*. 2004;**83**(7):430-3.
- Ansari SH, Shamsi TS, Ashraf M, Perveen K, Farzana T, Bohray M, et al. Efficacy of hydroxyurea in providing transfusion independence in beta-thalassemia. *J Pediatr Hematol Oncol*. 2011;**33**(5):339-43.
- Bordbar MR, Silavizadeh S, Haghpanah S, Kamfirooz R, Bardestani M, Karimi M. Hydroxyurea Treatment in Transfusion-Dependent beta-Thalassemia Patients. *Iran Red Crescent Med J*. 2014;**16**(6).
- Ehsani MA, Hedayati-Asl AA, Bagheri A, Zeinali S, Rashidi A. Hydroxyurea-induced hematological response in transfusion-independent beta-thalassemia intermedia: case series and review of literature. *Pediatr Hematol Oncol*. 2009;**26**(8):560-5.
- Karimi M. Hydroxyurea in the management of thalassemia intermedia. *Hemoglobin*. 2009;**33** Suppl 1:S177-82.
- Karimi M, Cohan N, Pishdad P. Hydroxyurea as a first-line treatment of extramedullary hematopoiesis in patients with beta thalassemia: Four case reports. *Hematology*. 2014.
- Borgna-Pignatti C. Modern treatment of thalassaemia intermedia. *Br J Haematol*. 2007;**138**(3):291-304.
- Cario H, Wegener M, Debatin KM, Kohne E. Treatment with hydroxyurea in thalassemia intermedia with paravertebral pseudotumors of extramedullary hematopoiesis. *Ann Hematol*. 2002;**81**(8):478-82.
- Hoppe C, Vichinsky E, Lewis B, Foote D, Styles L. Hydroxyurea and sodium phenylbutyrate therapy in thalassemia intermedia. *Am J Hematol*. 1999;**62**(4):221-7.
- Koren A, Levin C, Dgany O, Kransnov T, Elhasid R, Zalman I, et al. Response to hydroxyurea therapy in beta-thalassemia. *Am J Hematol*. 2008;**83**(5):366-70.
- Ileri T, Azik F, Ertem M, Uysal Z, Gozdasoglu S. Extramedullary he-

- matopoiesis with spinal cord compression in a child with thalassaemia intermedia. *J Pediatr Hematol Oncol.* 2009;**31**(9):681-3.
26. Italia KY, Jijina FJ, Merchant R, Panjwani S, Nadkarni AH, Sawant PM, et al. Response to hydroxyurea in beta thalassaemia major and intermedia: experience in western India. *Clin Chim Acta.* 2009;**407**(1-2):10-5.
27. Meo A, Cassinerio E, Castelli R, Bignamini D, Perego L, Cappellini MD. Effect of hydroxyurea on extramedullary haematopoiesis in thalassaemia intermedia: case reports and literature review. *Int J Lab Hematol.* 2008;**30**(5):425-31.
28. Zamani F, Shakeri R, Eslami SM, Razavi SM, Basi A. Hydroxyurea therapy in 49 patients with major beta-thalassaemia. *Arch Iran Med.* 2009;**12**(3):295-7.
29. Berjis N, Sonbolestan SM, Nemati S, Mokhtarinejad F, Danesh Z. Otorhinolaryngologic Manifestations in Thalassaemia Major Patients. *Iran J Pediatr.* 2007;**17**(1):15-8.

Archive of SID