

A New Technique for Reconstruction of Medium-Sized Eyelid Defects (A Modification of Tessier Nasojugal Flap)

Awat Yousefiazar, MSc¹ Mohsen Hassanzadazar, MD²

¹Department of Surgical Technology, School of Allied Medical Sciences, Urmia University of Medical Sciences, Urmia, West Azerbaijan, the Islamic Republic of Iran

²Department of Plastic and Reconstructive Surgery, Urmia University of Medical Sciences, Imam Khomeini Teaching Hospital, Urmia, West Azerbaijan, the Islamic Republic of Iran

Address for correspondence Mohsen Hassanzadazar, Department of Plastic and Reconstructive Surgery, Urmia University of Medical Sciences, 5 floor, Sepid Medical Center, Hassani Ave, Urmia 1234, the Islamic Republic of Iran (e-mail: a.youa@yahoo.com).

Facial Plast Surg

Abstract

Eyelid reconstructions are considered challenging surgical procedures, which are mostly performed due to trauma, tumor resections, and congenital defects. Several techniques can be used to reconstruct the lower eyelid defects. In this study, the authors aimed to introduce a new single-step technique for the reconstruction of medium-sized lower eyelid defects while preventing ectropion. A modified nasojugal flap was designed and harvested after making a complete incision. A dermal extension from the nasolabial area was added to the end of the nasojugal flap. A tunnel was created under the orbicularis oculi muscle, and the dermal tail was passed through this tunnel toward the lateral canthus. The flap was fixed in its new position by suturing. The defect in the nasojugal area was repaired by bilateral advancement of the surrounding tissue. The recovery of the patients was followed up for 6 months, which included assessment of the eyelid position and donor site morbidity. A total of four patients with an age range of 64 ± 8 years who suffered from basal cell carcinoma were treated using the technique introduced in this study. No ectropion or abnormal eyelid position nor donor site morbidity was observed during the follow-up period. Reconstruction of a medium-sized lower eyelid defect using nasolabial flap with local modification combined with orbital canthus fixation resulted in appropriate functional and cosmetic outcomes and limited the risk of complications and morbidity.

Keywords

- ▶ lower eyelid reconstruction
- ▶ nasolabial flap
- ▶ nasojugal flap
- ▶ ectropion

Eyelid reconstructions can be considered as the most challenging surgical procedure and are mostly done due to trauma, tumor resections, and congenital defects.¹

Optimization of aesthetic and functional outcomes is a general goal in the reconstruction of eyelid defects. Overall, eyelid reconstruction must follow basic principles so that the surgeon should use conventional methods for reconstruction before thinking about more complex methods.²

Given the complex anatomy of the upper and lower eyelid, the changes in one structure can have consequences for all anatomic units. In this regard, a successful surgical procedure will keep vital performance of the eyelids, including acceptable symmetry and aesthetic characteristics.³

Eyelid reconstruction is one of the most common surgeries performed in patients suffering from eyelid cancers. Basal cell carcinoma (BCC) includes more than 90% of lower eyelid tumors that rarely metastasizes but can lead to noticeable morbidity and mortality.⁴

A variety of surgical techniques are available for the reconstruction of eyelid defects, including plastic and ophthalmic surgeries that are technical approaches applied to close eyelid defects.⁵

In lower eyelid defects that include less than one-third of the eyelid margin, direct closure is recommended for reconstruction.² When direct closure is impossible, different alternatives with the goal of saving function and improving

aesthetic features in different locations of the eyelid will be considered.¹

In the defects of lower eyelid involving one-third to half of the eyelid margin, lateral edge advancement of the eyelid by approximation method of semicircular or by rotational flap will be done.²

In patients with full-thickness defects, the defect size and laxity in the periocular tissue are important determinants for best reconstruction results or combinatory reconstruction methods.²

Semicircular flap (Tenzel method) was first described in 1975 by Tenzel. In this method, a semicircular incision is created from the lateral canthus to the superior and then to the lateral aspect of the canthus, and reconstruction is done by medial advancement of the flap while it has enough lateral tissue mobility for reconstruction of defect in the superior or inferior eyelid.⁶

Tarsoconjunctival flap (Hughes flap) can be used for defects that include the posterior lamella of the inferior eyelid. This flap enables reconstruction of lower eyelid defects that involve more than 90% of the eyelid margin. This procedure involves the advancement of the flap from the superior eyelid and tarsus toward the lower eyelid. For the reconstruction of the anterior lamella, a local myocutaneous flap or a full-thickness graft can be used using the same procedure.⁷

Another choice for the reconstruction of the lower eyelid can be the Tripiet flap in which additional tissue of the upper eyelid is used for the reconstruction of the lateral edge of the eyelid.⁸ Also, large cheek flap (Mustarde flap) may be used for bulky anterior lamellar defects of the lower eyelid and cheek.⁹

Another variation of cheek flaps is the modified Fricke's cheek flap, a flap that is harvested from the cheek without using mucosal graft.¹⁰

In addition to these methods, a nasojugal flap of Tessier with upper nasal chondromucosal graft is an excellent method for total or near total defects of the lower eyelid due to the vascularity of the flap. Application of this flap for replacement and smaller chondromucosal graft for the inner lamella is preferable for 50 to 60% of defects in the medial portion of the eyelid.¹¹

Siegel was the first scientist to describe the use of nasolabial flap for covering lower eyelid defects.¹² Nasolabial flap

is an effective flap that can be harvested with a random or axial pattern. Besides the common use of this flap for midface defects, it has different advantages for lower eyelid, including the ease of dissection, skin color matching, tissue texture matches, and minimal mortality and morbidity in donor sites. However, nasolabial flaps have been rarely used for lower eyelid defects.¹

In this study, we have introduced a modified form of nasojugal flap to reconstruct the lower eyelid to provide a mobile lid with good cosmetic and functional effect for corneal protection without ectropion.

Methods

The Institutional Review Board of Urmia University of Medical Sciences approved this study (Ethics Ref. No: Ir.umsu.rec.1396.52). Furthermore, the patients were formally informed about the study and were requested to sign an informed consent form prior to enrollment in the study as well as for publishing their photographs. From July 2015 to May 2017, reconstruction of a medium-sized medial lower eyelid defect was performed on four patients (one man and three women with an average age of 64 ± 8 years and age range of 55–72 years) after cancer surgery by applying an interpolated modified nasolabial flap. All the participants had BCC of the lower eyelid (→Fig. 1). The same surgical method was applied for all the patients, and there were no technical differences in procedures.

First, BCC was surgically excised until clear safe margins were obtained. The margin clearance was pathologically assured using frozen sections. The inclusion criterion for this study was a medium-sized (30–60%) medial side eyelid defect after ablation of carcinoma. The applied strategy for reconstruction of the defect was based on transfer of a nasolabial flap to the defect site. To the best of our knowledge, the use of a modified nasolabial flap introduced in this article has not been previously reported. The reconstructive intervention was initiated after the complete ablation of carcinoma by a cancer surgeon (→Fig. 2). The defects were located at the anterior lamella and medial side of the lower eyelid.

A full-thickness nasolabial flap was raised in an elliptical manner by making an incision in the medial canthus vascular

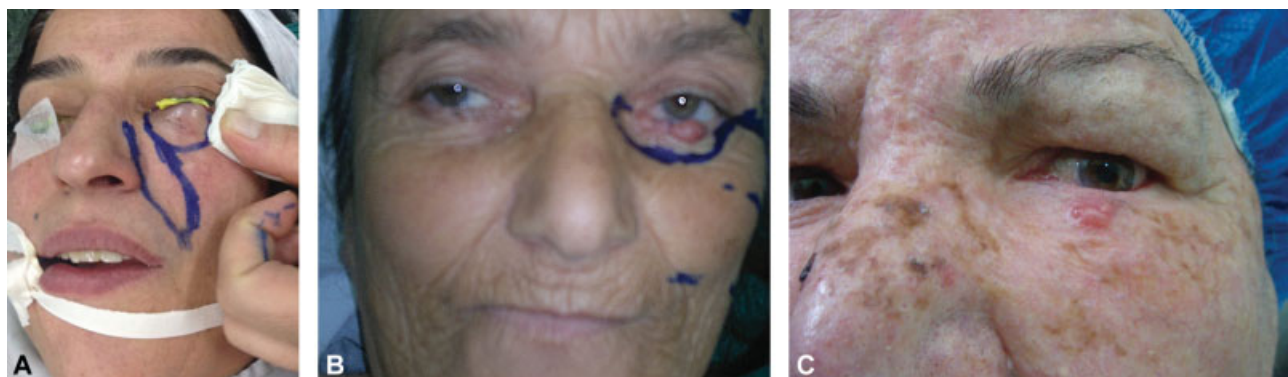


Fig. 1 (A–C) Preop lower lid carcinoma.

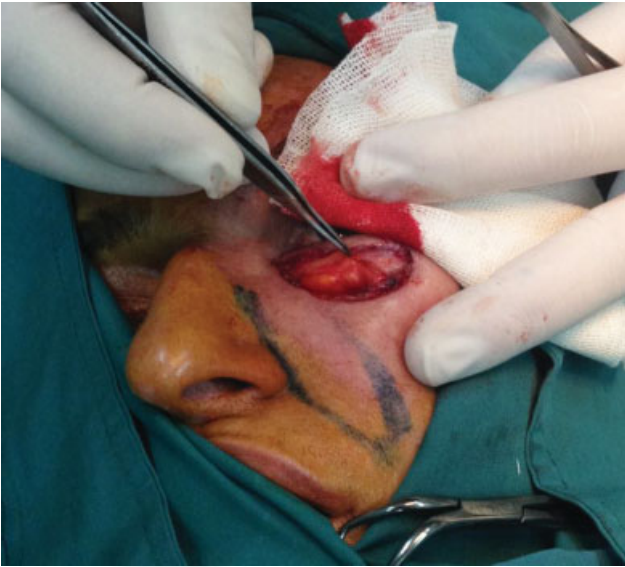

Fig. 2 Removal of basal cell carcinoma (BCC) by a cancer surgeon.

pedicle and extending it to the nasojugal area using a novel modified method, making a partial-thickness nasolabial dermal tail in the terminal portion of the flap.

After making a complete incision and raising the flap, suitable homeostasis was achieved and the wound was prepared for coverage (►Fig. 3).

The donor site was repaired in an anatomic manner by bilateral advancement of the surrounding tissue and interposing the flap into the defect. Our next step was to prevent ectropion by making a tunnel under the orbicularis oculi muscle. The distal dermal tail of the flap was brought to the lateral canthus through the tunnel (►Fig. 4), and the lateral canthus was sutured to the dermal tail of the flap, which was fixed in its new position (►Figs. 5 and 6).

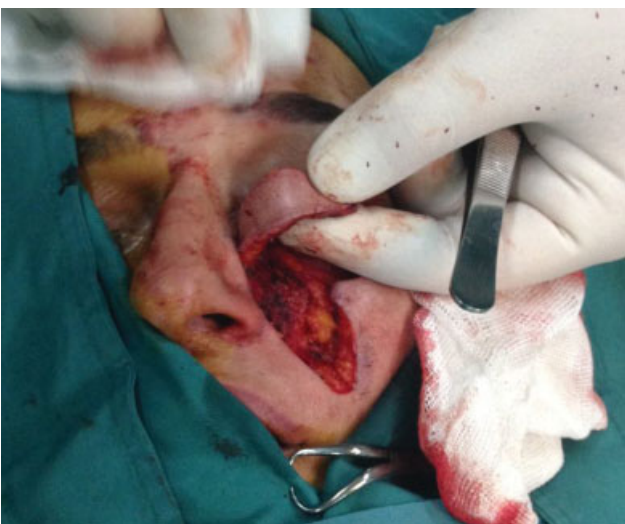

Fig. 3 Modified nasojugal flap after designing and harvesting.

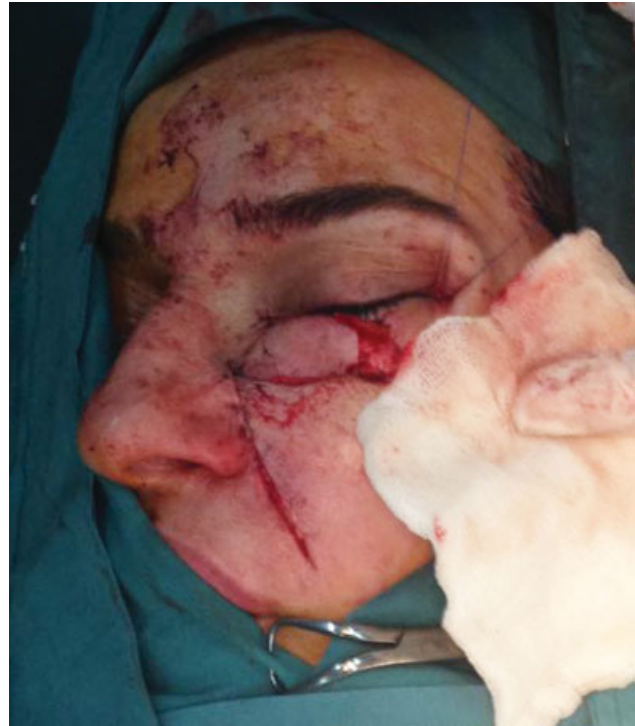

Fig. 4 Passing the dermal tail of the flap through the pre-designed tunnel in the orbital oculi muscle.

Results

We found no tension or ectropion during the 6-month postoperative follow-up period. The results illustrated that the flap was symmetrical, and no excessive bulkiness of the nasolabial flap was observed. Furthermore, there were no complications, including abnormalities in eyelid position, ectropion, corneal irritation, flap contraction, and no donor site morbidity was observed. Moreover, excellent cosmetic results were obtained (►Fig. 7).

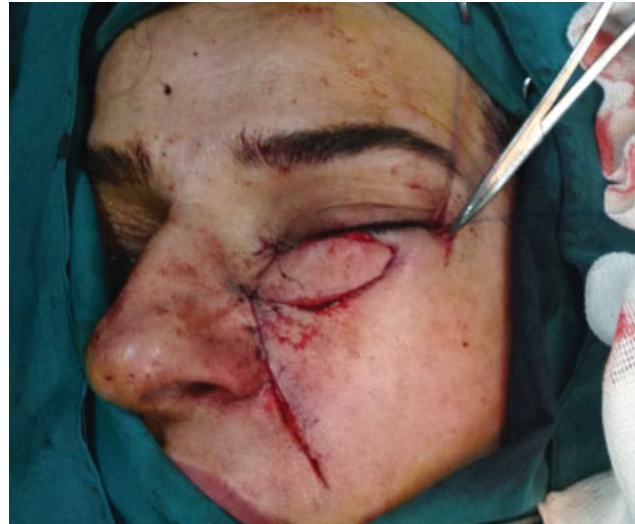

Fig. 5 Suturing the dermal tail of the flap to the lateral canthus.

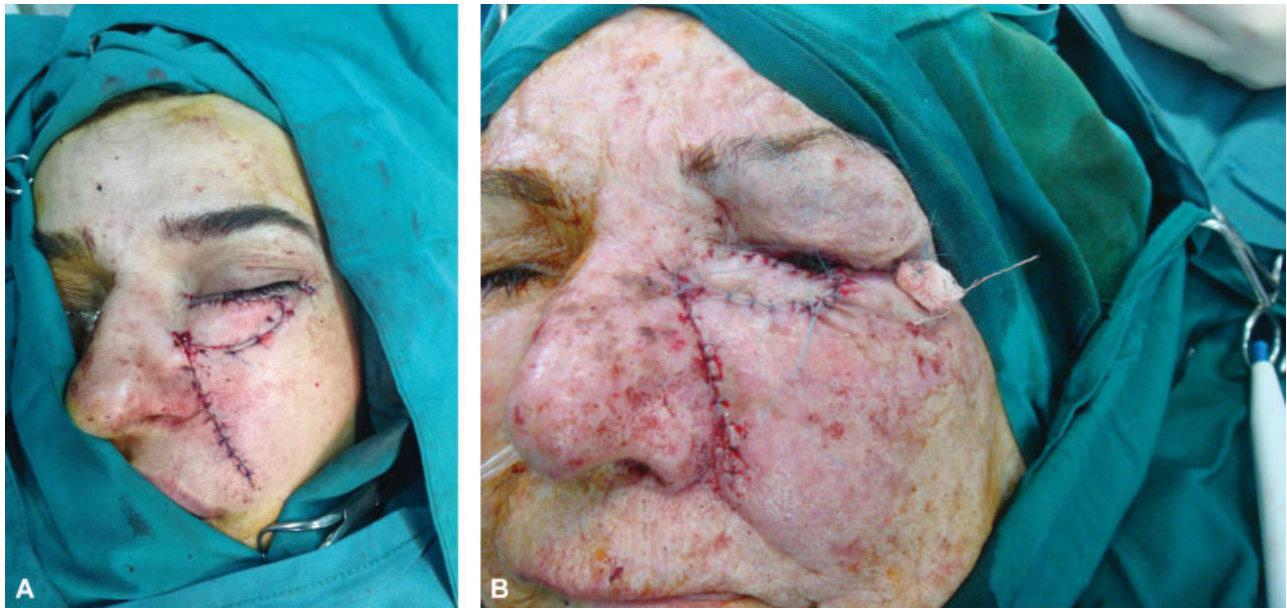

Fig. 6 (A, B) Covering the donor site and fixation of the flap in its new position.

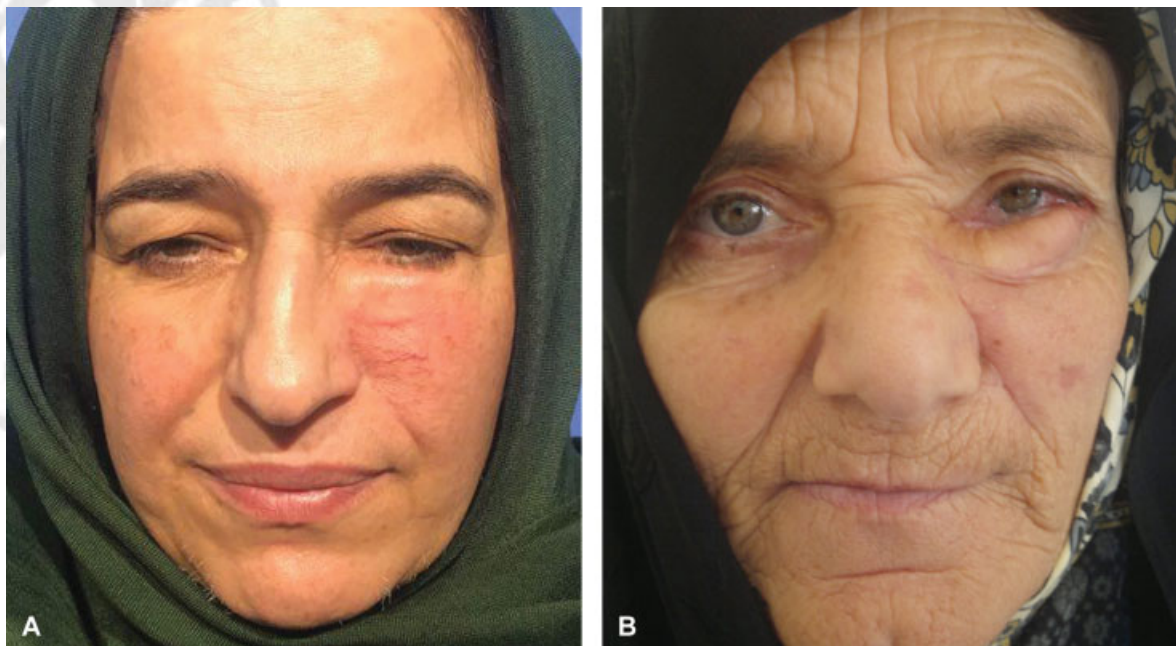


Fig. 7 (A, B) Reconstruction follow-up after 6 months.

Discussion

Reconstruction of the eyelid and periorbital area is difficult due to the quality of tissues in these areas, which are thin, elastic, and highly mobile. However, the tissues close to the orbit, which are generally used for reconstruction, are thick and stiff.¹³⁻¹⁷

Similar to other reconstructive procedures, there is the risk of bleeding, infection, wound dehiscence, and poor survival of graft or flap in the eyelid reconstruction. Moreover, there are potential complications that are unique to the

eyelid reconstruction, including perforation of eyelid margin, retraction, and ectropion.²

As a problematic complication in lower eyelid surgery, ectropion is defined as the inappropriate position of eyelids wherein the lower eyelid margin shows emerges from the globe.¹ Ectropion occurs due to excessive incision of eyelid tissue during blepharoplasty and eyelid reconstruction.³ In addition, other factors causing ectropion include involutional laxity of the lower eyelid as well as mechanical factors such as bulkiness of the facial flaps in comparison to the adjacent anatomic structures, which results in considerable

problems like pain and mucosal irritation due to exposure of conjunctiva.² The incidence of ectropion following removal of eyelid lesions has been reported in 2.5 to 7% of cases.¹⁸

As previously described, there are various methods for lower eyelid reconstruction. The cheek rotation flap offers an alternative surgical approach for cutaneous cover; however, a high prevalence rate of complications, including ectropion, entropies, and epiphora, have been reported due to the necessary cicatricial healing or accidental damage to the forehead branch of the facial nerve.¹⁹

The Mustarde flap can be used for full-thickness defects involving a large area of the lower eyelid, but the need for wide incision, heavy weight of the flap, and scar contraction are the main disadvantages of this method.²⁰

In the study conducted by Tenzel and Stewart,⁶ ectropion, marginal notching, symblepharon, lateral canthal adhesion, and local infection were reported in six patients. Also, in this method, excessive stretching of the flap during wound closure can lead to complications such as lateral canthal web formation and symblepharon.

Also, there is the risk of eyelid malposition, ectropion, conjunctival ectropion, and upper eyelid retraction in Hughes procedure.

As previously described, procedures used for reconstruction of a full-thickness medial half of the lower eyelid defect are performed using either a nasojugal flap or a Tessier with a chondromucosal graft.¹¹

The advantages of using nasolabial flaps are the inconspicuous donor scar concealed in the nasolabial fold and reliable vascularity of the flap. In contrast to the cheek rotation flap, particularly in male patients, any medial displacement of the hair-bearing area is avoided by application of a nasolabial flap.

As reported in various studies, during reconstruction of lower eyelid defects using local flaps, secondary ectropion is sometimes observed, which is induced due to the heavy weight of these flaps. We tried to overcome this issue by applying an easier method, which required less time during the surgery by creating a tunnel under the orbicularis oculi muscle and positioning the dermal tail in this tunnel by suturing it to the lateral canthus.

No complication was detected in patients following application of the method introduced in this study after 6 months of follow-up.

Siegel¹² was the first to describe the use of a nasolabial flap combined with a palatal mucosal graft to cover a shallow lower eyelid defect. Nakajima et al¹³ introduced a subcutaneous pedicle flap pivoting the lateral canthus to reconstruct the skin of the whole eyelid as an aesthetic unit. For single-stage reconstruction of full-thickness eyelid, a palatal mucosal graft was added to line the conjunctival side of the flap. Similar to these approaches, Miyamoto et al²¹ applied a rotation flap based on the orbicularis oculi muscle and a palatal mucosal graft. In all of these procedures, which have been applied for reconstruction of the posterior lamella, a split-thickness palatal mucosal graft has been used to cover the mucosal defect, whereas palatal graft was not applied in the procedure introduced in this study because there was no defect in the posterior lamella.

Siegel reported the formation of a superficial slough in the distal third of the nasolabial flap that healed within a few weeks. No complications (e.g., sloughing) were observed in the approach of this study. The procedure introduced by Siegel involved anatomic reconstruction, and the complexity of the procedure as well as the difficulty to perform it might have limited its application by plastic surgeons; furthermore, upper eyelid deformity may occur after reconstruction using Siegel's method.

Tei and Larsen¹⁹ described the application of Hughes procedure (tarsconjunctival flap) in conjunction with a subcutaneous-based nasolabial transposition flap for the reconstruction of a full-thickness subtotal lower eyelid defect. The second step of their procedure was to separate the tarsconjunctival flap after 3 weeks, although a 3-month clinical assessment revealed neither ectropion nor entropion. However, this method may cause damage to the frontal branch of the facial nerve. Furthermore, there was the likelihood of necrosis because the tissue transfer was performed in a random pattern. In the method introduced in this study, there was no possibility of frontal nerve damage because no lateral incision was made.

The flaps harvested by Tei and Larsen¹⁹ as well as by Nakajima et al¹³ and Tatar et al¹ were random subcutaneous pedicle flaps. In spite of their advantages, subcutaneous pedicle flaps are not widely used in facial reconstruction for several reasons. First, their application is restricted by local thickness, elasticity, and vascularity of the underlying subcutaneous facial tissue. A tendency has also been noted in these flaps toward pincushioning and central fullness. Furthermore, they require relatively extensive local undermining and result in a circumferential geometric scar at the recipient site. These limitations restrict the application of random subcutaneous pedicle flaps at specific locations.²² Moreover, application of these flaps leads to an increased risk of necrosis due to poor vascularity.

In the reconstruction approach applied in this study, an axial flap was used and the blood supply was derived from the jugal branch of the infraorbital artery; furthermore, there were no signs of arterial impairment in any of the cases.

Conclusions

Reconstruction of a medium-sized lower eyelid defect with local modification of the nasolabial flap has the advantages of easy accessibility; quick donor site healing with minimal scarring; acceptable tightness of the flap in the new position with no ectropion, entropion, or epiphora; and limited complications and morbidity, combined with orbital ring fixation, which is associated with appropriate functional and cosmetic outcomes.

Conflicts of Interest

None.

References

- 1 Tatar S, Yontar Y, Özmen S. Superiorly based nasolabial island flap for reconstruction of the lateral lower eyelid. *Turk J Med Sci* 2017; 47(06):1673–1680

- 2 Chang EI, Esmaeli B, Butler CE. Eyelid reconstruction. *Plast Reconstr Surg* 2017;140(05):724e–735e
- 3 Karimnejad K, Walen S. Complications in eyelid surgery. *Facial Plast Surg Clin North Am* 2016;24(02):193–203
- 4 Niederhuber JE, Armitage JO, Doroshow JH, Kastan MB, Tepper JE. *Abeloff's Clinical Oncology E-Book*. London, United Kingdom: Elsevier Health Sciences; 2013
- 5 Bashour M. Lower eyelid reconstruction, entropion. *Ophthal Plast Reconstr Surg* 2007;14(05):95–103
- 6 Tenzel RR, Stewart WB. Eyelid reconstruction by the semicircle flap technique. *Ophthalmology* 1978;85(11):1164–1169
- 7 Ovidia S, Alabadi C. Hughes tarsoconjunctival flap. In: Tuan AT, Panthaki ZJ, Hoballah JJ, Thaller SR, eds. *Operative Dictations in Plastic and Reconstructive Surgery*. New York, NY: Springer; 2017:307–310
- 8 Elliot D, Britto JA. Tripiet's innervated myocutaneous flap 1889. *Br J Plast Surg* 2004;57(06):543–549
- 9 Alghoul M, Pacella SJ, McClellan WT, Codner MA. Eyelid reconstruction. *Plast Reconstr Surg* 2013;132(02):288e–302e
- 10 Barba-Gómez J, Zuñiga-Mendoza O, Iñiguez-Briseño I, et al. Total lower-eyelid reconstruction: modified Fricke's cheek flap. *J Plast Reconstr Aesthet Surg* 2011;64(11):1430–1435
- 11 Mathes SJ, Hentz VR. *Plastic Surgery* (8 volume set). Philadelphia, PA: Saunders Elsevier; 2006
- 12 Siegel RJ. Palatal grafts for eyelid reconstruction. *Plast Reconstr Surg* 1985;76(03):411–414
- 13 Nakajima T, Yoshimura Y, Kami T. The subcutaneous pedicle flap: widening of its applications. *Ann Plast Surg* 1987;19(02):103–116
- 14 Yoshimura Y, Nakajima T, Yoneda K. Reconstruction of the entire upper eyelid area with a subcutaneous pedicle flap based on the orbicularis oculi muscle. *Plast Reconstr Surg* 1991;88(01):136–139
- 15 Spinelli HM, Jelks GW. Periocular reconstruction: a systematic approach. *Plast Reconstr Surg* 1993;91(06):1017–1024, discussion 1025–1026
- 16 Goldstein MH. "Orbiting the orbicularis"—restoration of muscle-ripping continuity with myocutaneous flaps. *Plast Reconstr Surg* 1983;72(03):294–301
- 17 Guerrissi JO. Surgical reconstruction of the palpebral border: upper lid eyebrow–musculocutaneous island flap. *Plast Reconstr Surg* 2005;115(04):1118–1123
- 18 Rubin P, Mykula R, Griffiths RW. Ectropion following excision of lower eyelid tumours and full thickness skin graft repair. *Br J Plast Surg* 2005;58(03):353–360
- 19 Tei TM, Larsen J. Use of the subcutaneously based nasolabial flap in lower eyelid reconstruction. *Br J Plast Surg* 2003;56(04):420–423
- 20 Vayvada H, Menderes A, Tan O, Yilmaz M. Total lower eyelid reconstruction using paranasal flap. *J Craniofac Surg* 2006;17(05):1020–1026
- 21 Miyamoto J, Nakajima T, Nagasao T, et al. Full-thickness reconstruction of the eyelid with rotation flap based on orbicularis oculi muscle and palatal mucosal graft: long-term results in 12 cases. *J Plast Reconstr Aesthet Surg* 2009;62(11):1389–1394
- 22 Rustad TJ, Hartshorn DO, Clevens RA, Johnson TM, Baker SR. The subcutaneous pedicle flap in melolabial reconstruction. *Arch Otolaryngol Head Neck Surg* 1998;124(10):1163–1166



THIEME