

Successful Removal of a Rivet from the Heart of a Boy with Penetrating Cardiac Injury: A Case Report and Literature Review

Rahim Mahmudloo¹, Ahmad Jamei Khosroshahi², *Shahsanam Gheibi³

¹Associate Professor of Thorax Surgery, Department of Surgery, Urmia University of Medical Sciences, Urmia, Iran.

² Assistant Professor of Pediatric Cardiology, Department of Pediatrics, Tabriz University of Medical Sciences, Tabriz, Iran.

³Associate Professor of Pediatric Gastroenterology, Maternal and Childhood Obesity Research Center, Department of Pediatrics, Urmia University of Medical Sciences, Urmia, Iran.

Abstract

Introduction

Penetrating cardiac injuries generally occur secondary to gunshot or stab wounds and have a high mortality rate. They are rare and often fatal in children. When a foreign object penetrates the myocardium, it is dangerous to remove it, suddenly, and should be removed gradually to prevent excessive bleeding.

Case report

We report a case of an unusual penetrating cardiac injury in a 12-year-old boy with a rivet pushed into his sternum and penetrating the right ventricle. After the patient underwent sternotomy and pericardiotomy, the site of the rivet was exposed. A purse was then sutured around the rivet and tightened while pulling it out. The patient was discharged five days post-op, with normal echocardiography after 12 months. A review of the English-written literature revealed that this is the first case of heart trauma with rivet.

Key Words: Children, Heart injury, Penetrating cardiac injury.

*Corresponding Author:

Shahsanam Gheibi, MD, Associate Professor of Pediatric Gastroenterology, Maternal and Childhood Obesity Research Center, Shaheed Motahari Hospital, Urmia University of Medical Sciences, Kashani Ave, Urmia, Iran.
Email: drgheibi@yahoo.com; drgheibi@umsu.ac.ir

Received date: Oct 20, 2014 ; Accepted date: Oct 25, 2014

Introduction

Although chest trauma is uncommon during childhood, mortality rate and morbidity are high. Among pediatric trauma patients, 14.5% experienced cardiac trauma with a 39% mortality rate (1). Penetrating cardiac traumas in children are rare but usually prove fatal. Many of the patients are brought to the hospital in a state of shock or are dead at presentation (2). In cases of penetrating cardiac trauma, the anatomic position of the cardiac structures determines the severity of injury (e.g., anterior structures are more likely to be injured). In decreasing order of frequency, penetrating cardiac injuries involve the right ventricle, left ventricle, right atrium, and left atrium (3). Penetrating injuries to the heart include stab wounds, gunshot wounds, falling on an arrow, swallowed sewing needles, iatrogenic events, child abuse, and inward displacement of fractured ribs through chest trauma (4-6). A chest Computerized tomography (CT) scan is a potentially useful modality for evaluating cardiac injuries in high-risk, stable patients (7); this is the tool we use for detection of foreign body position. In searching the literature, penetrating cardiac injury with a rivet was found to be a unique occurrence.

Case presentation

A 12-year-old boy with a rivet clenching into his sternum had been referred to the emergency department of Imam Khomeini Hospital of Urmia City, West of Iran. Upon admission to Intensive care unit (ICU), he was conscious and responsive, although experiencing considerable chest pain. Also, he was not able to take a deep breath and had assumed a semi-bending position while sitting on the hospital bed. On physical examination, his blood pressure, respiratory, and heart rates were 110/60 mmHg, 18/min, and

100/min, respectively. A small, erythematous wound about 0.5×0.5 cm was seen on the distal third of the sternum (Figure.1).

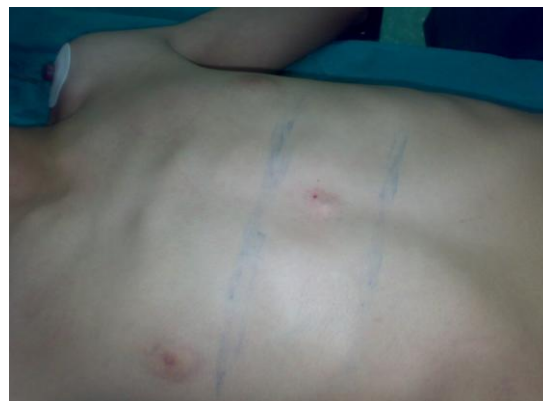

Fig.1: A small, erythematous wound on the distal third of the sternum.

His general condition was good without significant respiratory distress. No decreased breath or abnormal cardiac sounds were heard; no friction rub was detected. Third and fourth heart sounds were not heard. In other words, the patient's hemodynamic status and Electrocardiogram (ECG) were normal. On echocardiography no pericardial effusion was detected. Therefore, to evaluate the depth of the injury a noncontrast chest CT scan was done, whereupon a rivet, penetrating the heart under the sternum, was revealed (Figure.2).

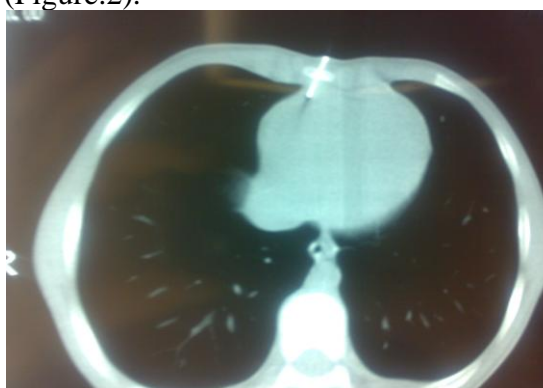


Fig.2: Penetrating Heart Injury with a Rivet

A sternotomy and pericardiectomy were then performed anterior to the phrenic

nerve. The penetration site of the rivet to the right ventricle was exposed, and a purse was sutured around the site using PROLENE 4-0, which we tightened while extracting the rivet (Figure.3).

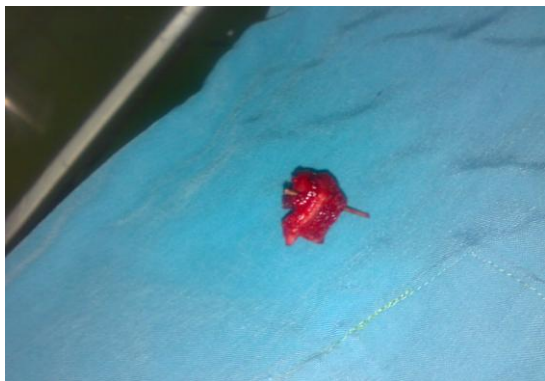

Fig.3: Extracting the Rivet and Sutured with Prolene 4-0

No bleeding was seen following the procedure, and after thoroughly exploring the site the pericardium and sternum were closed. The patient's postoperative course was uneventful, and on the fifth day postop echocardiography showed no abnormality, and the patient was discharged. On follow-up the patient had no problem, as repeat echocardiograms showed the cardiac septa, pericardium, and all four chambers to be completely normal after 6 and 12 months.

Discussion

We report the first case of penetrating heart injury due to rivet in children that removed successfully with careful and cautious. Although blunt trauma accounts for most injuries among the pediatric population, penetrating trauma is increasing among young adults of low socioeconomic status (8), teenagers, and even younger children (9). Penetrating cardiac injuries obviously result in high mortality rates (10). Rapid transport, proper resuscitation, and emergent surgery improved survival in patients with penetrating cardiac injuries (3). Immediate surgical intervention, a first-rate surgical

technique, and the ability to provide excellent postoperative critical care are all crucial to saving the life of a patient with a penetrating cardiac injury (11). Although CT scan-associated radiation may increase an individual's lifetime risk of developing cancer (12), selective CT chest scanning as a screening tool could be adopted (13). All stable patients with any suspected heart trauma should undergo CT scanning of the chest as well as echocardiography. Any blunt chest injury or penetrating wound of the thorax or upper abdomen should alert physicians to the possibility of cardiac injury (14). The hospital's emergency staff should be prepared and poised for prompt surgical exploration. Operative timing should be based on the patient's hemodynamic status and the presence of other life-threatening injuries (8). As in the case described, after suturing around the foreign body it should be removed gradually from the myocardium to prevent excessive bleeding.

Conclusion

Our experience shows that early diagnosis and immediate and suitable surgical intervention are the main life-saving factors in penetrating heart injuries and prevent disasters.

Financial Disclosure: None to disclose.

Conflict of Interest: None to report.

Funding/Support: There was no funding or support.

References

1. De Raet J, Mees U, Vandekerckhof J, Hendriks M. Penetrating pediatric cardiac trauma caused by fall on a pencil with normal echocardiography. *Interactive cardiovascular and thoracic surgery* 2004;3(4):634-6.
2. Goz M, Cakir O, Eren MN. Penetrating cardiac trauma in children. *Ulus Travma Acil Cerrahi Derg* 2010;16(3):220-4.

3. Dereli Y, Ozdemir R, Agris M, Oncel M, Hosgor K, Ozdis AS. Penetrating cardiac injuries: assessment of 21 patients. *Ulus Travma Acil Cerrahi Derg* 2012;18(5):441-5.
4. Clarke DL, Quazi MA, Reddy K, Thomson SR. Emergency operation for penetrating thoracic trauma in a metropolitan surgical service in South Africa. *The Journal of thoracic and cardiovascular surgery* 2011;142(3):563-8.
5. Sobnach S, Castillo F, Blanco Vinent R, Kahn D, Bhyat A. Penetrating cardiac injury following sewing needle ingestion. *Heart, lung & circulation* 2011;20(7):479-81.
6. Pometlova J, Pleva L, Sir M, Gloger J, Chmelova J. Right ventricular perforation by a rib fragment following blunt thoracic trauma. *Rozhl Chir* 2011;90(11):656-60.
7. Plurad DS, Bricker S, Van Natta TL, Neville A, Kim D, Bongard F, et al. Penetrating cardiac injury and the significance of chest computed tomography findings. *Emergency radiology* 2013;20(4):279-84.
8. Onan B, Demirhan R, Oz K, Onan IS. Cardiac and great vessel injuries after chest trauma: our 10-year experience. *Ulus Travma Acil Cerrahi Derg* 2011;17(5):423-9.
9. Smith G.A, Feltes TF. Cardiac Truma. In: Allen HD, Driscoll DJ, Shaddy RE, Feltes TF, editors. *Moss and Adams Heart Disease in Infants, Children and Adolescent*. 8th ed. Baltimore: Williams and Wilkins; 2013. p. 552.
10. Karigyo CJ, Fan OG, Rodrigues RJ, Tarasiewich MJ. Transfixing gunshot wound to the heart: case report. *Rev Bras Cir Cardiovasc* 2011;26(2):298-300.
11. Janati M, Bolandparvaz S, Salamina S, Johari HG, Sabet B, Kojuri J. Outcome of penetrating cardiac injuries in southern Iran, Shiraz. *Chinese journal of traumatology = Zhonghua chuang shang za zhi / Chinese Medical Association* 2013;16(2):89-93.
12. Sarma A, Heilbrun ME, Conner KE, Stevens SM, Woller SC, Elliott CG. Radiation and chest CT scan examinations: what do we know? *Chest* 2012;142(3):750-60.
13. Traub M, Stevenson M, McEvoy S, Briggs G, Lo SK, Leibman S, et al. The use of chest computed tomography versus chest X-ray in patients with major blunt trauma Injury 2007;38(1):43-7.
14. Kim YM, Yoo BW, Choi JY, Sul JH, Park YH. Traumatic ventricular septal defect in a 4-year-old boy after blunt chest injury. *Korean journal of pediatrics* 2011;54(2):86-9.