

OSTEOID OSTEOMA DISTAL PHALANX OF THE THUMB: A CASE REPORT AND REVIEW OF LITERATURE

Ahmadreza Afshar¹, Ali Tabrizi^{1}*

Received 08 May 2019, Accepted for publication 08 Aug 2019

Abstract

Osteoid osteoma is the third most common benign bone tumor. It is often seen in metaphysis and diaphysis of long bones especially femur and tibia. Osteoid osteoma is very rare in hand, thumb, and distal phalanx. In this report we present a 14-year-old patient suffering from painful swelling in the distal phalanx of thumb and clubbing. Radiography showed lucent's lesion with sclerotic margin. Laboratory findings were normal. There was no evidence confirming infection. After excision of the lesion, osteoid osteoma was confirmed based on pathological findings. One month after excision, the patient's pain was completely resolved. Based on this report, osteoid osteoma is one of the reasons for local painful swelling and finger clubbing. This is one of the main differential diagnoses of painful finger swelling which should always be considered. Surgical excision and lesion curettage are efficient methods in the treatment of phalangeal osteoid osteoma.

Keywords: Thumb, Hand, Osteoid osteoma

Address: Clinical Research Development Unit of Imam Khomeini Hospital, Urmia University of Medical Sciences, Urmia, Iran

Tel: + 9833457286

Email: Ali.tab.ms@gmail.com

Introduction

Osteoid osteoma is the third most common benign bone tumor (1). It is often seen in metaphysis and diaphysis of long bones especially femur and tibia (1). Many believe that this tumor is non-neoplastic. In 19 to 31% of all cases, osteoid osteoma occur in upper extremity (2). Among which hand and wrist were reported to be involved in 5-15% of the cases (2). This tumor is usually characterized by typical complaint of severe and unremitting pain, getting worse at night and dramatically being relieved by oral non-steroidal anti-inflammatory medications (NSAIDs). In radiography, it

can be determined by a small lucent with a diameter smaller than 1 cm and sclerosis around the lesion (called nidus) (2).

The proximal phalanx is the most common site of this tumor in hand while the involvement of metacarpals and distal phalanx are very rare (2, 3). The index finger is the most common site of occurrence while the thumb is rarely reported (2). In this report, we present a 14-year-old patient with painful inflammation on thumb distal phalanx.

Case report:

¹ Clinical Research Development Unit of Imam Khomeini Hospital, Urmia University of Medical Sciences, Urmia, Iran

² Clinical Research Development Unit of Imam Khomeini Hospital, Urmia University of Medical Sciences, Urmia, Iran (Corresponding Author)

The patient was a 14-year-old boy complaining about painful swelling in the thumb for 6 months and he was referred to our orthopedic clinic. He had no history of trauma or surgery. The distal phalanx swelling increased over the 6 months. He also mentioned severe pain at night which did not let him sleep. His pain was typically reduced and resolved by oral Diclofenac (25 mg). Functional ability of the patient's thumb was decreased. Severe swelling in comparison with the opposite thumb could be seen (Fig 1). The swelling was only in distal of the thumb and interphalangeal joint was intact. Interphalangeal joint movements were normal but painful. Patient felt severe pain by touching his nails. No symptoms of erythema or induration infection and abscess were found. Nail growth was normal but clubbing and enlargement were evident in distal phalanx and nail (Fig 1). Nervous examination of the thumb and capillary filling were normal.

Anterior-posterior radiography of the thumb showed a lucent lesion with sclerotic margin in the distal phalanx (Fig 2). The ulnar side of thumb in distal phalanx had cortical thinning. The lesion was not observable in

lateral view. Radiography also showed symptoms of soft tissue inflammation. Differential diagnosis were proposed based on radiography and the clinical findings were chronic osteomyelitis and osteoid osteoma. Blood cell count results were normal (white blood cell count of $8.8 \times 10,000/\text{mm}^3$ and rheumatoid factor=0, uric acid of 4.6 mg/dL, erythrocyte sedimentation rate (ESR) of 8 mm/h, C-reactive protein CRP 3.5 mg/dL). According to these laboratory results, infection was roll out.

The patient was considered as an excisional biopsy candidate. The surgery was carried out under local anesthesia with lidocaine 1% and finger tourniquet. The mass was removed from longitude incision in velar surface of the finger and the lesion curettage was carried out. The surrounding bone tissue (1-2 mm) was removed by high-speed burr to make sure on complete excursion of the lump. The removed fragment was sent to the lab for further histopathological examination. Histopathological investigations showed an irregular bony trabeculae amidst surrounding vascularised connective tissue which confirmed osteoid osteoma (fig 3). After one month, the pain was completely resolved.

Table 1. Case reports on phalangeal osteoid osteoma

Reports	Phalanges involvement	Symptoms	Treatment	outcome
Tsang DS et al. (2008) ¹⁰	18-year-old male with OO of the left ring finger	Tenderness and swelling	Complete surgical excision	No recurrence
Tsang DS et al. (2008) ¹⁰	38-year-old male distal phalanx of the right fourth	Painful enlargement and clubbing	Complete surgical excision	No recurrence
Galdi B et al.(2010) ²	18-year-old right-hand-thumb involved	pain with progressively increased in severity	Surgical excision of the lesion without bone grafting	No recurrence
Andalib et al.(2013)	A 27-year-old with OO in left middle finger	Chronic pain, nail enlargement and increase in size	En-block and Curettage	No recurrence
Jafari D et al.(2013) ⁵	Five cases with distal phalanges OO	Pain with gradually increased and initially intermittent	Curettage	In two cases (40%)
Gupta P et al.(2015) ³	A 36 year old with OO in left middle finger	pain without nocturnal increase and no local swelling	Surgical resection and curettage with high speed burr	No recurrence
Liu EH et al.(2017) ¹¹	56 cases 19.4% of hand involvement	pain and nocturnal pain	en bloc resection, curettage	No recurrence

OO: Osteoid Osteoma

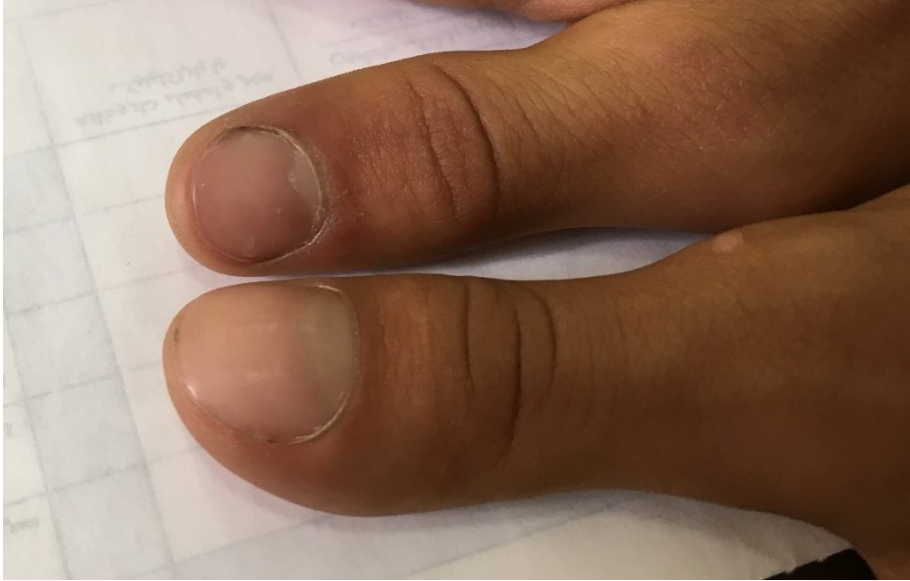

Fig 1. Clinical photo of the involved thumb, as it can be seen, it is swelling in comparison with opposite thumb and clubbing can be observed.

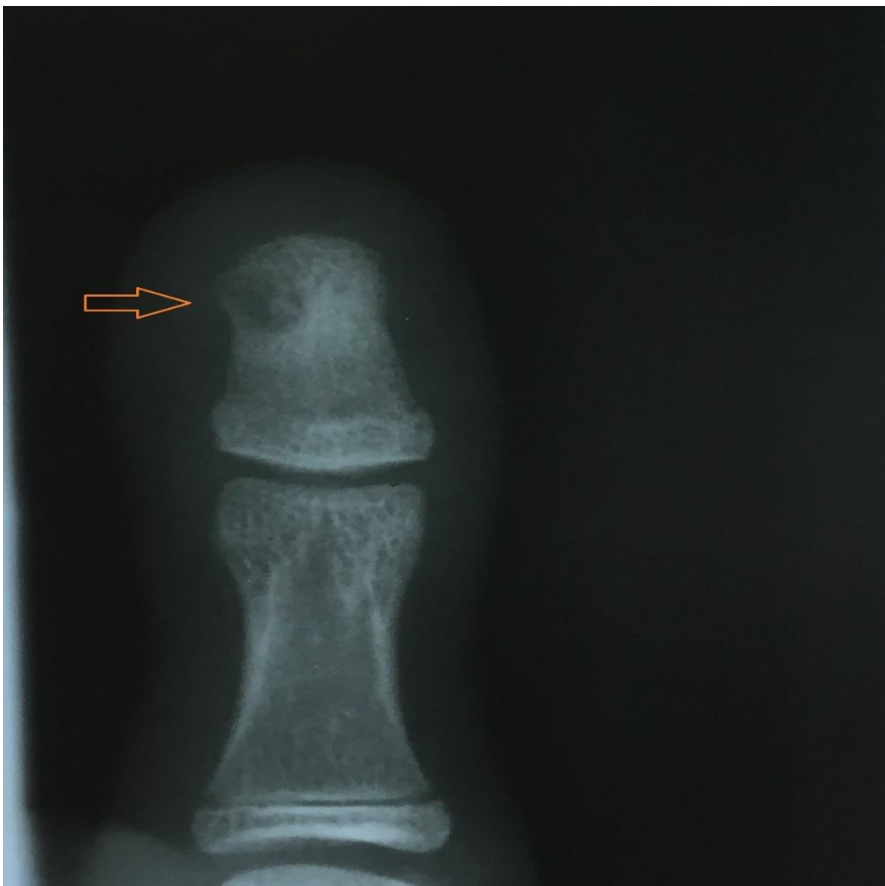

Fig 2. Anterior posterior view radiography of thumb indicating lucent lesion with sclerotic margins.

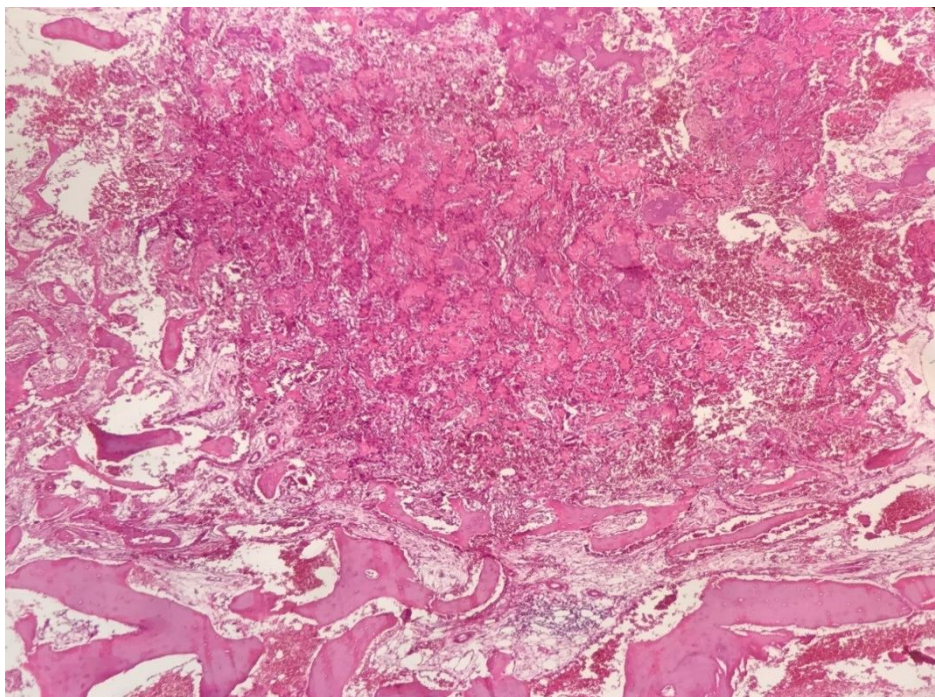


Fig 3. Histological section showing irregular trabeculae composed of osteoid and woven bone in a stroma of vascular connective tissue (haematoxylin and eosin, magnification 250×)

Discussion

Osteoid osteoma has an average incidence of 8% in hand (4), although it is seldom observed in phalanges and very rare in the thumb and its distal phalanx (2). Study of osteoid osteoma in the hand and wrist by Jafari et al. showed that 3 out of 25 cases had this lesion in their proximal phalanx of thumb (5). Galdi et al in 2010 described an 18-year-old man with thumb distal phalanx swelling (2). Nidus was observed in distal radiography of the thumb. Diagnosis of osteoid osteoma was confirmed after lesion excision through pathological investigations. The findings of the mentioned patient who was presented by night pain in distal phalanx was similar to our patient. In the report by Ramesh et al., 2 patients (24 and 28 years old) with a painful lesion in little and index fingers were diagnosed with osteoid osteoma. In these cases, overnight -painful swelling was a crucial sign for diagnosing osteoid osteoma (6). All of the reports in osteoid osteoma in distal phalanx are presented in Table 1. The most common symptoms on the fingers are pain and tenderness. Swelling and

enlargement of phalanx are reported in three case reports.

Distal phalanx osteoid osteoma could be successfully treated by surgical excision (6). Di Gennero et al. succeeded in complete cure of tumoral mass in thumb distal phalanx by surgical excision. The lesion had an increasing density in CT scan and osteolytic area (7). In this report, the treatment was initiated by assuming enchondroma, but then the findings were in favor of osteoid osteoma in thumb distal phalanx (7). Partial amputation of the distal phalanx was also mentioned as one of the treatment alternatives, however it cannot be applied to patients with osteoid osteoma (2). Disease symptoms would be completely resolved by surgical excision treatment in almost all the patient. Patient follow-up in different reports declared no recurrences (2). Clinical findings of hand and wrist osteoid osteoma mainly involve tenderness and soft tissue inflammations which are relatively more evident in this tumor (5). When the tumor is near to the joint, it can restrict the joint movements and mimic arthritis

symptoms (5). Fusiform swelling in the fingers, enlargement, and clubbing can be seen in phalanges which can help to diagnose osteoid osteoma. In our patient, clubbing and soft tissue swelling were completely typical (5, 8). The mechanisms of swelling and clubbing are not clear. But it seems that an inflammatory response to the hormones released from osteoid osteoma could be effective (5,8). Therefore, the response will cause connective tissue proliferation, bone alternations, and blood vessel dilation. In addition, created edema as a consequence of local hyperaemia and release of inflammatory factors can cause swelling. Moreover, edema increases the distance through which oxygen must diffuse before reaching the cells, this may cause a localized hypoxaemia. Such tissue hypoxia can result in enlargement and clubbing (8).

Differential diagnosis for hands and fingers which have symptoms similar to osteoid osteoma are syphilitic dactylitis, tuberculosis, other infection, brodie's abscess, enchondroma, post-traumatic change, osteochondroma, and soft tissue tumor. Therefore, accurate history, radiographic investigations and clinical examinations will be helpful in diagnosis (9).

Radiography analysis can typically determine the lesion in most cases and can show nidus. In phalanges, radiography can be helpful in 65% of the cases (2). In some cases, due to the small size of the lesion, it may not be seen in radiography. Limitation in the reactive bone surrounding the lesion may also hinder the diagnosis. In such cases, the misdiagnosis with diffuse swelling and inflammatory standing with osteomyelitis are probable. (2). Differential diagnosis based on radiography include enchondroma, subungual exostosis, osteochondroma, Brodie's abscess, acute osteomyelitis, and posttraumatic conditions. In these cases, Technitium bone scans and computed tomography (CT) are recommended (2).

Conclusion:

Osteoid osteoma is one of the common reasons for painful local swelling and clubbing in the fingers. It is one of the differential diagnoses which has to be considered. Surgical excision and nidus removal with lesion curettage are efficient in treatment osteoid osteoma of phalanges.

Conflict of Interest

There is no conflict of interest to disclose.

References

1. Pourfeizi HH, Sales JG, Elmi A, Tabrizi A. Osteoid osteoma of a scapula: a case report in a 34 years old woman. *Med J Islam Repub Iran* 2012;26(3):143-6.
2. Galdi B, Capo JT, Nourbakhsh A, Patterson F. Osteoid osteoma of the thumb: a case report. *Hand (N Y)* 2010;5(4):423-6.
3. Gupta P, Rammohan R, Maini L, Gautam VK, Khurana N. Osteoid Osteoma of the Metacarpal-A Case Report. *J Hand Microsurg* 2015;7(1):187-90.
4. Chronopoulos E, Xypnitos FN, Nikolaou VS, Efstathopoulos N, Korres D. Osteoid osteoma of a metacarpal bone: a case report and review of the literature. *J Med Case Rep* 2008;2:285.
5. Jafari D, Shariatzade H, Mazhar FN, Abbasgholizadeh B, Dashtebozorgh A. Osteoid osteoma of the hand and wrist: a report of 25 cases. *Med J Islam Repub Iran* 2013;27(2):62-6.
6. Ramesh P, Khan F, Kamboj H. Painful lesions at the fingertips. *J R Soc Med* 2004;97(1):30-1.
7. Di Gennaro GL, Lampasi M, Bosco A, et al. Osteoid osteoma of the distal thumb phalanx: a case report. *Chir Organi Mov* 2008;92(19052928):179-82.
8. Marcuzzi A, LetiAcciaro A, Landi A. Osteoid Osteoma of the hand and wrist. *J Hand surg* 2002; 27B: 440-443.
9. Burger IM, McCarthy EF. Phalangeal osteoid osteomas in the hand: a diagnostic problem. *Clin Orthop Relat Res* 2004;427:198-203.

10. Tsang DS, Wu DY. Osteoid osteoma of phalangeal bone. J Formos Med Assoc 2008;107(7):582-6.
11. Liu EH, Stone N, Alowami SO, Thoma A. Proximal

Phalanx Osteoid Osteoma: A Case Report and Literature Review. Plast Reconstr Surg Glob Open 2017;5(5):e1332.