




Contents lists available at ScienceDirect

Asian Pacific Journal of Tropical Disease

journal homepage: www.elsevier.com/locate/apjtd

Document heading

doi: 10.1016/S2222-1808(14)60508-9

© 2014 by the Asian Pacific Journal of Tropical Disease. All rights reserved.

Case report of oral cavity infestation in a 3-year old jackass with *Limnatis nilotica* from Ilam province, west of Iran

Mahmoud Bahmani^{1*}, Seyed Ahmad Karamati², Morteza Mohamad Hosseini Anari³, Amir Rahimirad¹, Jafar Asadzadeh¹, Aghakhan Kheiri¹, Ghader Hajjiglizadeh¹, Fereidoun Ghotbian⁴, Farzaneh Bahmani⁵

¹Urmia University of Medical Sciences, Urmia, Iran

²Department of Parasitology and Mycology, Faculty of Medicine, Urmia University of Medical Sciences, Urmia, Iran

³Shahrekord Branch, Islamic Azad University, Shahrekord, Iran

⁴Private Sector Veterinarian of Dehloran City, Ilam Province, Iran

⁵Department of Entomology, Ahvaz Jondishapour University of Medical Sciences, Ahvaz, Iran

PEER REVIEW

Peer reviewer

Prof. Dr. Baha Latif, Faculty of Medicine, UiTM, Sungai Buloh, Selangor, Malaysia.

Tel: +6 017 31 45649

Fax: +6 03 6126 7073

E-mail: bahalatif@yahoo.com

Comments

This is an interesting case report in which the authors studied an oral cavity infestation in a three years old jackass with *L. nilotica*. The necessary precautions to protect animals from infection with leeches by contaminated water should be carried out.

Details on Page 212

ABSTRACT

Leeches (phylum: Annelida, class: hirudinea) could infest wide range of livestock such as cow, buffalo, sheep, goat, horse, mule, ass, dog, pig and even human. In November 2013, a 3-year old jackass from Dehloran county, Ilam province, Iran, was infected through his mouth due to drinking spring water. Symptoms including stress, anxiety and tachycardia were seen. After examining oral cavity of jackass, a leech was observed in upper gum. The leech was measured after separation which was three inches in length. The leech was adult which has dark green with orange lines, and it was identified as *Limnatis nilotica* species. It seems that using spring, subterranean water, pond *etc.* is the main causes of livestock infestation with leech. Ranchers could be recommended to decontaminate leech waters to prevent further leech infestation cases.

KEYWORDS

Leech, *Limnatis nilotica*, Oral cavity, Gum, Jackass, Iran

1. Introduction

Leeches belong to the Annelida phylum and Hirudinea class[1]. They mainly live in freshwaters, while some species can be found in terrestrial area. One of their toxic species, *Limnatis nilotica* (*L. nilotica*), is an aquatic creature and lives in marine environments[2].

Most of leeches are hematophagous, which makes them predominantly blood suckers that feed on blood from vertebrate and invertebrate animals[3]. Almost 700 species of leeches have been described. Among them, 100 species are marine, 90 terrestrial and the rest of them live in freshwater[4].

The most important species of leeches include *L.*

*Corresponding author: Dr. Mahmoud Bahmani, Urmia University of Medical Sciences, Urmia, Iran.

Tel: 0984412772023

Fax: 0984412787412

E-mail: mahmood.bahmani@gmail.com;

Article history:

Received 2 Feb 2014

Received in revised form 10 Feb, 2nd revised form 14 Feb, 3rd revised form 18 Feb 2014

Accepted 29 Apr 2014

Available online 28 Jun 2014

nilotica, *Haemadipsa zylanica*, *Haemadipsa sylvestris*, *Hamadipsa picta*, *Myxobdella africana*, *Dinobdella ferox*, *Phytobdella catenifera*, and *Theromyzon tessulatum*[5–7].

L. nilotica is an aquatic leech which inhabits lakes and streams. It may enter the animal body through drinking from infested waters and most of them attach to the oral cavity or respiratory passages[1,8,9].

The major infestation complications by aquatic leech include anemia, difficulty in swallowing, breathing, cough, fever, chest pain, vomiting, bloody diarrhea and vaginal bleeding[10]. The cow, buffalo, sheep, goat, horse, mule, ass, dog, pig and human are often infested with leech[11,12]. Hirudiniasis is not common in animal and human[10].

The present study is a case report of infestation of a 3-year old jackass in Ilam province which located in the west of Iran.

2. Case report

In November 2013, a 3-year old jackass from Sangarnader village in Dehloran county, Ilam province, was infested by a number of leeches in his oral cavity upper gum. After examination and observation of the oral cavity, a leech with dark green and orange lines in lateral was determined. After removal of leech from the gum by rubbing dirt on the position, it was identified as *L. nilotica* (Figure 1). The strong jaws and muscular suckers at the anterior and posterior ends were observed. The leech had dark-green color surface with rows of green spots on the dorsal surface, and yellowish-orange and dark-green bands on either side with a 100 mm length, which was identified as *L. nilotica* species[13].

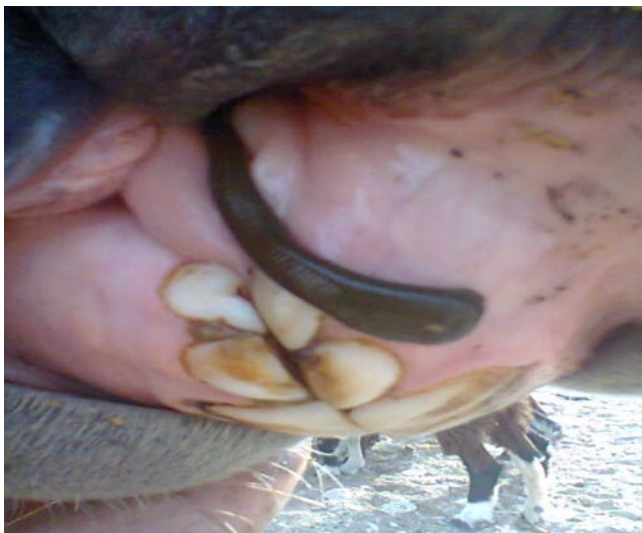

Figure 1. Attached *L. nilotica* to oral cavity of the 3-year old jackass.

The muscle suckers and strong jaws at the anterior and posterior ends, dark green surface colour with rows of dark green spots on the dorsal surface and the yellowish orange and green bands on both sides of a body with 30–100 mm length, were the main characters of the identification of *L. nilotica* species[10].

3. Discussion

The leeches are assumed as the agents of new emerging zoonotic diseases[11]. Several cases of leech infestation in cow, sheep, goat, lamb, goat, dog and chicken have been reported in Iran. The first report of leech infestation in sheep was reported in Dehloran city in Iran. In this report, the Kurdish breed's sheep was infested with leech of *L. nilotica*[10]. Bahmani *et al.* reported oral infestation of 3-year old pregnant cow with signs of increased temperature, increased heartbeat and respiration rate, incidence of anemia in normocytic and normochromic types along with leukocytosis and neutrophilia[13]. The first global report of oral hirudinea in chicken with *L. nilotica* has been reported in Ilam province, located in the west of Iran[14]. The report of oral infestation of a lamb and goat with leech of *L. nilotica* species has also been studied[15,16]. Bahmani *et al.* reported the infection of a male dog from Shahrekord (South–West of Iran), in which the complete interpret of leech infected blood test of dog showed about 3% anemia. The hemoglobin amount was reduced by 1 unit and fibrinogen was also determined three times over the normal range in which its reason was due to tissue damage caused by the leech. The amount of lymphocytes segments were also 75%, which has been indicated on a type of topical acute infection[17]. In the earlier studies, the reports of livestock's infection were in oral region[14–17]. In our study, the jackass was also infested in oral cavity. In the other parts of Iran, livestock infected by leech had been reported. Gharadaghi *et al.* reported a case of stillbirth in 4-year old pregnant goat due to leech[17].

The background of using spring, subterranean water, pond, *etc.* is the main causes of livestock infestation with leech. Ranchers are recommended to decontaminate leech infected waters to prevent infection cases.

Conflict of interest statement

We declare that we have no conflict of interest.

Acknowledgements

We are thankful for collaboration ranchers of the village and taking photographs for the report (Grant No. 777–1392–08–25).

Comments

Background

Leeches are common in animals and the infection takes place through drinking water contaminated with the larval stages of this parasite. The leeches usually attached to the oral cavity and respiratory passages.

Research frontiers

It is a case report showed the presence of aquatic leech *L. nilotica* in the oral cavity of a 3-year old jackass in Ilam province, Iran.

Related reports

Bahmani *et al.* (2010) have reported leech infestation in domestic animals such as *L. nilotica* infested in a pregnant cow in Ilam province in Iran and in a dog from Shahrekord.

Applications

More information about the distribution of leeches in different provinces of Iran has been reported. The necessary precautions to protect animals from infection with leeches by contaminated water should be carried out.

Peer review

This is an interesting case report in which the authors studied an oral cavity infestation in a three years old jackass with *L. nilotica*. The necessary precautions to protect animals from infection with leeches by contaminated water should be carried out.

References

- [1] Foonant S, Puntasri W, Manorot M, Niwasabutra S. A leech in the nasal cavity: case report. *Chiang Mai Med Bull* 2006; **45**: 27–30.
- [2] World Book Inc. *World book encyclopedia* 2013. Oxford: Raintree Publishers; 2013.
- [3] Davari MH. A case report of ophthalmorrhagia caused by leech attachment. *J Birjand Univ Med Sci* 2007; **14**(3): 9–15.
- [4] Sket B, Trontelj P. Global diversity of leeches (Hirudinea) in freshwater. *Hydrobiologia* 2008; **595**(1): 129–137.
- [5] Bahmani M, Rasouli M, Parsaei P, Bahnihabib EK, Saki K, Ghotbian F. Case report: *Limnatis nilotica* infestation in ram and kid in Dehloran City, Ilam province, West of Iran. *Asian Pac J Trop Dis* 2013; **3**(2): 155–157.
- [6] Vera C, Blu A, Torres M. [Leeches, today and yesterday presentpasitwd]. *Rev Chilena Infectol* 2005; **22**(1): 32–37. Spanish.
- [7] Hamilton RG, Levy JH, Marder VJ, Sane DC. Interference of thrombin in immunological assays for hirudin specific antibodies. *J Immunol Methods* 2012; **381**(1–2): 50–58.
- [8] Guerrant RL, Walker DH, Weller PF. *Essentials of tropical infectious diseases*. Philadelphia: Churchill Livingstone; 2001, p. 607–608.
- [9] Stickland G. *Hunter's tropical medicine and emerging infectious disease*. 8th ed. Philadelphia: W.B. Saunders Company; 2000, p. 895.
- [10] Bahmani M, Zamani P, Meshgi B, Zadeh AR. The first reported infestation in sheep at *Limnatis nilotica* in Iran. Sixth National Conference and the First Regional Congress of Parasitology and Parasitic Diseases. Karaj; 2006, p. 384.
- [11] Bahmani M, Avijgan M, Hosseini SR, Qorbani M. Evaluating the anti *Limnatis nilotica* effects of tobacco methanol extract compared with succinyl choline and some other anti-parasite drugs. *J Shahrekord Univ Med Sci* 2010; **12**(3): 53–59.
- [12] Cheikh-Rouhou F, Besbes M, Makni F, Chaabouni M, Ayadi A. [*Limnatis nilotica*, cause of severe anemia in an infant]. *Med Trop (Mars)* 2000; **60**(1): 100–101. French.
- [13] Bahmani M, Eftekhari Z, Mohsezaadeghan A, Ghotbian F, Alighazi N. Leech (*Limnatis nilotica*) causing respiratory distress in a pregnant cow in Ilam province in Iran. *Comp Clin Pathol* 2012; **21**: 501–503.
- [14] Bahmani M, Golshahi H, Ghotbian H, Bahmani F. Internal hirudiniasis in a hen (*Gallus gallusdomesticus*) – the first report in literature. *Asian Pac J Trop Dis* 2013; **3**(3): 232–234.
- [15] Bahmani M, Nekoe SH, Parsaei P, Saki K, Banihabib EK. Contamination reporting with *Limnatis nilotica* in a dog from Shahrekord. *JMVR* 2010; **2**(6): 29–32.
- [16] Rajaei SM, Khorram H, Ansari Mood M, Mashhadi Rafie S, Williams DL. Oral infestation with leech *Limnatis nilotica* in two mixed-breed dogs. *J Small Anim Pract*. 2013; doi: 10.1111/jsap.12166.
- [17] Gharedaghi Y, Elmirazeli V, Yeganehzad M. Clinical report a rare case of stillbirth goat due to leech. *J Vet Med Islamic Azad Univ Tabriz* 2010; **2**(4): 817–820.