

## The Effect of Curcumin on Functional and Structural Alterations of the Liver in Rats after MDMA Consumption

Naser Khalaji, Ph.D. <sup>1</sup>, Mohammad Hasan Khadem Ansari, Ph.D. <sup>2</sup>, Maryam Pourheydar, Ph.D. <sup>3</sup>, Mehdi Hasanpour, M.D. <sup>3</sup>, Sina Dindarian, M.D. <sup>3</sup>, Mehdi Bagheri, M.D. <sup>3</sup>, Leila Chodari, Ph.D. <sup>4</sup>

1- Department of Physiology, Faculty of Medicine, Urmia University of Medical Sciences, Urmia, Iran

2- Department of Biochemistry, Faculty of Medicine, Urmia University of Medical Sciences, Urmia, Iran

3- Faculty of Medicine, Urmia University of Medical Sciences, Urmia, Iran

4- Department of Physiology, Faculty of Medicine, Urmia University of Medical Sciences, Urmia, Iran (Corresponding author; E-mail: lchodari@yahoo.com)

Received: 13 March, 2019

Accepted: 14 December, 2019

### ARTICLE INFO

#### Article type:

Original Article

#### Keywords:

Liver  
MDMA  
Curcumin  
Rat

### Abstract

**Background:** Nowadays, one of the problems of human beings is drug addiction, which causes individual, economic and social damages. One of the most commonly used substances in parties is ecstasy pills or 3, 4-methylenedioxymethamphetamine (MDMA). This study seeks to assess the effect of curcumin in complications of ecstasy on liver tissue in rats.

**Methods:** 48 male Wistar rats in six groups were treated with curcumin (20  $\mu$  mol/kg) and MDMA (20 mg/kg) simultaneously and non-simultaneously. At the end of the experiment, blood samples were collected, lipid profile, liver enzymes were measured and morphology of liver was done.

**Results:** MDMA consumption had adverse effect on lipid profile in comparison to the control group. Treatment of curcumin with MDMA consumption improved this effect of MDMA on lipid profile. Moreover, curcumin treatment concurrent with MDMA consumption increased liver enzymes, whereas consumption of MDMA for 15 days and curcumin treatment in the next 15 days decreased liver enzymes.

**Conclusion:** Our findings suggest that simultaneous consumption of MDMA and curcumin have a synergistic adverse effect on liver enzymes and liver tissue. It is assumed that MDMA intestinal absorption increased by curcumin. While non-simultaneous treatment of curcumin and MDMA improved undesirable effects of MDMA on liver that is assumed by antioxidant capabilities of curcumin.

### Introduction

MDMA (3,4-Methylenedioxymethamphetamine) is an entertaining drug of abuse with toxic potential toward most tissues including the liver (1).

MDMA was produced by Merck pharmaceutical company in 1912 under the name "methysafrylamin" (1). It was planned to be used for decreasing appetite but failed (2). After the

consumption of ecstasy, psychological changes including euphoria, high self-confidence and power (3), being awake, sexual arousal, abnormalities in perception and mental awareness, and hallucination (4) are experienced. Physical complications of ecstasy include tachycardia, hypertension, blood coagulation, muscular stiffness, uncontrolled clump of teeth, nausea, blurred vision, syncope, shivering, and sweating

(5). After oral consumption of MDMA, it is immediately absorbed from digestive system and its maximum level of blood concentration occurs 2 hours after consumption (6). Metabolism of MDMA occurs in the liver by cytochrome P450 or CYP2D6 enzymes and MDMA is changed to methylenedioxyamphetamine (MDA). It is shown that MDA increases the peroxidation of lipids and decreases glutathione. Thus, it decreases the liver mitochondrial function and increased liver toxicity (7). Clinical observations showed that hepatotoxicity is the main toxicity caused by MDMA. In this sense, histologic experiments in some studies showed that MDMA induced toxicity ranges from mild hepatitis of the lobules to the collapse of the subdivisions of lobules (8). Also, an increase in the liver enzyme levels, alkaline phosphatase, bilirubin, and prothrombin following the use of MDMA has occurred (3). Clinical studies claim that the toxic effects of MDMA on the liver include jaundice, hepatomegaly, hepatitis, necrosis of the central lobules, fibrosis, and liver fail (9, 10). There are several factors related to the liver toxicity caused by MDMA which include MDMA metabolism, increased

dissemination of neurotransmitters, oxidation of biogenic Amines, and hyperthermia (11). Despite the control of MDMA misuse, it is still the second cause of liver injury in people below the age of 25 years and there is still no cure for the liver injury caused by MDMA (12).

Curcumin is the main substance of turmeric. Many invitro and invivo studies have suggested that it has antioxidant, antiinflammatory, antineoplastic, antimyeloid, and antiarthritic effects. Antioxidant effects of curcumin are proved to be ten times greater than vitamin E (13).

In view of what was said above, this study seeks to investigate the effect of curcumin on liver functional and morphologic harms caused by MDMA.

## Materials and Methods

### Animals

Experiments were carried out on 48 adult male Wistar rats (200±30g body weight). The animals were randomly divided into six groups (n=7):

**Table 1.** Experimental Design

Groups	Treatment ethyloleate 0.2 ml IP injection	Water 20mg/kg oral	MDMA 20 mg/kg oral	Curcumin 20 µ mol/kg IP injection	Treatment days	Simultaneous interventions	Non-simultaneous interventions
I	*	*			15	*	
II	*	*			30		*
III	*		*		15	*	
IV			*	*	15	*	
V	*		*		30		*
VI			*	*	30		*

All animal experiments were performed under the guidelines on human use and care of laboratory animals for biomedical research published by National Institutes of Health (8th ed., revised 2011) and conformed to the Declaration of Helsinki. The Ethics Committee of Urmia University approved the experimental protocol.

### Chemicals

Curcumin (Sigma Company for Chemicals, Iran) dissolved in ethylolate and administered (20  $\mu$  mol/kg) subcutaneously to rats. A stock solution of 3, 4-methylenedioxymethamphetamine (MDMA, Ecstasy) (Sigma Company for Chemicals, Iran) was prepared at 2ml distilled water and administered intragastrically at 20 mg/kg to rats (14).

### Sample preparation

At the end of treatments period, the rats were anesthetized by 10% chloral hydrate (0.5 mL/100g body weight, IP). The anesthesia depth was assessed by pinching a hind paw. At termination, after weighing the animals, the blood was collected from the heart in heparinized tubes, centrifuged at 1,000 g for 10 minutes so plasma separated and stored at  $-80^{\circ}\text{C}$  and livers were excised for histological analysis.

### Biochemistry Analysis

For biochemistry analysis, the collected blood without EDTA was centrifuged at 3500 rpm during 15 minutes to obtain the serum that was stored at  $-20^{\circ}\text{C}$ . The serum concentration of liver enzymes (alanine aminotransferase - ALT, aspartate aminotransferase - AST, and alkaline phosphatase - ALP, Lactate dehydrogenase\_ LDH) were determined by colorimetric assay using commercially available kits according to the manufacturer's instructions (Labtest Diagnóstica S.A., Lagoa Santa, MG, Brazil).

Biochemical parameters including total cholesterol (TC), triglycerides (TGs), high density lipoprotein-cholesterol (HDLc), and low density lipoproteincholesterol (LDLc) which were determined enzymatically on a COBAS FARA analyzer Roche Diagnostics, Switzerland) (15).

### Histopathological evaluation

For histology, tissue samples fixed in 10% buffered formalin were paraffin embedded for preparation of 5  $\mu$ m sections that were stained with Hematoxylin and eosin (H&E). The photomicrographs were taken using a binocular Zeiss® microscope (model Axioskop 2 plus).

### Statistical analysis

All values were analyzed by one-way and two-way analysis of variance (ANOVA), and the Tukey test was used to compare quantitative data. Values less than 0.05 were considered statistically significant in all cases. Results are expressed as means  $\pm$  SEM.

## Results

### Biochemical changes

#### Effects of MDMA Consumption and Curcumin Treatment on Lipid Profile

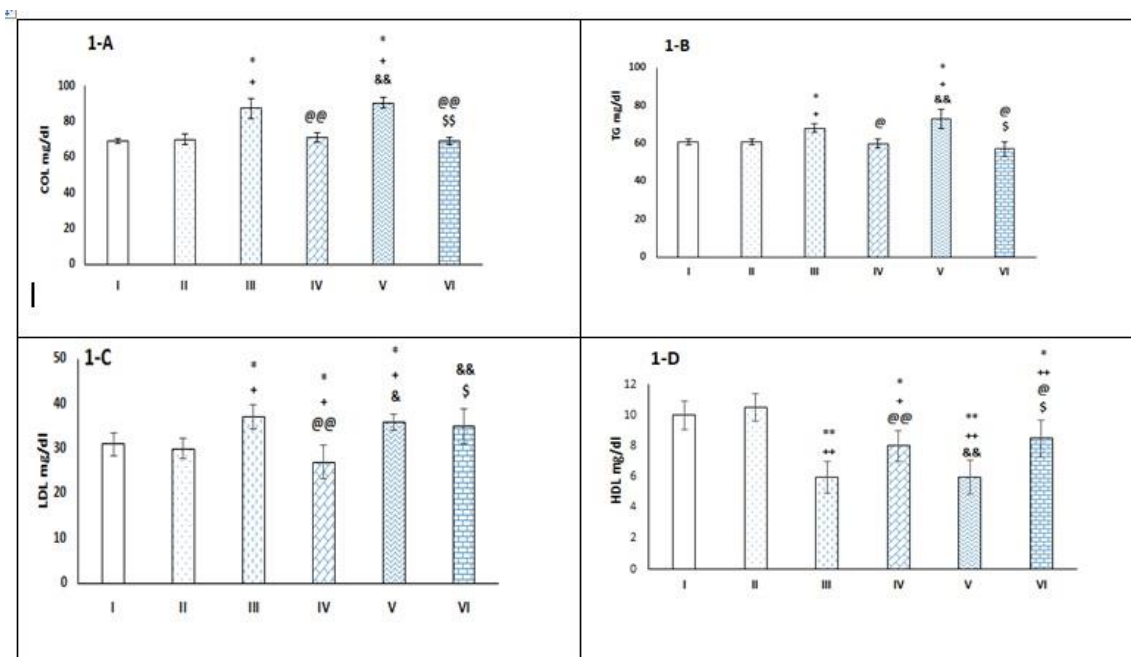
Figure 1 (A-D) shows the levels of cholesterol, triglycerides, HDL, and LDL in the serum of rats. As according to Fig 1A and B, 15 days of MDMA consumption significantly ( $p < 0.05$ ) increased cholesterol and TG levels in blood in comparison with the control group. Also, simultaneous consumption of MDMA and curcumin for 15 days (group IV) significantly decreased cholesterol ( $p < 0.01$ ) and TG ( $p < 0.05$ ) levels in blood in comparison with the group III and the amount of COL and TG in this group were found to be similar to that in the control animals.

Figure 1 (A and B) shows that 15 days of MDMA consumption and ethyloleate injection in the next 15 days significantly ( $p < 0.05$ ) increased cholesterol and TG levels in blood compared with the groups I, II ( $p < 0.05$ ) and IV ( $p < 0.01$ ). The one-way ANOVA showed that consumption of MDMA for 15 days and curcumin treatment in the next 15 days significantly decreased cholesterol ( $p < 0.01$ ) and TG ( $p < 0.05$ ) levels in blood compared with groups IV, V and the amount of COL and TG in this group were found to be similar to that in the control animals.

According to Fig 1C and D, 15 days of MDMA consumption significantly ( $p < 0.05$ ) increased LDL levels and diminished HDL ( $p < 0.01$ ) levels in blood in comparison to the

control groups. Also, simultaneous consumption of MDMA and curcumin for 15 days, significantly ( $p < 0.01$ ) decreased LDL and increased HDL levels in blood in comparison to the group III. Figure 1C and D show that 15 days of MDMA consumption and ethyl oleate injection in the next 15 days significantly increased LDL ( $p < 0.05$ ) and decreased HDL ( $p < 0.01$ ) levels in blood compared with the groups I, II and IV. The one-way ANOVA showed that the consumption of MDMA for 15 days and curcumin injection in the next 15 days significantly declined LDL ( $p < 0.01$ ) compared to groups IV ( $p < 0.05$ ) and V ( $p < 0.01$ ) and increased HDL ( $p < 0.05$ ) levels in blood compared to groups IV and V groups.

**Figure 1.** Effect of simultaneous and not-simultaneous curcumin treatment with MDMA consumption on cholesterol (Fig 1-A), TG (Fig 1-B), LDL (Fig 1-C), HDL (Fig 1-D) levels in the serum of different groups of study.



Data are expressed as mean  $\pm$  SEM for 7 animals. \* $p < 0.05$ , \*\*  $p < 0.01$  vs the group (I). ++  $p < 0.01$ , +  $p < 0.05$  vs the group (II). @  $p < 0.05$ , @@  $p < 0.01$  vs the group (III). &  $p < 0.05$ , &&  $p < 0.01$  vs the group (IV). \$  $p < 0.05$ , \$\$  $p < 0.01$  vs the group (V).

### Effects of MDMA Consumption and Curcumin Treatment on Liver Enzymes

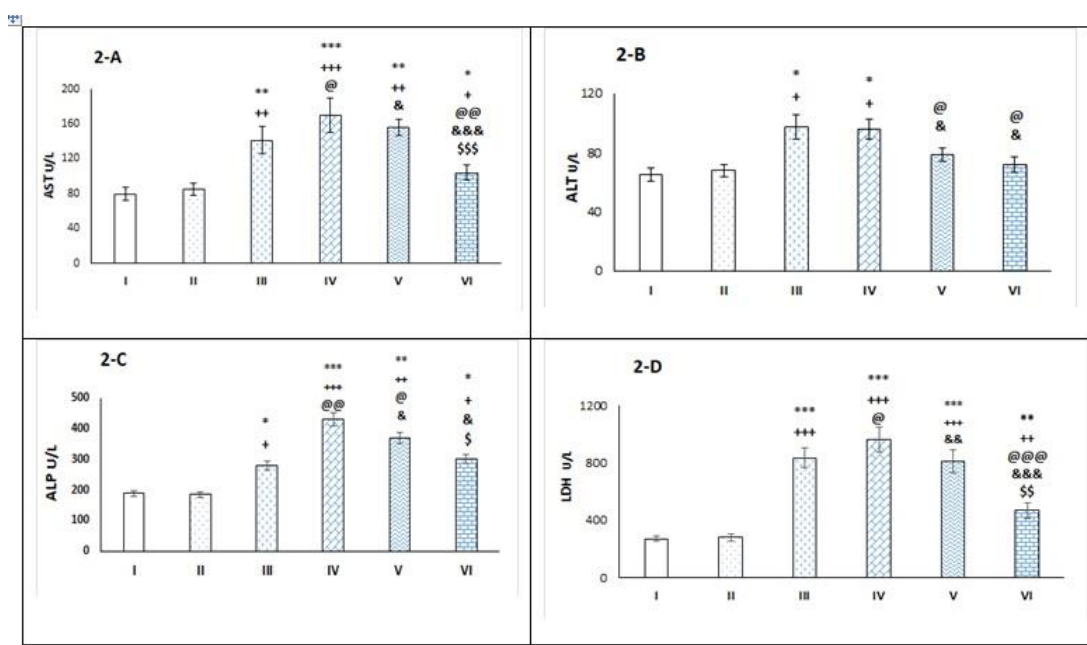
Figure 2 (A-D) shows the levels of liver enzymes in the blood of rats. One-way ANOVA showed that 15 days of MDMA consumption significantly increased AST ( $p<0.01$ ) and ALT ( $p<0.05$ ) levels in blood in comparison to the control groups (Figure 2 A-B). Also, simultaneously consumption of MDMA and curcumin for 15 days significantly increased AST ( $p<0.001$ ) compared to the control group ( $p<0.001$ ) and group III ( $p<0.05$ ) and significantly increased ALT compared to the control groups ( $p<0.05$ ) (Fig 2 A-B). Figure 2 A and 2 B shows that 15 days of MDMA consumption and ethyl oleate injection in the next 15 days significantly ( $p<0.05$ ) declined AST and ALT compared to IV group. The one-way ANOVA showed that consumption of MDMA for 15 days and curcumin injection in the next 15 days significantly decreased AST in compared to groups III ( $p<0.01$ ) IV ( $p<0.001$ ) and V ( $p<0.001$ ) groups and significantly ( $p<0.05$ ) decreased ALT levels in blood compared to groups III and IV groups.

As shown in Figure 2 C and D, 15 days of MDMA consumption significantly increased ALP ( $p<0.05$ ) and LDH

( $p<0.001$ ) levels in blood in comparison to the control groups. Also, simultaneous consumption of MDMA and curcumin for 15 days, significantly ( $p<0.01$ ) increased ALP levels in blood in comparison to the group III. Figure 2C shows that 15 days of MDMA consumption and ethyl oleate injection in the next 15 days significantly increased ALP ( $p<0.05$ ) compared to the group III and significantly decreased ALP ( $p<0.05$ ) compared to the group IV. Also, 15 days of MDMA consumption and curcumin injection in the next 15 days significantly ( $p<0.01$ ) diminished ALP levels compared to the group IV and V.

Fig. 2D shows that simultaneous consumption of MDMA and curcumin for 15 days, significantly increased LDH levels in blood in comparison with the group I,II ( $p<0.001$ ) and III ( $p<0.05$ ). The one-way ANOVA shows that 15 days of MDMA consumption and ethyl oleate injection in the next 15 days significantly increased LDH ( $p<0.001$ ) in comparison with the group I, II and IV ( $p<0.05$ ). Also, 15 days of MDMA consumption and curcumin injection in the next 15 days significantly reduced LDH levels in comparison with the group III, IV ( $p<0.001$ ) and V ( $p<0.01$ ).

**Figure 2.** Effect of simultaneous and not- simultaneous curcumin treatment with MDMA consumption on AST (Fig 2-A), ALT (Fig 2-B), ALP (Fig 2-C), LDH (Fig 2-D) levels in the serum of different groups of study.



Data are expressed as mean ± SEM for 7 animals. \*p<0.05, \*\* p<0.01, \*\*\*p<0.001 vs the group (I). ++ p<0.01, +++ p<0.001 vs the group (II). @ p<0.05, @@, p<0.01, @@@ p<0.001 vs the group (III). & p<0.05, && p<0.01, &&& p<0.001 vs the group (IV). \$ p<0.05, \$\$ p<0.01 vs the group (V).

### Effects of MDMA Consumption and Curcumin Treatment on Body Weight

Table 2 illustrates that 15 days of MDMA consumption resulted in a significant (p<0.001) decrease in body weight in group III compared to I and II groups. Also, simultaneous consumption of MDMA and curcumin for 15 days, significantly decreased body weight comparison with I, II groups (p<0.001) and III (p<0.01). Similarly, a significant decrease in body weight was observed in the group V compared to the I, II groups (p<0.001) and IV (p<0.01). However, the body weight in group V was found to be similar to that in the group III. Furthermore, 15 days of MDMA consumption and curcumin injection in the next 15 days significantly reduced body weight compared to the group I and, II (p<0.001) while

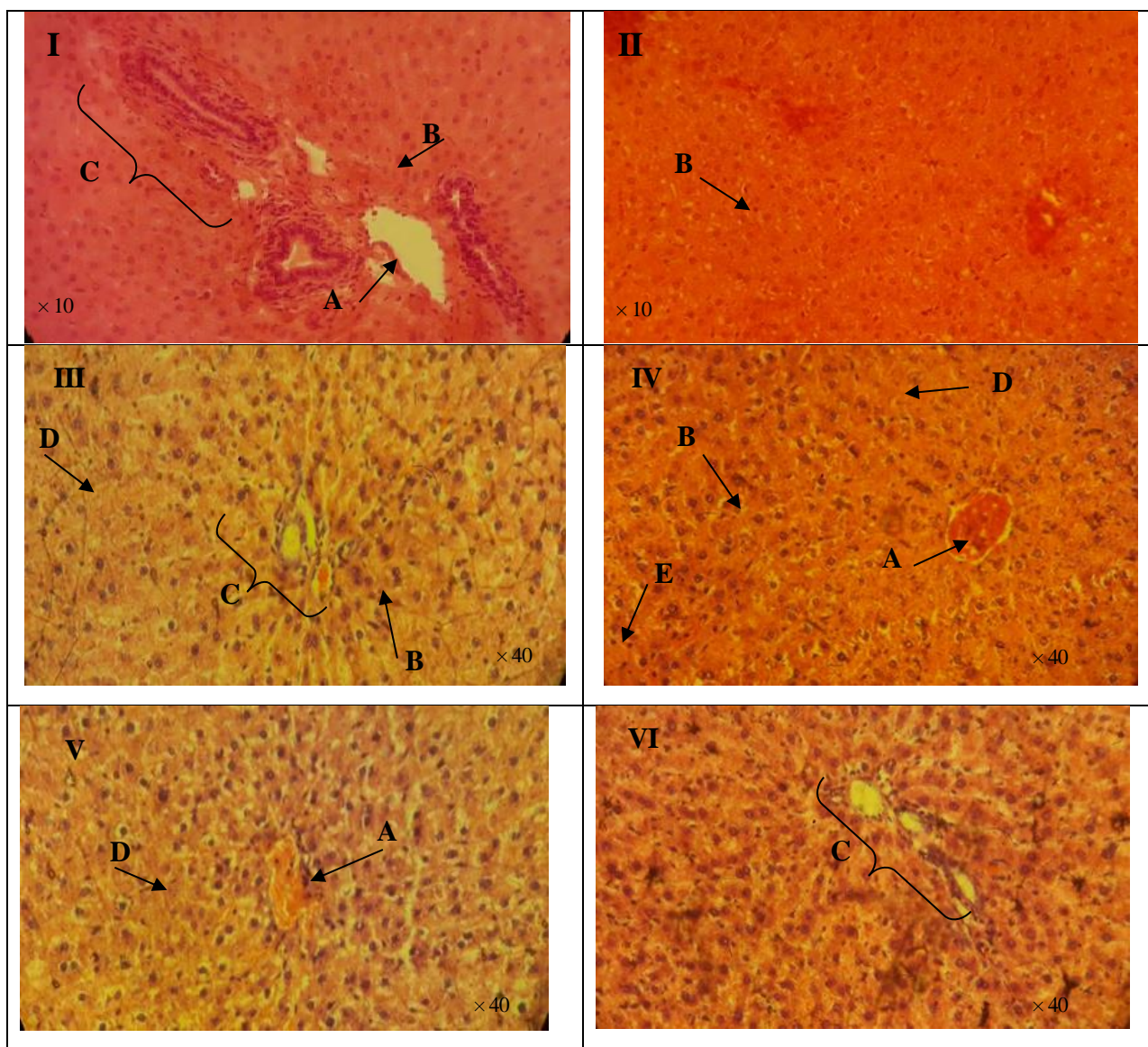
didn't observe any significant changes between this group with group V.

### Histopathological Findings

#### Effect of MDMA Consumption and Curcumin Treatment on Liver Tissue

Results from the liver tissue histopathological examination are given in Figure 3. In the MDMA treated groups III and V (MDMA treated groups) and group IV (simultaneously MDMA and curcumin treated groups), several histopathological changes such as interstitial edema, leukocyte infiltration, hepatocyte necrosis and congestion were observed. While, the mentioned histopathological changes in the group VI (non-simultaneously MDMA and curcumin treated groups) are less seen.

**Figure 3.** (I-V1): The histological light microscopy images of the liver tissue stained with hematoxylin and eosin (I – VI). Arrow A: Central hepatic vein, arrow B: Normal hepatocyte, Arrow C: Portal area, Arrow D: Necrosis, Arrow E: Lymphocyte,



**Discussion**

This study is the first to investigate the effects of curcumin treatment on the undesirable effects of MDMA on the liver tissue of rats. According to the experimental design, treatment

with curcumin was conducted in two ways: simultaneous curcumin treatment with MDMA or curcumin treatment for 15 days after consumption of MDMA for 15 days.

**Table 2.** Effect of simultaneous and non- simultaneous curcumin treatment with MDMA consumption on body weight in rats in each group.

G`roups	Body weight(before) (g)	Body weight (after) (g)	Change in body weight (%)
I	220± 5.8	235 ± 9.1	16.6 ± 2
II	216 ± 7.1	241 ± 6.4	17.04 ± 2.2
III	218 ± 6.5	210 ± 8.6 <sup>**++</sup>	-10.33 ± 1.02 <sup>***+++</sup>
IV	225 ± 9.7	200 ± 5.8 <sup>***+++</sup>	-20 ± 2.4 <sup>***+++@</sup>
V	227 ± 5.9	216 ± 2.2 <sup>***+++@</sup>	-13.48 ± 1.63a <sup>***+++&amp;&amp;</sup>
VI	220 ± 6.2	212 ± 2.1 <sup>**+&amp;</sup>	-13.14 ± 1.53a <sup>***+++&amp;&amp;</sup>

Body weight (before) indicates weights of animals before treatments. Body weight (after) indicates weights after treatment of simultaneously and not- simultaneously curcumin and MDMA. Change in body weight indicates percent of change in body weights after treatment of simultaneously and not- simultaneously curcumin and MDMA. Data are expressed as mean ± SEM for 7 animals. \*\* p<0.01 \*\*\*p<0.001 vs the group (I). + p<0.05, ++ p<0.01, +++ p<0.001 vs the group (II). @ p<0.05, @@, p<0.01 vs the group (III). & p<0.05, && p<0.01 vs the group (IV).

The results of the present study showed that simultaneous treatment of curcumin for 15 days with MDMA or after MDMA consumption improve adverse effects of MDMA on lipid profile. Moreover, our findings showed that concurrent treatment of MDMA group with curcumin significantly increased liver enzymes (ALT, AST, ALP, and LDH) in comparison to MDMA group but interestingly curcumin treatment after consumption of MDMA significantly decreased liver enzymes in compared to MDMA group. Furthermore, it was also demonstrated that the consumption of MDMA significantly decreased body weight in comparison with the control groups. Similarly, simultaneous treatment of curcumin for 15 days with MDMA significantly decreased body weight in comparison with the MDMA group. While, non-simultaneous treatment of curcumin with MDMA didn't make any significant change in body weight compared to the MDMA group. Our histological studies showed that simultaneous treatment of curcumin with MDMA enhanced the fibrosis, necrosis and inflammation in the liver tissue

compared to the MDMA group. However, curcumin treatment after consumption of MDMA decreased histopathological changes in the liver tissue due to MDMA intake.

The abuse of MDMA (ecstasy) is a growing issue in many parts of the world and represents a significant public health issue (16). This trend among teenagers and young adults, together with the widespread belief that "ecstasy" is a safe drug, has led to a thriving illicit traffic in it, even though these drugs have serious toxic effects (17). MDMA and related drugs are largely metabolized in liver by the cytochrome P450. The immediate product of this reaction is then processed further by other enzymes into a variety of secondary products, some of which are highly reactive with glutathione. The marked decrease in the level of free glutathione permits a series of biochemical changes (massive influx of calcium, oxidative change in the cell-membrane lipids, and so on) that results in cell death (18). An increasing body of evidence has revealed that the MDMA deleterious effects on liver is mediated by oxidative



stress and inflammation (19, 20). It has been reported that increased free radical production is leading to the formation of peroxides such as lipid-peroxidation, oxidation of DNA and proteins, and as well as pro-inflammatory factors that damages the cell membrane and the cell (21). Moreover, it has been shown that damage to the liver from alcohol, toxins, and certain drugs can also result in inflammation (22).

Consequently, considerable attention has been focused on the application of protective agents in MDMA consumption which can decrease these free radicals and thereby improve the oxidative damage to liver tissue. Frequent studies have described that active dietary components, such as phytochemicals, have promising cytoprotective effects in many pathological conditions (23, 24). Among these herbal medicines, curcumin has gained great attention and has been under research in our laboratory. Antioxidant and anti-inflammatory properties of curcumin supplementation are very well established by previous studies (25, 26). It is reported that curcumin increases the total antioxidant capacity and reduces lipid and protein oxidation as two main ROS generator sources in diabetics (27) and other oxidative stress conditions such as ethanol exposure (28). Also, curcumin can also regulates the expression of various proinflammatory cytokines including TNF, IL-1, IL-2, IL-6, IL-8, IL-12, and chemokines, most likely through inactivation of the transcription factor NF- $\kappa$ B (25, 26). However, no research on the effects of curcumin on adverse effect of MDMA consumption has been conducted so far. Thus, this study precisely aimed to fill this loophole.

In this study, it was demonstrated that MDMA administration damaged hepatocytes seriously, evidenced by masses of intracellular enzymes leaking into blood, such as AST, ALT, ALP and significant histopathological changes

(interstitial edema, leukocyte infiltration, hepatocyte necrosis and congestion). Hepatic tissues were the primary sites for the microsomal activation of the drugs. Hepatic activation of MDMA leading to the formation of toxic metabolite caused damage to liver tissue.

In agreement with the present study, previous studies have also shown that acute and repeated administration of MDMA caused a significant increase in liver enzymes levels in blood (29). The mechanisms underlying MDMA induced hepatotoxicity are multifactor. It is believed that induced hepatotoxicity after the consumption of MDMA is possibly related to a significant increase in ROS production and a marked decrease in the level of free glutathione (30). Also, it is shown that Kupffer cells as being central to a response to damage of liver released of an array of inflammatory mediators such as TNF- $\alpha$ , IL-1, and NO that exacerbates hepatotoxicity due to MDMA consumption.

Further, results of this study indicated that curcumin treatment after MDMA consumption could decrease liver enzymes in plasma. According to the antioxidant activity of curcumin, it is assumed that curcumin intake after MDMA consumption decreased oxidative stress, inflammation, hepatocytes damages and leakage of liver enzymes into blood. Opposing to our assumption, the study results also showed that curcumin co-treatment with MDMA increased the liver enzymes in the plasma. Thus, with regard to the adverse effects of curcumin in this case, we suppose that curcumin increases MDMA absorption from the intestinal tract in the co-treated group of curcumin with MDMA. Previous study indicates that curcumin has an increasing effect on bile production and a decreasing effect on stomach acid secretion (31). Accordingly, metabolism of the MDMA is decreased by the stomach

enzymes that resulted in an efficient increased absorption of MDMA in the small intestine (32). Moreover, we observed that the animals treated with MDMA showed a significant decrease in body weight during the period of treatment. It is reported that there is a linear relationship between MDMA consumption and weight loss. In this regard, it is shown that the effect of MDMA on body weight is mediated by the increasing effect of MDMA on thyroid hormone levels such as thyroxin. Also, our study has shown that curcumin co-treatment with MDMA had an additive decreasing effect on body weight. This is, in part, because curcumin increase adiponectin levels in blood. Many studies have found adiponectin to be inversely correlated with body mass index in patient populations.

In conclusion, based on the results of the current study, we suggest that MDMA consumption induces the enhancement of liver tissue abnormality factors such as the ones mentioned above along with structural changes. Administration of

curcumin along with MDMA showed elevated adverse effects of MDMA on liver functional and histological index. In this regard, we assume that curcumin has an additive effect on MDMA intestinal absorption. Moreover, observations of this study indicated that curcumin treatment after MDMA consumption has protective effects against elevation of liver enzymes and liver tissue histopathological changes due to MDMA consumption. This protective effect of curcumin treatment after MDMA intake can be justified with regard to its antioxidant properties.

### Acknowledgments

Support of this investigation by Urmia University of Medical Sciences, through a grant, is gratefully acknowledged.

### Conflict of interest

No conflict of interest relevant to this article was reported.

## References

1. Bernschneider-Reif S, Öxler F, Freudenmann R. The origin of MDMA ('ecstasy')—separating the facts from the myth. *Die Pharmazie-An International Journal of Pharmaceutical Sciences*. 2006;61(11):966-72.
2. Ghodse AH, Kreek M-J. A rave at Ecstasy. *Current Opinion in Psychiatry*. 1997;10(3):191-3.
3. Guneyssel O, Onur OE, Akoglu H, Denizbasi A. Ecstasy-induced recurrent toxic hepatitis in a young adult. *Current Therapeutic Research*. 2008;69(3):260-5.
4. Barrett SP, Darredeau C, Pihl RO. Patterns of simultaneous polysubstance use in drug using university students. *Human Psychopharmacology: Clinical and Experimental*. 2006;21(4):255-63.
5. TUFAN ZK, Bulut C, Kinikli S, Irmak H, YILMAZ GR, Demİröz AP. A Case Report of Ecstasy-induced Acute Hepatic Failure. *Turkish Journal of Medical Sciences*. 2006;36(5):319-21.
6. Mas M, Farré M, de la Torre R, Roset PN, Ortuño J, Segura J, et al. Cardiovascular and neuroendocrine effects and pharmacokinetics of 3, 4-methylenedioxymethamphetamine in humans. *Journal of Pharmacology and Experimental Therapeutics*. 1999;290(1):136-45.
7. Wu D, Otton SV, Inaba T, Kalow W, Sellers EM. Interactions of amphetamine analogs with human liver CYP2D6. *Biochemical pharmacology*. 1997;53(11):1605-12.

8. Carvalho M, Carvalho F, Remião F, de Lourdes Pereira M, Pires-das-Neves R, de Lourdes Bastos M. Effect of 3, 4-methylenedioxymethamphetamine ("ecstasy") on body temperature and liver antioxidant status in mice: influence of ambient temperature. *Archives of toxicology*. 2002;76(3):166-72.
9. Green AR, Mehan AO, Elliott JM, O'Shea E, Colado MI. The pharmacology and clinical pharmacology of 3, 4-methylenedioxymethamphetamine (MDMA, "ecstasy"). *Pharmacological reviews*. 2003;55(3):463-508.
10. Maurer HH, Kraemer T, Springer D, Staack RF. Chemistry, pharmacology, toxicology, and hepatic metabolism of designer drugs of the amphetamine (ecstasy), piperazine, and pyrrolidinophenone types: a synopsis. *Therapeutic drug monitoring*. 2004;26(2):127-31.
11. Pourahmad J, Eskandari MR, Nosrati M, Kobarfard F, Khajeamiri AR. Involvement of mitochondrial/lysosomal toxic cross-talk in ecstasy induced liver toxicity under hyperthermic condition. *European journal of pharmacology*. 2010;643(2):162-9.
12. Andreu V, Mas A, Bruguera M, Salmerón JM, Moreno V, Nogué S, et al. Ecstasy: a common cause of severe acute hepatotoxicity. *Journal of hepatology*. 1998;29(3):394-7.
13. Zhou H, S Beevers C, Huang S. The targets of curcumin. *Current drug targets*. 2011;12(3):332-47.
14. Connor TJ, McNamara MG, Finn D, Currid A, O'Malley M, Redmond AM, et al. Acute 3, 4-methylenedioxymethamphetamine (MDMA) administration produces a rapid and sustained suppression of immune function in the rat. *Immunopharmacology*. 1998;38(3):253-60.
15. Sedlak J, Lindsay RH. Estimation of total, protein-bound, and nonprotein sulfhydryl groups in tissue with Ellman's reagent. *Analytical biochemistry*. 1968;25:192-205.
16. Khalaji N, Namyari M, Rasmi Y, Pourjabali M, Chodari L. Protective effect of curcumin on fertility of rats after exposure to compact fluorescent lamps: An experimental study. *International Journal of Reproductive Biomedicine*. 2018;16(7):447.
17. Zaki NG, Abdel Kawy L. Chronic exposure to MDMA (ecstasy) induces DNA damage, impairs functional antioxidant cellular defenses, enhances the lipid peroxidation process and alters testes histopathology in male rat. *The Egyptian Journal of Hospital Medicine*. 2013;31(762):1-12.
18. Zhou S-F, Liu J-P, Chowbay B. Polymorphism of human cytochrome P450 enzymes and its clinical impact. *Drug metabolism reviews*. 2009;41(2):89-295.
19. Song B-J, Moon K-H, V Upreti V, D Eddington N, J Lee I. Mechanisms of MDMA (ecstasy)-induced oxidative stress, mitochondrial dysfunction, and organ damage. *Current pharmaceutical biotechnology*. 2010;11(5):434-43.
20. Valente M, Araújo A, Silva R, Bastos M, Carvalho F, de Pinho PG, et al. Hepatic oxidative stress induced by methylone and MDPV: A comparison to MDMA. *Toxicology Letters*. 2015;2(238):S265.
21. Halliwell B, Gutteridge JM. *Free radicals in biology and medicine*: Oxford University Press, USA; 2015.
22. Neuman MG. First international symposium on the molecular pathology and clinical aspects of the inflamed liver: alcohol and cytokines. *Clinical and Investigative Medicine*. 1998;21(6):283.
23. Surh YJ. Xenohormesis mechanisms underlying chemopreventive effects of some dietary phytochemicals. *Annals of the New York Academy of Sciences*. 2011;1229(1):1-6.

24. Tesoriere L, Allegra M, Butera D, Gentile C, Livrea M. Cytoprotective effects of the antioxidant phytochemical indicaxanthin in  $\beta$ -thalassemia red blood cells. *Free radical research*. 2006;40(7):753-61.
25. Jurenka JS. Anti-inflammatory properties of curcumin, a major constituent of *Curcuma longa*: a review of preclinical and clinical research. *Alternative medicine review*. 2009;14(2).
26. Maheshwari RK, Singh AK, Gaddipati J, Srimal RC. Multiple biological activities of curcumin: a short review. *Life sciences*. 2006;78(18):2081-7.
27. Xie Z, Wu B, Shen G, Li X, Wu Q. Curcumin alleviates liver oxidative stress in type 1 diabetic rats. *Molecular medicine reports*. 2018;17(1):103-8.
28. Bao W, Li K, Rong S, Yao P, Hao L, Ying C, et al. Curcumin alleviates ethanol-induced hepatocytes oxidative damage involving heme oxygenase-1 induction. *Journal of ethnopharmacology*. 2010;128(2):549-53.
29. Beitia G, Cobreros A, Sainz L, Cenarruzabeitia E. Ecstasy-induced toxicity in rat liver. *Liver International*. 2000;20(1):8-15.
30. Shahraki MR, Irani M. The effects of ecstasy on liver function tests, blood glucose, and lipids profile of male rats. *International journal of high risk behaviors & addiction*. 2014;3(4).
31. Swerdlow NR, Koob GF, Cador M, Lorang M, Hauger R. Pituitary-adrenal axis responses to acute amphetamine in the rat. *Pharmacology Biochemistry and Behavior*. 1993;45(3):629-37.
32. Sharma R, Gescher A, Steward W. Curcumin: the story so far. *European journal of cancer*. 2005;41(13):1955-68.