

CASE REPORT

Nail Psoriasis Triggered by the Reconstruction of Syndactyly

Ahmadreza Afshar, MD; Ali Tabrizi, MD

*Research performed at Imam Khomeini Hospital, Urmia University of Medical Sciences, Urmia, Iran**Received: 26 August 2016**Accepted: 19 October 2016***Abstract**

Koebner phenomenon is observed in a number of inflammatory skin diseases. Psoriasis is one of the most common skin diseases associated with Koebner phenomenon. Nail psoriasis may be developed independently from inflammatory arthritis and skin psoriasis. This study reports on the reconstruction of third web of a 30-year-old woman, which performed on her right, due to congenital syndactyly. Four months postoperatively, she developed nail dystrophy, onycholysis and onychorrhexis of the middle, ring and little fingernails. The clinical and histopathology findings were compatible with diagnosis of isolated nail psoriasis.

Keywords: Koebner phenomenon, Nail dystrophy, Nail psoriasis, Onycholysis, Syndactyly

Introduction

Psoriasis is one of the most inflammatory skin diseases inducing stress and morbidity (1). The most important clinical symptoms are associated with well-demarcated, scaling and erythematous plaques often located at extensor surfaces of knees and elbows (1). Nail is one of the areas that is involved in the disease (1). The prevalence of nail involvement in psoriasis patients is approximately 50% (1). It is estimated that 80-90% of patients with psoriasis will present with nail involvement at some point (2). For the first time, Koebner phenomenon was observed in psoriasis-like lesions following cutaneous trauma (3). More recently, the definition has been extended to include post-trauma lesions in patients with no pre-existing dermatosis (3). Koebner phenomenon likely occurs in 25% of patients with psoriasis after various traumatic injuries. However, these episodes may be left unrecognized (4).

Case report

A 30-year-old woman underwent reconstruction of third web of her right hand because of congenital syndactyly. The syndactyly was incomplete. The third and

fourth fingernails were not confluent and there was no interosseous connection. The reconstruction was limited to soft tissue. The routine pre-operative blood laboratory test (CBC) was normal for the elective hand surgery. Reconstruction was performed by creating a dorsal rectangular flap to cover the third web and matching volar and dorsal V-shaped flaps to cover the middle and ring fingers' sides. The skin defected areas were covered by full thickness skin grafts of the inguinal region.

Four months after the surgery, she developed nail dystrophy, onycholysis and onychorrhexis of the middle, ring and little fingernails. The fingernails had a yellow-greasy appearance. There were subungual hyperkeratoses [Figure 1]. She had no inflammatory arthritis and no other skin lesion. She referred to a dermatologist for further evaluations. The main differential diagnoses were nail psoriasis, onychomycosis and lichen planus. Periodic acid Schiff staining was negative for fungal elements. Rheumatoid factor was negative. There was no abnormality on the roentgenogram of her right hand. A biopsy from the ring finger's nail unit demonstrated increased nail plate thickness, hyperkeratosis, chronic

Corresponding Author: Ali Tabrizi, Imam Khomeini hospital, Urmia University of Medical sciences, Iran
Email: Ali.tab.ms@gmail.com



THE ONLINE VERSION OF THIS ARTICLE
ABJS.MUMS.AC.IR

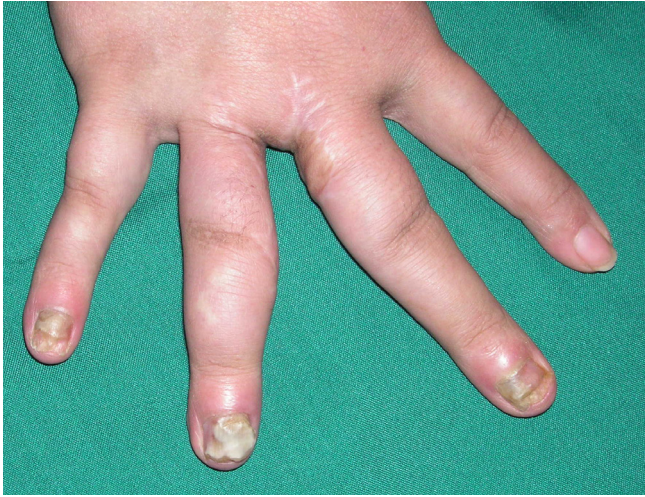

Figure 1. Nail dystrophy, onycholysis and onychorrhexis of middle, ring and little fingernails in the right hand four months after reconstruction of third web for syndactyly.

inflammatory cells and some vasodilatations. The clinical and histopathology findings were compatible with diagnosis of isolated nail psoriasis. Histopathologic sections show nail and skin tissue with psoriasis form accanthosis, heperkeratosis, elongated rete ridges, focal epidermal spongiosis, focal subepidermal vesicle formation, perivascular lymphocytic infiltration and fibrosis [Figures 2; 3].

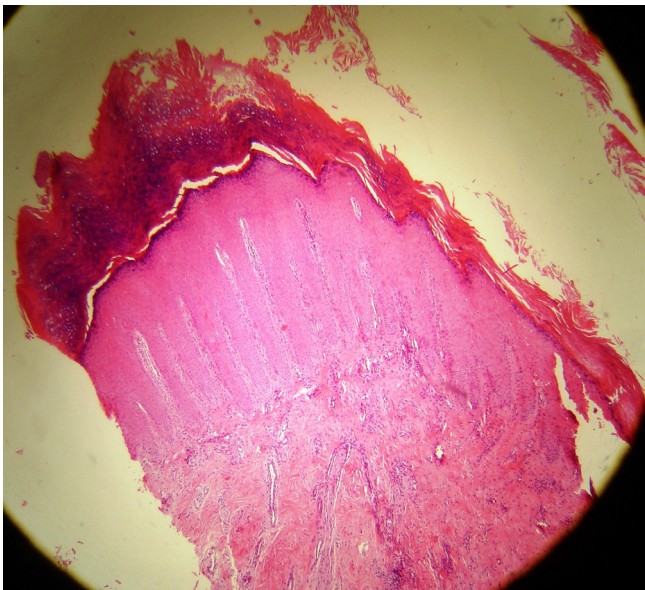


Figure 2. Histopathologic section shows skin tissue with psoriasis form accanthosis, heperkeratosis, elongated rete ridges, focal epidermal spongiosis, focal subepidermal vesicle formation, perivascular lymphocytic infiltration and fibrosis (H&E, Magnification X 40).

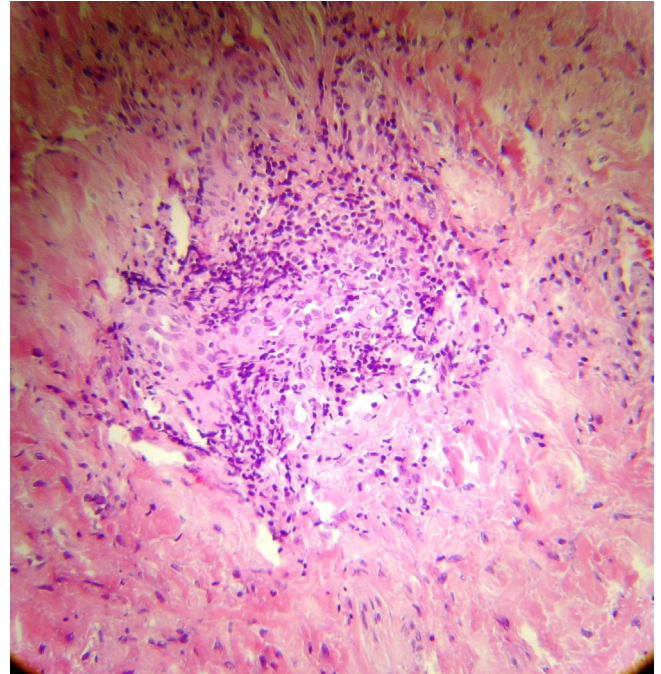


Figure 3. Section shows perivascular lymphocytic infiltration and fibrosis (H&E, Magnification X 400).

Discussion

Psoriasis may be detected by presence of skin and nail lesions, inflammatory arthritis, dactylitis, negative rheumatoid factor and juxta-articular bone formation. Nail lesions have been reported for about 90% of psoriatic patients (4). However, isolated nail psoriasis may be developed independently from inflammatory arthritis and skin psoriasis in 1-10% of psoriatic patients (4, 5). Koebner phenomenon is highly associated with nail psoriasis (5). For the first time, the German dermatologist, Heinrich Koebner, described appearance of psoriatic lesions in uninvolved skin of psoriatic patients following local trauma in 1877. The time period from injury to psoriatic lesion development varies, although it generally takes 10 to 20 days (4). For the phenomenon to occur, both epidermis and dermis need to be involved in the injury. According to the available evidences, there is not any exclusive reason for Koebner phenomenon anatomically (6). Psoriasis may develop due to injury, trauma, wound or irritation because of Koebner phenomenon (6). Stress may also trigger or aggravate the condition. Most reports of post-trauma psoriasis lesions are associated with patients having tattoos (7, 8).

Arias-Santiago reported a healthy 18-year-old man presented with skin lesions appeared on 2-week-old tattoos on his forearms (3). Koebner phenomenon may occur in patients without pre-existing dermatosis (3). According to Alolabi et al. report, Koebner phenomenon observed after breast reconstruction surgery (3). There are limited reports about occurrence of post-

operative Koebner phenomenon and the phenomenon has been observed following various types of surgeries including breast reductions and cosmetic procedures (9). For the first time, we reported about occurrence of Koebner phenomenon after hand surgery.

In this case, it may be hypothesized that hand surgery triggered a Koebner-like phenomenon induced development of nails lesions in the patient middle and little fingers as well as little finger that was not operated (10).

Currently, the patient's psoriasis is limited to the middle, ring and little fingers' nails of her right hand and she is on proper treatment by a dermatologist. However, she may develop psoriatic skin lesions and inflammatory arthritis in future.

Koebner phenomenon likely occurs in psoriasis patients. Although skin lesions caused by surgical trauma may initially occur in patients with no history of previous skin diseases, nail psoriasis occurring after surgery is

described as Koebner phenomenon. Nail psoriasis may develop independently from inflammatory arthritis and skin psoriasis.

There are no conflicts of interest.

Acknowledgments

This Study was supported by Urmia University of Medical Sciences, Urmia, Iran.

Ahmadreza Afshar MD

Ali Tabrizi MD

Department of Orthopedics, Imam Khomeini Hospital, Urmia University of Medical Sciences, Urmia, Iran

References

1. Pasch MC. Nail Psoriasis: A Review of Treatment Options. *Drugs*. 2016; 76 (6): 675-705.
2. Weiss G, Shemer A, Trau H. The Koebner phenomenon: review of the literature. *J Eur Acad Dermatol Venereol* 2002; 16 (3): 241-8.
3. Arias-Santiago S, Espiñeira-Carmona MJ, Aneiros-Fernández J. The Koebner phenomenon: psoriasis in tattoos. *CMAJ*. 2013; 185 (7): 585.
4. Dogra A, Arora AK. Nail psoriasis: the journey so far. *Indian J Dermatol*. 2014; 59(4): 319-33.
5. Schons KR, Knob CF, Murussi N, et al. Nail psoriasis: a review of the literature. *An Bras Dermatol*. 2014; 89(2): 312-7.
6. Orzan OA, Popa LG, Vexler ES, Olaru I, Voiculescu VM, Bumbăcea RS. Tattoo-induced psoriasis. *J Med Life*. 2014; 7(2): 65-8.
7. Ghorpade A. Tattoo-induced psoriasis. *Int J Dermatol*. 2015; 54(10): 1180-2.
8. Alolabi N, White CP, Cin AD. The Koebner phenomenon and breast reconstruction: Psoriasis eruption along the surgical incision. *Can J Plast Surg*. 2011; 19(4): 143-4.
9. Bernstein EF, Kantor GR. Treatment-resistant psoriasis due to a mastectomy sleeve: An extensive Koebner response. *Cutis* 1992; 50(1): 65-7.
10. Ryan GM. Psoriatic arthritis and Koebner phenomenon. *J Hand Surg Am*. 1991; 16(1): 180-1.