

The Effect of Propolis-Gum Arabic as a Novel Nerve Guidance Channel on Regeneration of Sciatic Nerve in Male Rats

Mahsa NOSRATIYAN¹, Gholam Hossein FARJAH^{1,2}, Mojtaba KARIMIPOUR¹, Bagher POURHEIDAR¹

¹Urmia University of Medical Sciences, Faculty of Medicine, Department of Anatomy, Urmia, Iran

²Urmia University of Medical Sciences, Neurophysiology Research Center, Urmia, Iran

Corresponding author: Gholam Hossein FARJAH ✉ farjah.gh@UMSU.ac.ir, hfarjah@hotmail.com

ABSTRACT

AIM: To investigate the effect of Propolis-gum Arabic as nerve guidance channel.

MATERIAL and METHODS: Male rats (n=24) were randomly divided into sham surgery, autograft, and Propolis+gum Arabic groups with equal numbers. Under anesthesia, the sciatic nerve was removed, and the gap between the two ending was repaired by Propolis-gum Arabic or nerve autograft. Nerve regeneration was evaluated by sciatic function index (SFI), withdrawal reflex latency (WRL), muscle fiber diameter, number of myelinated axons, myelinated fiber diameter, and immunohistochemical analysis.

RESULTS: At 30, 49, 60 and 90 days after surgery, the mean of SFI in Propolis + gum Arabic group was significantly greater than the autograft group ($p<0.03$). The mean muscle fiber diameters (30 and 90 days after surgery) and the mean number of myelinated axons (90 days after surgery) in Propolis + gum Arabic group were significantly greater than autograft group ($p<0.05$). In addition, 90 days after surgery, the mean myelinated fiber diameter in Propolis + gum Arabic group was significantly higher than autograft group ($p<0.05$).

CONCLUSION: The results of this study suggest that as guidance channel, the Propolis + gum Arabic may be useful in peripheral nerve regeneration.

KEYWORDS: Propolis, Gum Arabic, Nerve regeneration, Nerve guidance channel, Sciatic nerve

INTRODUCTION

The injuries to peripheral nerves are popular which may result in the loss of sensory and motor function in upper and lower extremity. When the distance between the cut ends of the nerve increases more than 2-3 centimeters, Autograft is considered the standard procedure. However, this procedure causes such unwanted side effects, including: neuroma formation, sensory disturbance in the nerve donor area, and longer surgical duration (8).

Therefore, studies are needed to introduce the appropriate nerve guidance channel (NGCs) as a surrogate for nerve Autograft. Previous studies have used a number of materials (simple or combined form) as NGCs, some of which include collagen (9), combination of hyaluronic acid and silk fibroin (25), and polyurethane (29).

An ideal NGC should include the following features: directing axonal regeneration from the proximal end of the channel to the distal end, preventing the release of growth factors secreted from the injured nerve ends of the channel wall, attenuation of scar tissue formation at the site of nerve injury, and easy operation (29).

Gum is a combination of carbohydrates that can bind to water and form gels (5). Gum Arabic (GA) is a natural material derived from the Acacia Senegal used as an additive in food (E414), and consists of a mixture of protein chains that bind to polysaccharides (6). Several studies have emphasized that GA has anti-inflammatory and antioxidant properties (13, 26).

Earlier research has showed that GA has a protective effect against numerous diseases, including cardiovascular disease (4), sickle cell anemia (15), and chronic kidney disease (2).

Propolis (bee glue) consists of waxes, plant resins, and essential oils. It is rich in antioxidant compounds (mainly phenolics and flavonoids) so that it can be effective in reducing the damage caused by oxidative stress and inflammatory processes (23).

Previous study show that Propolis may effectively repair skin burns (18), protect retinal ganglion cells in ischemic retina (24), prevent neuron apoptosis after brain injury (32), and repair crushed sciatic nerve (7,34).

Based on the physical properties of gum Arabic and Propolis, neither can form the nerve guidance channel per se. Due to their anti-inflammatory and antioxidant activities, the aim of this study was to evaluate the effect of gum Arabic and Propolis as NGC in comparison with autograft.

■ MATERIAL and METHODS

Animals

Twenty four adult males (Sprague-Dawley; 230-260 g) rats, were divided into three groups, including sham surgery, autograft, and Propolis+gum Arabic. The study was approved by the ethical committee of Urmia University of Medical Sciences [approved No: IR, UMSU.REC. 1396.397, date 7 Feb 2018].

Preparation of the Propolis-gum Arabic Nerve Guidance Channel

For the preparation of GA solution, 50 gr of GA (Merck, Germany) was dissolved in 50 ml distilled water and stirred for 30 min at room temperature. In order to the complete the hydration of GA, the container of the GA solution was covered with aluminum foil and kept in the refrigerator for 24 h. Propolis sample was collected from colonies of honey bees located in the Urmia, Iran (in the spring of 2019). The 50 g of Propolis was cut into small pieces and melted in a water bath (70 °C). The NGCs (1.7 mm in inner diameter, 12 mm in length) were made from three layers. First, the inner layer of the NGCs was formed by immersing a Teflon tube into the molten Propolis.

After cooling (in the refrigerator for 15-20 min), a fine hole was created on this layer. Then, the middle layer of NGCs was formed by immersing the Teflon tube coated with Propolis in the GA solution. After GA dried (in room temperature for 12 h), the channel was again immersed in the molten Propolis and the outer layer of NGCs was formed. The tube was stored in the refrigerator for 1 hour. Then the channel was separated from Teflon tube and sterilized with a formalin tablet for at least 24 hours. Samples were stored in the dark at 4 °C and used within 1 months of preparation.

Surgery Procedure

The rats were anesthetized (ketamine: 100 mg/kg; xylazine: 15 mg/kg, i.p.). In the sham surgery group, the left sciatic nerve was exposed. In the Propolis+Gum Arabic group, 10 mm of sciatic nerve was removed (just above the sciatic nerve bifurcation). Then, the nerve cut ends were implanted into the Propolis+Gum Arabic nerve guidance channel, and sutured to the channel wall (8-0 nylon); the NGCs were filled with normal saline afterwards (30 µl). Sterile wax was used to prevent leakage through the NGCs opening. In autograft, the nerve segment was again sutured to the two ends of the sciatic nerve. Finally, the skin and muscle were sutured (Figure 1A, B) (12).

Functional Evaluation of Hind Limbs

In order to ensure proper functioning of the hind limbs, all rats were evaluated one day before surgery. Then, the animals were evaluated regularly (7th, 21st, 30th, 49th, 60th, and 90th days post-operation). At first, the plantar surfaces of the rats (hind limbs) were soaked in black ink. Then, the animals were allowed to walk on white paper. The footprints were used to calculate the sciatic functional index (SFI) (5).

Withdrawal Reflex Latency (WRL)

The sensory nerve recovery was assessed by evaluating WRL at days 30 and 90y after surgery. For this purpose, the plantar surface of the hind limb each animal was placed on a hot plate

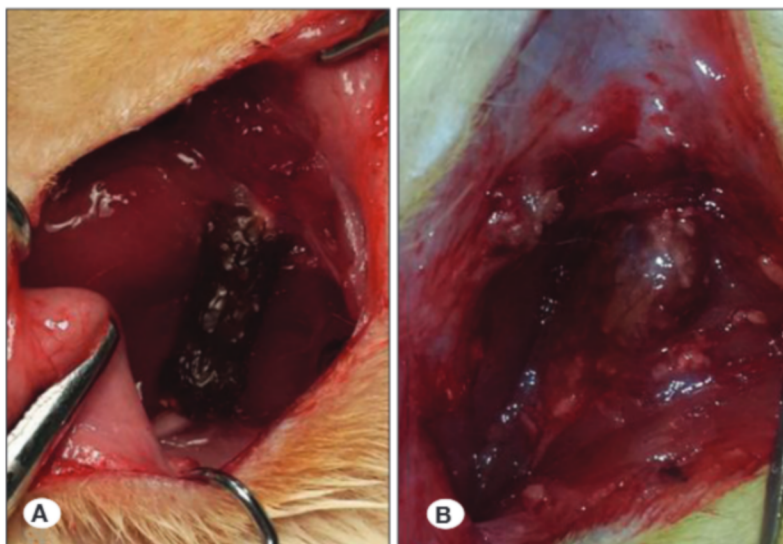


Figure 1: Implanted Propolis-gum Arabic nerve guidance channel on the sciatic nerve gap (1 cm). **A)** 30 and **B)** 90 days after surgery.

(DID SABZ, Model; DS8310; 56 °C). Then, the contact time of the hind limb with the surface of the hot plate was recorded. In order to prevent injury to the animal's foot, the maximum contact of the animal's foot with the hot plate was assumed to be 10 s (17).

Muscle Weight

In each group, the rats in the 30 and the 90 day after surgery were anesthetized (ketamine & xylazine). Then, the gastrocnemius muscles were perfectly separated from the bone, and the wet weight of muscle was measured by digital scale (11).

Histologic Evaluation

After measuring gastrocnemius muscle weight, the muscle-cross sections were stained with H-E. Then, the diameter of muscle fibers was measured with a calibrated eyepiece. Also, the middle segment of the sciatic nerve was removed, and stained with toluidine blue. In the nerve cross-section, the total myelinated fibers were counted. In addition, the thickness of myelin and the diameter of myelinated axons were calculated with the aid of the calibrated eyepiece (12).

Immunohistochemistry

In this study, an anti S-100 (Dako, 1:200 dilution) was used to determine the Schwann cell sheath. After blocking non-specific immunoreaction in the paraffin nerve sections (4 μ m cross sections) and incubating the samples in S-100 protein antibody solutions, secondary antibody solution (Horseradish peroxidase-labelled) was added for 15-20 min. Then the sections were washed with saline phosphate buffer saline (PBS), and the number of S-100 positive Schwann cells was counted in a blind fashion and under a light microscope (10).

Statistical Analysis

All data were considered as means \pm SEM. Statistical analysis (one-way ANOVA followed by Tukey's post hoc test) was performed using SPSS 16.0 (Chicago, IL, USA). For all analyses, the significance was set at $p < 0.05$.

RESULTS

In this study, the SFI showed a marked decrease for all experimental groups, 7 days after surgery. On days 30, 49, 60, and 90 after surgery, the mean SFI were -61.23 ± 3.4 , -57.14 ± 2.23 , -48.43 ± 3.72 , 42.48 ± 3.81 for the Propolis+gum Arabic group, and -73.14 ± 3.27 , -71.55 ± 4.94 , -68.21 ± 7.89 , -58.31 ± 4.9 for the autograft group, respectively ($p < 0.03$) (Figure 2).

Withdrawal reflex latency (WRL) was not significantly differences between Propolis+gum Arabic group and autograft group 30 and 90 days after surgery ($p > 0.05$) (Figure 3).

Thirty and 90 days after surgery, the mean wet weight (g) of gastrocnemius muscles was statistically significant between the Propolis+gum Arabic group (1.408 ± 0.17 , 1.623 ± 0.24) and autograft group (0.87 ± 0.19 , 1.18 ± 0.29), respectively ($p < 0.01$) (Figure 4). In this respect, the average diameter of muscle fibers in the Propolis-gum Arabic group were upper than autograft group and the differences were statistically significant at 30 and 90 days after surgery ($p < 0.01$) (Figure 5A, B).

After removing the channel, it was observed that the two nerve endings were connected by a newly formed tissue. At 30 and 90 days after surgery, the diameter of axons and myelin sheath thickness in the experimental groups were lower than the sham surgery group. Thirty days after surgery,

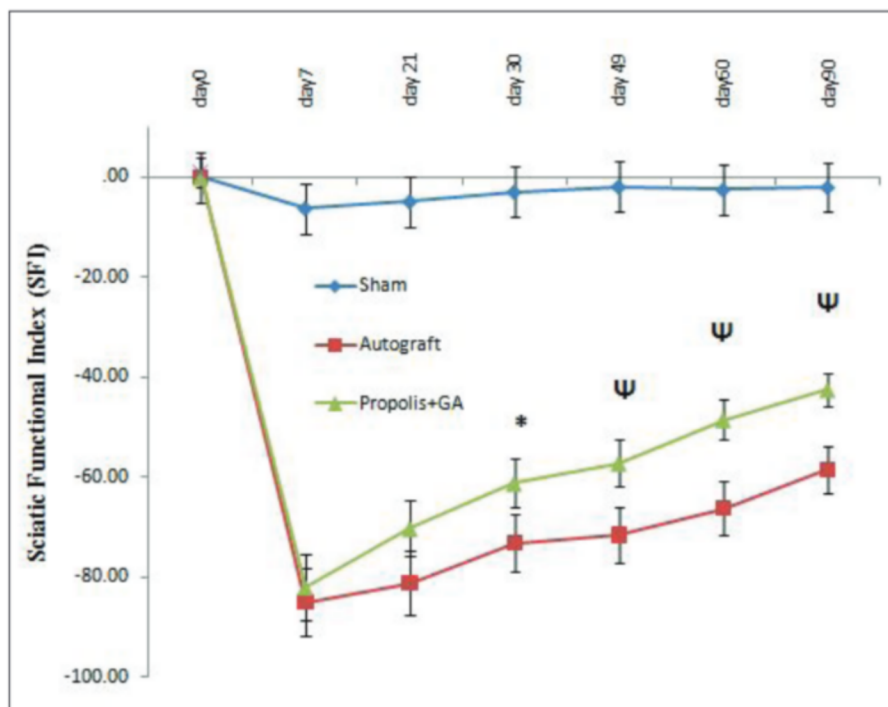


Figure 2: The sciatic nerve index (SFI) decreased after complete excision of the sciatic nerve at 7 days after surgery. *Difference among Propolis + gum Arabic with the autograft, 30 days after surgery ($p < 0.03$). Ψ Difference among Propolis + gum Arabic with the autograft, 49, 60, and 90 days after surgery ($p < 0.01$). Results are presented as mean \pm SEM.

in the Propolis+gum Arabic group, the newly regenerated axons were seen in diffuse and delicate micro-fascicles. These fascicles were surrounded by loose connective tissue containing blood vessels. Ninety days after surgery, the myelinated axons were more organized in microfascicles with a small connective tissue in the Propolis-gum Arabic group, while in the autograft group, the regenerated axons were surrounded by abundant connective tissue around them. At 90 days, the mean number of myelinated fibers in Propolis+gum Arabic group (5252 ± 643.21) was not significantly greater than autograft group (4603 ± 812.42) ($p > 0.05$) (Figure 6A, B). There was a significant difference in mean myelinated fiber diameter (μm) between Propolis+gum Arabic group and autograft 90 days after surgery ($p < 0.05$) (Table I).

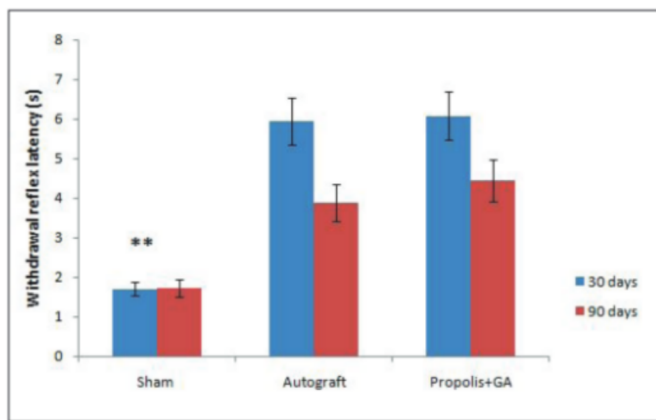


Figure 3: The mean withdrawal reflex latency (WRL) after surgery in experimental groups. ** Difference between sham surgery and other groups ($p < 0.001$). Results are presented as mean \pm SEM.

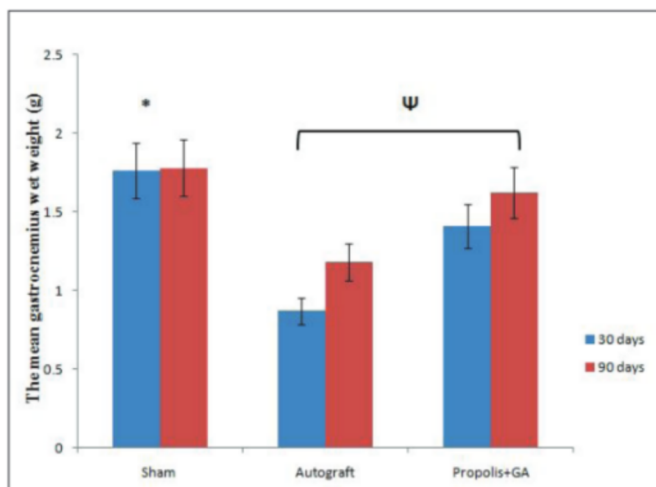


Figure 4: The mean gastrocnemius wet weight (g) after surgery in experimental groups. * Difference between sham surgery and other groups, at 30 days after surgery ($p < 0.01$). Ψ Difference between Propolis + gum Arabic and autograft groups, 30 and 90 days after surgery ($p < 0.01$). Results are presented as mean \pm SEM.

Immunohistochemical study showed that the activity of the S-100 protein was higher in the Propolis-gum Arabic group than in the autograft group, 90 days after surgery.

Positive immunohistochemical analysis indicated that Schwann cells had a higher number of myelinated axons in the Propolis+gum Arabic group than the autograft group (Figure 7A, B).

DISCUSSION

The present study reveals a completely novel effect of Propolis and gum Arabic as nerve guide channels. Previous studies showed that Propolis is effective in the regeneration of the sciatic nerve as oral treatment (7,34). However, according to recent studies, gum Arabic demonstrates a wide range of pharmacological properties, especially anti-inflammatory and antioxidant properties (13,26). For the first time, we made the NGCs from a combination of Propolis and gum Arabic. Because the melting point of Propolis is approximately 60-70 °C, its use alone in the channel structure can soften and even block the channel. Gum Arabic is a powder that is fully hydrated with water and it becomes brittle after drying.

In the present study, the Propolis-gum Arabic channel was filled with normal saline. The presence of a small hole in the

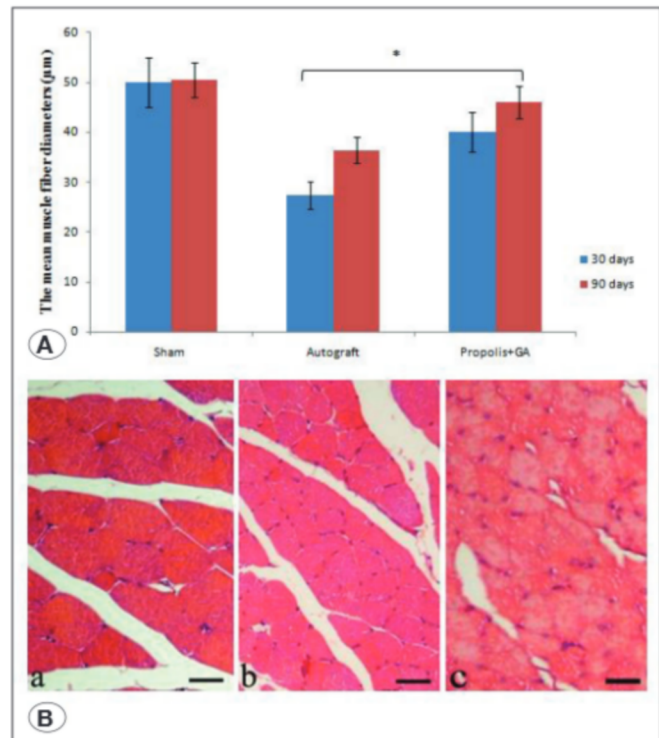


Figure 5: A) The mean muscle fiber diameters (μm) after surgery in experimental groups. * Difference between Propolis + gum Arabic and autograft groups, 30 and 90 days after surgery ($p < 0.01$). Results are presented as mean \pm SEM. **B)** Cross section of the gastrocnemius muscle (H-E), showing muscle fiber morphology after nerve regeneration. **(a)** sham surgery, **(b)** autograft, **(c)** Propolis + autograft, 90 days after surgery (Scale bar 50 μm).

Table 1: The Myelin Sheath Thickness and Myelinated Fiber Diameter in the Experimental Groups

Groups	Myelinated fiber diameter (μm)		Myelin sheath thickness (μm)	
	30 days	90 days	30 days	90 days
Sham surgery	$9.96 \pm 2.33^{**}$	$10.26 \pm 1.82^{**}$	$1.51 \pm 0.24^{**}$	$1.49 \pm 0.28^{**}$
Autograft	3.69 ± 0.19	5.92 ± 0.78	0.28 ± 0.31	0.59 ± 0.37
Propolis+GA	3.31 ± 0.25	4.76 ± 0.29	0.25 ± 0.04	$0.815 \pm 0.15^{\psi}$

** Difference between sham surgery and other groups ($p < 0.01$).

ψ Difference between Propolis + gum Arabic and autograft groups, 90 days after surgery ($p < 0.01$).

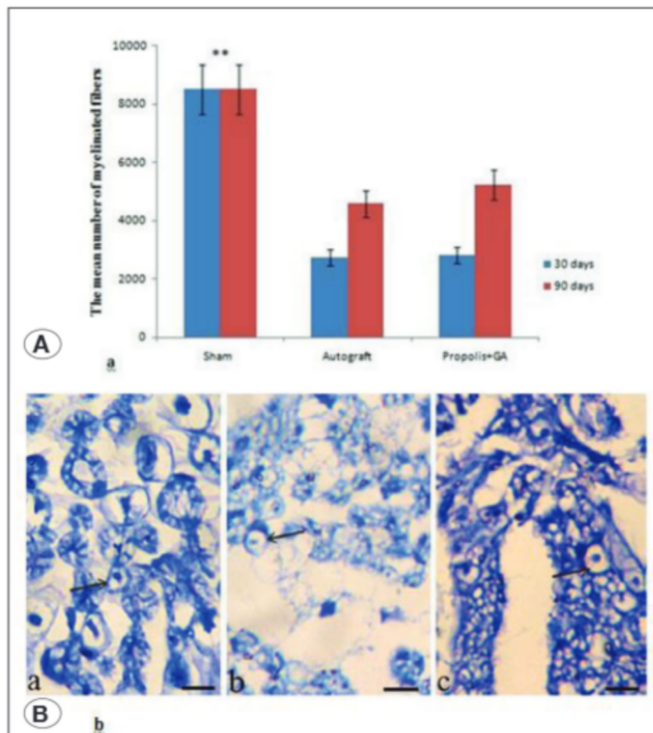


Figure 6: **A)** The mean number of myelinated fibers after surgery in experimental groups. ** Difference between sham surgery and other groups ($p < 0.001$). Results are presented as mean \pm SEM. **B)** Cross section of the main axis of the regenerated nerve (Toluidine blue stain), showing the myelinated axons after nerve regeneration. **(a)** sham surgery, **(b)** autograft, **(c)** Propolis + gum Arabic, 90 days after surgery (Scale bar 50 μm).

inner wall of the channel causes the gum Arabic to become in contact with normal saline. Due to the small size of the hole, the gum Arabic dissolves slowly in normal saline. There are many benefits of using Propolis-gum Arabic as NGCs: low cost, easy ductility, flexibility, easy sterilibility, and sufficient strength to hold sutures. Also, the degradation speed of Propolis+gum Arabic as NGCs can be easily controlled by determining the thickness of the channel layers.

In the present study, the Propolis+gum Arabic promotes sciatic functional index at 30, 49, 60, and 90 days after surgery. This study is in agreement with previous research that Propolis (oral

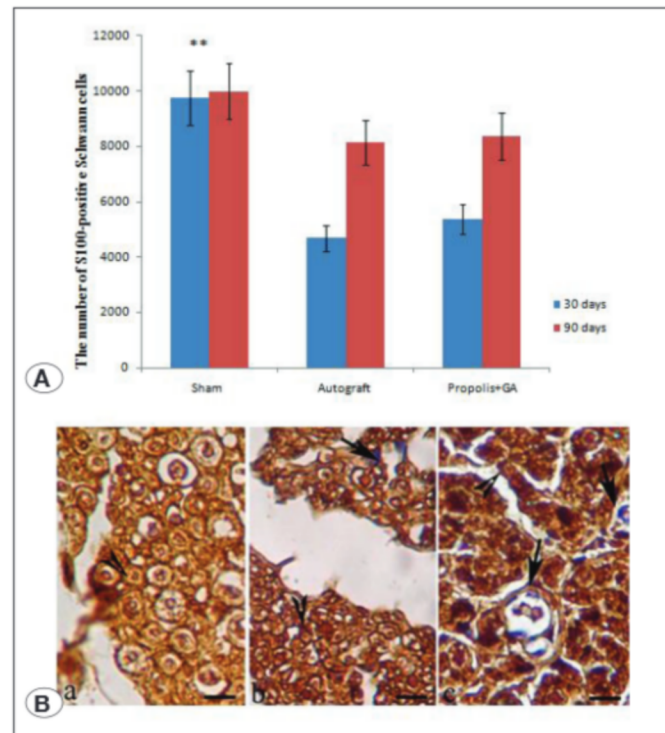


Figure 7: **A)** The mean number of S100-positive Schwann cells, 30 and 90 days after surgery in experimental groups. ** Difference between sham surgery and other groups, 30 days after surgery ($p < 0.002$). Results are presented as mean \pm SEM. **B)** Immunohistochemical analysis of cross sections of the regenerated nerve, 90 days after surgery. **(a)** Sham surgery, **(b)** Autograft, and **(c)** Propolis + gum Arabic groups. Regenerated nerve fibers including S100-positive Schwann cells, myelinated axons, and blood vessels were seen (scale bar 20 μm). **Arrow:** blood vessel, **Head Arrows:** myelinated axon.

administration) improved SFI at 14 and 21 days after sciatic nerve crush (7). The SFI score is related to the correct function of the hind limb muscles. In this study, the mean muscle wet weight, and muscle fiber diameters increased in the Propolis+gum Arabic group in comparison with the autograft group. Previous study showed that nerve damage causes skeletal muscle atrophy (19). Tanaka et al. [2019] showed that administration of Propolis prevents skeletal muscle atrophy by the suppression of anti-angiogenic and stimulation of pro-angiogenic factors (31).

The development of regeneration leads to functional recovery. In agreement with the previous study (7), the mean number of myelinated fibers increased in the Propolis+gum Arabic group in comparison with the autograft group. Oxidative stress and inflammation are well-known factors that occur in many pathophysiological processes (1). It seems that anti-inflammatory and antioxidant activity of Propolis and gum Arabic may be helpful in enhancing nerve regeneration. Ni et al. [2017] showed that Propolis has a neuroprotective effect on neurodegenerative damages in human (22). Caffeic acid phenethyl ester is a phenolic component derived from Propolis, which decrease pro-inflammatory cytokine expression and increase the antioxidant activity (21). In addition, Propolis may reduce inflammation by inhibiting the expression of nitric oxide synthase (20). The gum Arabic administration can be effective in modulating immunity and decrease of inflammation by a decrease in the level of TNF- α (16). On the other hand, GA stimulates the production of IL-6 (such as inflammatory cytokines) (33). Since the administration of Propolis reduces the levels of IL-6 (28), it seems that the combination of Propolis+gum Arabic may be effective in controlling and reducing inflammation.

In the present study, a layer of macrophages could be seen on the surface of the Propolis+gum Arabic NGCs. The macrophages are involved in the production and regulation of the nerve growth factor (30). A previous study showed that administration of Propolis may be useful in accelerating nerve regeneration by macrophages (7).

In the present study, the mean number of Schwann cells was increased in the Propolis+gum Arabic group in comparison with the autograft group. An increase in the number of Schwann cells can accelerate the process of the nerve regeneration. The anti-apoptotic effect of Propolis may be effective in increasing the number of Schwann cells (32).

We also found that the mean Withdrawal reflex latency (WRL) was not statistically significant differences between Propolis+gum Arabic group and autograft group 30 and 90 days after surgery. Although Propolis+gum Arabic may be useful in accelerating axon sprouting, painful neuroma formation is possible in the process of nerve regeneration. The Propolis may be considered as a pain reliever against inflammatory pain (7).

When the sciatic nerve is cut, the nerve distal segment is affected by ischemia and reperfusion, and the nerve damage happens during the formation of free radicals. Propolis+gum Arabic seems to be able to prevent ischemia-reperfusion injury. Previous studies showed that oral GA significantly increased the level of total antioxidant (TAC) and reduced the level of Malodialdehyde (MDA) (14). In addition, Propolis is a strong antioxidant, decreases MDA and increases the activities of glutathione and superoxide dismutase enzymes (27).

CONCLUSION

The Propolis+gum Arabic may be beneficial as an NGCs in repairing peripheral peripheral nerve gaps. It seems that nerve regeneration in the Propolis+gum Arabic may be due

to synergistic effects of Propolis and gum Arabic. There are many reasons for the effects of Propolis and gum Arabic in nerve regeneration, but it seems that the synergistic effects of these two may be effective. However, further studies are needed to reveal the mechanisms of the effects of Propolis and gum Arabic as NGCs in peripheral nerve regeneration.

ACKNOWLEDGMENT

This paper has been derived from the MSc thesis and supported by Urmia University of Medical Sciences in Urmia, Iran.

REFERENCES

- Ahmed A, Ahsan H: Biomarkers of inflammation and oxidative stress in ophthalmic disorders. *J Immunoassay Immunochem* 41(3):257-271, 2020
- Al Zábabi M, Al Saslam S, Al Suleimani Y, Manoj P, Nemmar A, Ali BH: Gum Acacia improves renal function and ameliorates systemic inflammation, oxidative and nitrosative stress in streptozotocin-induced diabetes in rats with adenine-induced chronic kidney disease. *Cell Physiol Biochem* 45:2293-2304, 2018
- Atgié M, Chennevière A, Masbernat O, Roger K: Emulsions stabilized by Gum Arabic: How diversity and interfacial networking lead to metastability. *Langmuir* 35:14553-14565, 2019
- Babiker R, Elmusharaf K, Keogh MB, Saeed AM: Effect of Gum Arabic (Acacia Senegal) supplementation on visceral adiposity index (VAI) and blood pressure in patients with type 2 diabetes mellitus as indicators of cardiovascular disease (CVD): A randomized and placebo-controlled clinical trial. *Lipids Health Dis* 17:56, 2018
- Bain JR, Mackinnon SE, Hunter DA: Functional evaluation of complete sciatic, peroneal, and posterior tibial nerve lesions in the rat. *Plast Reconstr Surg* 83:129-138, 1989
- Barak S, Mudgil D, Taneja S: Exudate gums: Chemistry, properties and food applications-a review. *J Sci Food Agric* 100(7):2828-2835, 2020
- Barbosa RA, Nunes TL, Nunes TL, da Paixão AO, Belo Neto R, Moura S, Albuquerque Junior RL, Cândido EA, Padilha FF, Quintans-Júnior LJ, Gomes MZ, Cardoso JC: Hydroalcoholic extract of red Propolis promotes functional recovery and axon repair after sciatic nerve injury in rats. *Pharm Biol* 54:993-1004, 2016
- Fadia NB, Bliley JM, DiBernardo GA, Crammond DJ, Schiling BK, Sivak WN, Spiess AM, Washington KM, Waldner M, Liao HT: Long-gap peripheral nerve repair through sustained release of a neurotrophic factor in nonhuman primates. *Sci Transl Med* 12(527):eaav7753, 2020
- Farjah GH, Dolatkah MA, Pourheidar B, Heshmatian B: The effect of cerebro-spinal fluid in collagen guide channel on sciatic nerve regeneration in rat. *Turk Neurosurg* 27:453-459, 2017
- Farjah GH, Fazli F: The effect of chick embryo amniotic fluid on sciatic nerve regeneration of rats. *Iran J Vet Res* 16:167-171, 2015

11. Farjah GH, Fazli F, Karimipour M, Pourheidar B, Heshmatiyan B, Pourheidar M: The effect of bone marrow mesenchymal stem cells on recovery of skeletal muscle after neurotization surgery in rat. *Iran J Basic Med Sci* 21:236-243, 2018
12. Farjah GHH, Mohammadzadeh S, Zirak Javanmard M: The effect of lycopene in eggshell membrane guidance channel on sciatic nerve regeneration in rats. *Iran J Basic Med Sci* 23:527-533, 2020
13. Garcínez E, Andújar I, Yuste Del Carmen A, Prohens J, Martínez-Navarrete N: Antioxidant and anti-inflammatory activity of freeze-dried grapefruit phenolics as affected by gum Arabic and bamboo fiber addition and microwave pretreatment. *J Sci Food Agric* 98:3076-3083, 2018
14. Kaddam L, Fadl-Elmula I, Eisawi OA, Abdelrazig HA, Salih MA, Lang F, Saeed AM: Gum Arabic as novel anti-oxidant agent in sickle cell anemia, phase II trial. *BMC Hematol* 17:4, 2017
15. Kaddam LA, Fdl-Elmula I, Eisawi OA, Abdelrazig HA, Elnimeiri MK, Saeed AM: Biochemical effects and safety of gum Arabic (*Acacia Senegal*) supplementation in patients with sickle cell anemia. *Blood Res* 54:31-37, 2019
16. Kamal E, Kaddam LA, Dahawi M, Osman M, Salih MA, Alagib A, Saeed A: Gum Arabic fibers decreased inflammatory markers and disease severity score among rheumatoid arthritis patients, phase II trial. *Int J Rheumatol* 2018:4197537, 2018
17. Konya D, Liao WL, Choi H, Yu D, Woodard MC, Newton KM, King AM, Pamir NM, Black PM, Frontera WR, Sabharwal S, Teng YD: Functional recovery in T13-L1 hemisectioned rats resulting from peripheral nerve rerouting: Role of neuroplasticity. *Regen Med* 3:309-327, 2008
18. Kurek-Górecka A, Górecki M, Rzepecka-Stojko A, Balwierz R, Stojko J: Bee products in dermatology and skin care. *Molecules* 25(3):556, 2020
19. Langer HT, Afzal S, Kempa S, Spuler S: Nerve damage induced skeletal muscle atrophy is associated with increased accumulation of intramuscular glucose and polyol pathway intermediates. *Sci Rep* 10:1908, 2020
20. Medjeber O, Touri K, Raza H, Djeraba Z, Belkhef M, Boutaleb AF, Arroul-Lammali A, Belguendouz H, Touil-Boukoffa C: Ex vivo immunomodulatory effect of ethanolic extract of Propolis during celiac disease: Involvement of nitric oxide pathway. *Inflammopharmacology* 26:1469-1481, 2018
21. Mei Y, Wang Z, Zhang Y, Wan T, Xue J, He W, Luo Y, Bai X, Wang Q, Huang Y: FA-97, a new synthetic caffeic acid phenethyl ester derivative, ameliorates DSS-induced colitis against oxidative stress by activating Nrf2/H₂O₂-1 pathway. *Front Immunol* 10:2969, 2020
22. Ni J, Wu Z, Meng J, Zhu A, Zhong X, Wu S, Nakanishi H: The neuroprotective effects of Brazilian green Propolis on Neurodegenerative damage in human neuronal SH-SY5Y cells. *Oxid Med Cell Longev* 2017:7984327, 2017
23. Osés SM, Marcos P, Azofra P, de Pablo A, Fernández-Muñoz MÁ, Sancho MT: Phenolic profile, antioxidant capacities and enzymatic inhibitory activities of Propolis from different geographical areas: Needs for analytical harmonization. *Antioxidants (Basel)* 9(1):75, 2020
24. Park JW, Sung MS, Ha JY, Guo Y, Piao H, Heo H, Park SW: Neuroprotective effect of Brazilian green Propolis on retinal ganglion cells in ischemic mouse retina. *Curr Eye Res* 45(8):955-964, 2020
25. Roca FG, Picazo PL, Pérez-Rigueiro J, Tortuero GVG, Pradas MM, Martínez-Ramos C: Conduits based on the combination of hyaluronic acid and silk fibroin: Characterization, in vitro studies and in vivo biocompatibility. *Int J Bio Macromol* 148:378-390, 2020
26. Sarabani K, Jafari SM, Mahoonak AS, Mohammadi A: Application of gum Arabic and maltodextrin for encapsulation of eggplant peel extract as a natural antioxidant and color source. *Int J Bio Macromol* 140:59-68, 2019
27. Seven I, Tatil Seven P, Gul Baykalir B, Ozer Kaya S, Yaman M: Bee glue (Propolis) improves reproductive organs, sperm quality and histological changes and antioxidant parameters of testis tissues in rats exposed to excess copper. *Andrologia* 52(4):e13540, 2020
28. Shi B, Zhao Y, Yuan X: Effects of MTA and Brazilian Propolis on the biological properties of dental pulp cells. *Braz Oral Res* 33:e117, 2020
29. Singh A, Shiekh PA, Das M, Seppälä J, Kumar A: Aligned chitosan-gelatin cryogel-filled polyurethane nerve guidance channel for neural tissue engineering: Fabrication, characterization, and in vitro evaluation. *Biomacromolecules* 20:662-637, 2019
30. Takano S, Uchida K, Inoue G, Miyagi M, Aikawa J, Iwase D, Iwabuchi K, Matsumoto T, Satoh M, Mukai M, Minatani A, Takaso M: Nerve growth factor regulation and production by macrophages in osteoarthritic synovium. *Clin Exp Immunol* 190:235-243, 2017
31. Tanaka M, Kanazashi M, Maeshige N, Kondo H, Ishihara A, Fujino H: Protective effects of Brazilian Propolis supplementation on capillary regression in the soleus muscle of hindlimb-unloaded rats. *J Physiol Sci* 69:223-233, 2019
32. Tandean S, Japardi I, Loe ML, Riawan W, July J: Protective effects of Propolis extract in a rat model of traumatic brain injury via Hsp70 induction. *Open Access Maced J Med Sci* 7:2763-2766, 2019
33. Xuan NT, Shumilina E, Nasir O, Bobbala D, Götz F, Lang F: Stimulation of mouse dendritic cells by gum Arabic. *Cell Physiol Biochem* 25:641-648, 2010
34. Yuce S, Cemal Gokce E, Iskdemir A, Koc ER, Cemil DB, Gokce A, Sargon MF: An experimental comparison of the effects of Propolis, curcumin, and methylprednisolone on crush injuries of sciatic nerve. *Ann Plast Surg* 74:648-692, 2015