

Heterotopic Mesenteric Ossification, Co-incidentally found with a Ruptured Tubo-ovarian Abscess: A Case Report

Farzaneh Javanmard^{*1}, Sonia Sadeghpour², Seyede Zohre Banihashemi³

Received 20 October 2020, Accepted for publication 16 March 2021

Abstract

Heterotopic mesenteric ossification is a rare bone-like lesion located inside the abdominal cavity. Its etiology is unclear but most of the patients had a history of abdominal trauma or surgical operation.

In this study, we present the case of a 29-year old woman admitted with acute abdominal pain and fever that underwent emergency laparotomy. She had a history of recurrent pelvic inflammatory disease and surgical appendectomy. During a laparotomy, a massive left tubo-ovarian abscess was seen and drained out. There was also a hard mass-like lesion measuring 2×1cm attached to the mesentery that was excised and sent for pathologic evaluation. The patient was discharged in good general condition.

Microscopic evaluation of the mass in hematoxylin and eosin stained section revealed a structure consisting of bony trabeculae and fibroblastic proliferation.

This case represents a rare simultaneous occurrence of mesenteric ossification with a ruptured tubo-ovarian abscess that due to a history of recurrent inflammatory disease introduce inflammatory process as a possible cause of heterotopic mesenteric ossification.

Keywords: Mesenteric, Ossification, Tubo-ovarian, abscess

Address: pathology department of shahid Mottahari hospital, Urmia University of medical science, Urmia, Iran

Tel: +984432237080

Email: javanmard.a@umsu.ac.ir

Introduction

Heterotopic mesenteric ossification (HMO), also referred to as mesenteritis ossificans or intra-abdominal myositis ossificans, is a rare benign intra-abdominal tumor-like lesion that is characterized by a bony formation in stromal myofibroblastic proliferation. Microscopically this entity may be confused with malignancy, particularly extraskelatal osteosarcoma(1). Heterotopic bone-like formation is generally found not only in the mesentery but also in the mesoappendix,

omentum, and peritoneal surfaces or laparotomy scars.

In clinical settings, patients with mesenteric or omental ossification can be asymptomatic or may present chronic abdominal pain, discomfort or intestinal obstruction.

Due to its rarity, the data are limited to case studies(2).

On our review of the literature, most of the cases involved were adult's men. In this study we present a case of mesenteric heterotopic ossification in a woman who underwent urgent laparotomy for tubo-ovarian

¹ Assistant professor Pathology, Urmia University of medical science, Urmia, Iran (Corresponding Author)

² Assistant professor Gynecology, Urmia University of medical science, Urmia, Iran

³ Resident of pathology Pathology, Urmia University of medical science, Urmia, Iran

abscess rupture. This report is the first co-occurrence of tubo-ovarian abscess rupture presentation incidentally found with the mesenteric heterotopic ossification.

Case report

A 29-year-old nulliparous woman was admitted to the emergency department of Urmia Shahid Motahari hospital with sudden onset of severe left lower quadrant abdominal pain. She had a gradual onset of high-grade fever (41°C) six days before abdominal pain and underwent fluid therapy at home.

She was under medication for recurrent pelvic inflammatory disease and left ovarian cyst. She had also a history of appendectomy five years ago.

Physical examination demonstrated generalized abdominal tenderness. She had a stable hemodynamic state.

In laboratory test, there was leukocytosis of $18.33 \times 10^3/\mu\text{l}$ (reference value: 4-11000/ μl), erythrocyte sedimentation

Rate (ESR) of 108 mm/h (reference value: 2-20mm/h), and positive C-reactive protein (CRP 3+).

An urgent ultrasound scan (US) of the abdomen showed a heterogeneous area measuring 55×42 mm at

the left adnexum compatible with tubo-ovarian abscess. (Fig. 1)

The patient underwent surgery. During a laparotomy, there were significant adhesions between the bowels and abdominal wall, as well as on the omentum. After the analysis of adhesions, a massive left tubo-ovarian abscess and a hard mass-like lesion measuring 2×1cm attached to the mesentery were seen. The abscess was drained out and the lesion was excised and sent for further pathologic investigation. The left ovary was preserved due to patient's nulliparity. Subsequently, the patient was treated with ampicillin, metronidazole, and gentamicin, intravenously for one week. She recovered well postoperatively and was discharged within 10 days.

On gross inspection a round gray-colored lesion, hard in consistency, measuring 2 cm in greatest dimension is seen (Fig. 2). On microscopic examination there was a well-developed bony trabecula in a background of fibroblastic proliferation (Fig. 3).

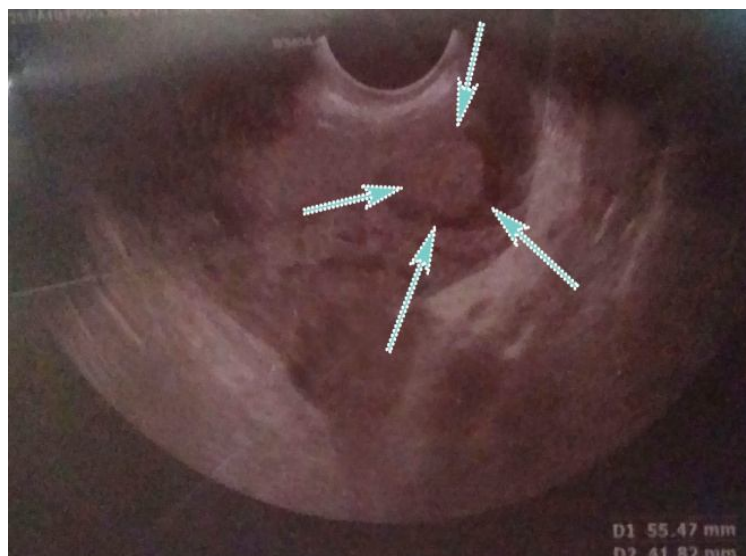


Fig 1. Ultrasound image of the abdomen shows heterogeneous area compatible with tubo-ovarian abscess (arrows)

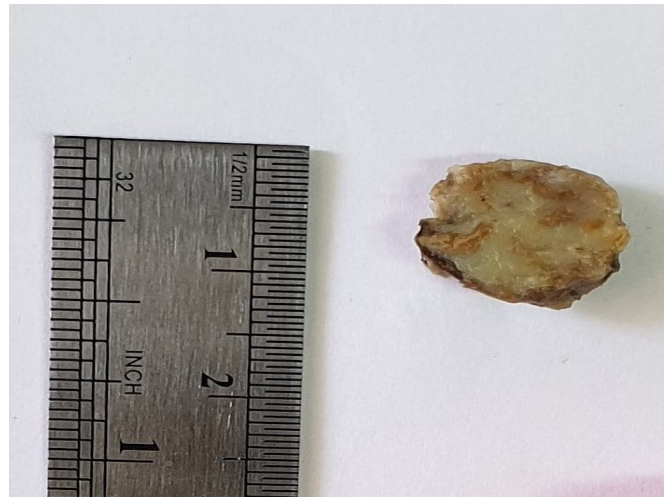


Fig 2. Gross photograph of the resection specimen shows a round well-defined gray-colored bony lesion

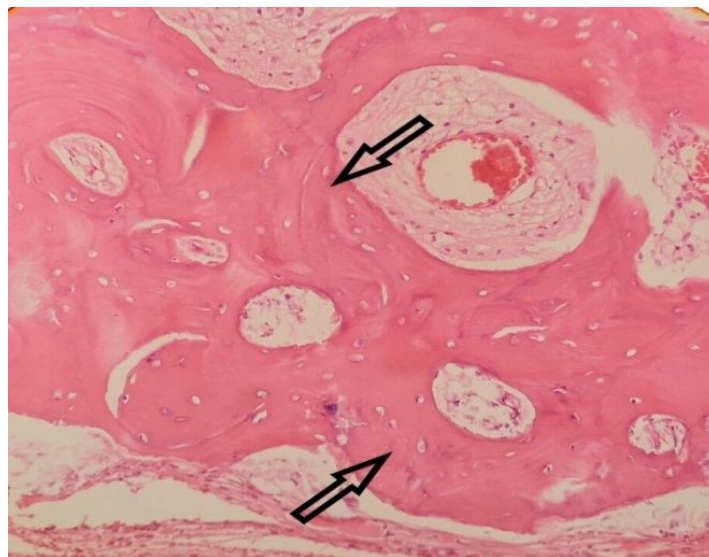


Fig 3. Histological section shows lamellar trabecular bone (arrows) in a background of fibroblastic proliferation (hematoxylin&eosin,×40)

Discussion

Heterotopic ossification is defined as the development of lamellar bone outside the skeletal system and it is a rare condition. The term heterotopic mesenteric ossification was coined by Wilson et al. in 1999 in their description of a fine intra-abdominal osseous pseudotumor histologically identical to myositis ossificans(3). It is also known by other names including pseudomalignant osseous tumor of soft tissue, neurogenic osteoma, fibrosing ossificans, and fibrodysplasia ossificans.

The process of heterotopic bone formation was first described in the extremities and was originally named myositis ossificans. This term is a misnomer as muscle is not always involved(4).

The most important diagnostic criterion is the zone phenomena, a term referring to the progressive maturation of the immature central portion towards the periphery from atypia, mitosis and hypercellularity, to first primitive osteoid, then well-organized osteoid with prominent osteoblastic rimming and finally mature lamellar bone(5).

The pathogenesis of HMO remains unclear, even if abdominal trauma and/or repetitive surgical procedures are always present(6). This event must cause a release of signals from the site of injury. These signals are sent either by the initially injured cells or by inflammatory cells. Third, mesenchymal cells “whose genetic machinery is not fully committed” must be present. lastly, the genes that are responsible for forming osteoid and chondroid in those mesenchymal cells must be activated by the inflammatory signals, causing the mesenchymal cells into osteoblasts or chondroblasts (7).

Heterotopic ossification in abdominal scars has been attributed to intraoperative seeding of osteogenic cells from the periosteum or perichondrium of normal, adjacent bone. It fails to explain the infrequent occurrence of heterotopic bone formation in sites involved in orthopedic surgeries, or procedures in which large numbers of osseous tissue cells are liberated (8).

Our patient had a surgical appendectomy 5 years ago but it is difficult to blame this factor as the only cause of mesenteric ossification, because the abdominal incision did not contact with any osseous tissue; thus, this hypothesis does not explain the heterotopic ossification in this patient.

Another hypothesis is that pathogenesis of heterotopic ossification is a result of immature multipotent mesenchymal cells differentiating into osteoblasts or chondroblasts as a reaction to local injury, and ultimately resulting in bone formation.

This process might require additional contributing factors including venous stasis, edema, local trauma, inflammation, and secretion of local osteoinductive factors (7). This hypothesis provides a better explanation for the pathogenesis of ossification in our patient due to recurrent pelvic inflammatory disease and signals from inflammatory cells into multipotential mesenchymal cell.

Regardless of the underlying etiology, management of a mass believed to be heterotopic ossification must

take several factors into account. First, one must differentiate between benign heterotopic ossification and the possibility of malignancy (8).

Heterotopic ossification must be differentiated from other phenomena such as dystrophic calcification and malignant bone tumors(10).

Dystrophic calcification is the calcification that occurs in soft tissue post inflammation and appears as amorphous calcification with an ill-defined appearance that can increase in density over time (11).

Histologically, HMO is comprised of organized lamellar bone. This contrasts with osseous malignancy that appears haphazard and disorganized(12).

According to the best of our knowledge, only a couple of dozen cases are reported in the literature. In review of literature, the vast majority of patients were men (>90%). Presentations included obstructive, abdominal trauma, fistula formation, incidental findings, intestinal perforation and anastomotic leak, in order of frequency. The majority of patients had abdominal surgeries, but few patients had no history of prior surgery or trauma (1-14).

In the present case, intra-abdominal heterotopic ossification was found co-incidentally with tubo-ovarian abscess rupture in a woman. The patient had history of recurrent PID that may accelerate bone tissue formation but there is not enough study about the relevance of bone formation to inflammatory disease.

However the surgeon should be aware of this unusual condition, particularly in patients with a previous surgical history. In clinical settings, it should not be forgotten that these bony lesions are benign with no malignant potential (2).

Conclusion: We report a rare case of HMO that was identified at laparotomy for tubo-ovarian abscess drain-out. A thorough literature review revealed no previous case with this rare co-occurrence. Heterotopic mesenteric ossification can result in serious complications, however surgical excision appears to be

an acceptable and suitable treatment. As such further investigation of the etiology, diagnosis, prevention, and treatment of HMO is essential to delineate appropriate prophylactic and therapeutic options for these patients.

Conflicts Of Interest

None of the authors identify any conflict of interest.

References

1. Vytlačil C, Sherwood N, Silverman J. Heterotopic Mesenteric Ossification: A Rare Benign Pseudotumor. *Am J Clin Pathol* 2015;144(suppl-2):A364.
2. Celik SU, Senocak R, Hancerliogullari O. Heterotopic mesenteric and omental ossification incidentally found in a patient with multiple abdominal surgical operations because of gunshot injury. *Ulus Travma Derg* 2019;25(5):531-4.
3. Patel RM, Weiss SW, Folpe AL. Heterotopic mesenteric ossification: a distinctive pseudosarcoma commonly associated with intestinal obstruction. *Am J Surg Pathol* 2006;30(1):119-22.
4. Binesh F, Akhavan A, Navabii H, Ostadi M. Heterotopic mesenteric ossification: report of a case and review of the literature. *BMJ Case Rep* 2012; 2012:bcr0220125793.
5. Ioannidis O, Sekouli A, Paraskevas G, Kotronis A, Chatzopoulos S, Papadimitriou N et al. Intra-abdominal heterotopic ossification of the peritoneum following traumatic splenic rupture. *J Res Med Sci* 2012; 17(1): 92-5.
6. Shi X, Zhang W, Nabieu PF, Zhao W, Fu C. Early postoperative heterotopic omental ossification: report of a case. *Surg Today* 2011;41(1):137-40.
7. Reynoso JF, Christense D, Latifi R. Heterotopic mesenteric ossification as a cause of persistent enterocutaneous fistula. *Eur J Surg* 2012;44:285-90.
8. Lai HJ, Jao SW, TY Lee, Ou JJ, Kang JC. Heterotopic mesenteric ossification after total colectomy for bleeding diverticulosis of colon: A rare case report. *J Formos Med Assoc* 2007; 106 (2):532-6.
9. Lao VV, Lao OB, Figueredo E. Postoperative Bowel Perforation due to Heterotopic Ossification (Myositis Ossificans Traumatica): A Case Report and Review of the Literature. *Case Rep Gastrointest Med* 2011:908514.
10. Bosaily A, Edminister J, Magal S, Jamil M, Lynn A, Hall G. Extensive Circumferential Heterotopic Ossification Discovered at the Base of a Loop Ileostomy. *Case Rep Surg* 2019; 2019: 4036716.
11. Mujtaba B, Taher A, Fiala MJ, Nassar S, Madewell JE, Hanafy AK et al. Heterotopic ossification: radiological and pathological review. *Radiol Oncol* 2019;53(3):275-84.
12. Torgersen Z, Osmolak A, Bikhchandani J, Forse R. Ectopic Bone in the Abdominal Cavity: A Surgical Nightmare. *J Gastrointest Surg* 2013; 17(9):1708-11.
13. Merrell J, Sadro C, Chew F. Heterotopic Mesenteric Ossification after Blunt Abdominal Trauma and Multiple Surgical Operations. *Radiol Case Rep* 2008;3(4):243.
14. Michael A, Narasimman S, Jasjit Singh N. Mesenteric bones: Intra-abdominal heterotopic ossification. *Med J Malaysia* 2018;73(2):110-1.