



Effect of Antihypertensive Drugs on Placental Villi of Preeclamptic Patients: A Histopathological Study

Hamid Ansari^{*1}, Mohammad Faizan Ansari², Smrity Gupta³, Medha Das⁴

¹ Associate Professor, Department of Anatomy, Rama Medical College & Research Centre, Kanpur, UP, India

² Assistant Professor, Department of Anatomy, Rama Medical College & Research Centre, Kanpur, UP, India

³ Assistant Professor, Department of Anatomy, Rama Medical College & Research Centre, Kanpur, UP, India

⁴ Professor & Head, Department of Anatomy, Rama Medical College & Research Centre, Kanpur, UP, India

***Corresponding authors:** Dr. Hamid Ansari, **Address:** Rama Medical College & Research Centre, Rama University, Kanpur, UP, India, **Email:** Hamidansari78@gmail.com, **Tel:** +918918748710

Abstract

Background & Aims: The placenta has been described as the most accurate record of the infant's prenatal experience. The present study was a quantitative study and it was carried out to see the effect of pre-eclampsia on histopathology of placenta and the comparative changes in placenta of preeclamptic patients taking antihypertensives.

Materials & Methods: A total of 60 patients were selected from the Obstetrics and Gynecology Department of Jawahar Lal Nehru Medical College & Hospital, AMU, Aligarh, UP, India and were grouped into control, untreated, and treated groups. Placenta of each group was fixed in 10% formalin solution and processed for section cutting. 5-micron thick sections were prepared and stained with Hematoxylin-eosin and Wiegerts & Van gieson stain and observed under the light of the microscope. A total of 200villi/hpf was counted and percentages for each parameter were expressed.

Result: It has been shown that there was a significant reduction (<0.05) in the percentage of placental villi showing syncytial knot, cytotrophoblast proliferation, Basement membrane thickening, fibrinoid necrosis, and stromal fibrosis.

Conclusion: It has been concluded that antihypertensive drugs were not only effective in controlling the symptoms of pre-eclampsia but also effective in minimizing the placental histopathology and helpful in continuation of pregnancy under low utero-placental flow without completely normalizing the placental changes.

Keywords: Pre-eclampsia, Methyldopa, Chorionic villi, Basement membrane

Received 10 May 2022; accepted for publication 19 June 2022

Introduction

The presence of the fetus in the womb depends on a vital organ called the placenta. It is the most accurate data on the prenatal experience of an infant (1).

Hypertensive diseases that complicate pregnancy are common and, along with hemorrhage and infection, form a deadly triad, leading to numerous maternal mortalities and thus fetal death. Although the cause

remains unknown, preeclampsia can only occur if there is a placenta. In preeclampsia, maternal blood flow to the fetal placental unit is significantly reduced compared to normal pregnancy (2).

The placenta fails to develop appropriately in preeclampsia. There is a resultant placental endothelial dysfunction and reduced maternal uteroplacental blood flow, which can indirectly constrict fetal stem arteries, resulting in changes found in placenta (3). Majumdar et al. (4) have noted significant morphological changes in placenta of preeclamptic patients.

The α -methyl dopa (α MD) is most commonly used to treat preeclampsia. Trophoblast cells carry the α 2-adrenergic receptor, which is the primary target of α -methyl dopa (5).

Materials & Methods

This study is a quantitative study to confirm the effect of preeclampsia on the histopathology of placental villi and to see how effective antihypertensive drugs are in restoring normal histopathological changes in the hypertensive placenta.

Ethical clearance was taken from Institutional Ethics Committee (IEC).

A total of 60 cases were taken and categorized into three categories: control, untreated, and treated.

Inclusion Criteria:

- Only cases with blood pressure less than 140/90mm Hg without proteinuria or edema were included in the control group.
- Only cases with or without edema and / or proteinuria, with blood pressure in the range of 140/90 mm Hg or higher were included in the untreated group.
- Only cases with preeclampsia who took α -methyl dopa 250 mg TDS or QID for approximately

an equal duration were included in the treated group.

Exclusion Criteria:

- Patients with other comorbidities such as diabetes, etc.
- Those who did not take methyl dopa on a regular basis, and
- Those who did not regularly attend prenatal clinics.

After birth, the placenta was collected and fixed with 10% formalin. Processing was done. Sections (5 μ thick) were prepared and then stained with hematoxylin eosin and Wiegert and Van gieson stain, and viewed under a light microscope. 200 villi / hpf was counted and percentages of each parameter were expressed.

Statistical analysis:

All statistical data were analyzed using the SPSS software version 16 statistics package for Windows. Continuous variables are expressed as mean \pm standard deviation. Depending on the normal distribution, we used the independent samples' unpaired "t" test to compare the continuous variables between the two groups. The p-value less than 0.05 was considered significant.

Results

The obtained data were compared as follows.

After statistical analysis, a significant increase ($p < 0.05$) of histopathological findings in the placental villi was observed in the untreated group compared to the control group (Table 1). When the data between untreated and treated groups were analyzed, there was also a significant reduction ($p < 0.05$) of histopathological changes in the placental villi of the treated group (Table 2). But the reductions in histopathological changes in patients receiving antihypertensives were not significantly close to those in controls (Table 3).

Table 1: Comparison of control group and untreated group

Histological findings features (PER HPF)	Hypertensive untreated group (mean \pm sd)	Hypertensive treated group (mean \pm sd)	Statistical significance ($p < 0.05$)
Syncytial knots	56.21 \pm 3.01	49.42 \pm 6.06	Significant

Cytotrophoblastic cells proliferation	56.74 ± 3.04	46.36 ± 8.53	Significant
Thickening of Basement membrane	41.20 ± 2.42	18.95 ± 3.71	Significant
Fibrinoid necrosis	33.25 ± 3.01	8.40 ± 2.09	Significant
Stromal fibrosis	58.95 ± 2.32	22.35 ± 5.95	Significant

Table 2. Comparison of untreated group and treated group

Histological feature (PER HPF)	Control group (mean ± sd)	Hypertensive untreated group (mean ± sd)	Statistical significance (p<0.05)
Syncytial knots	17 ± 2.32	56.21 ± 3.09	Significant
Cytotrophoblastic cells proliferation	12.55 ± 2.06	56.74 ± 3.04	Significant
Thickening of Basement Membrane	0.00	41.20 ± 2.42	Significant
Fibrinoid necrosis	2.50 ± 1.23	33.25 ± 3.01	Significant
Stromal fibrosis	1.95 ± 0.76	58.85 ± 2.32	Significant

Table 3. Comparison of treatment group and control group

Histological findings features (PER HPF)	Control group (mean ±sd)	Hypertensive treated group (mean ±sd)	Statistical significance (p<0.05)
Syncytial knots	17 ± 2.32	49.42 ± 6.05	Significant
Cytotrophoblastic cells proliferation	12.55 ± 2.06	46.36 ± 88.53	Significant
Thickening of Basement membrane	0.00	18.95 ± 3.71	Significant
Fibrinoid necrosis	2.50±1.23	8.40 ± 2.09	Significant
Stromal fibrosis	1.95 ± 0.76	22.35 ± 5.95	Significant

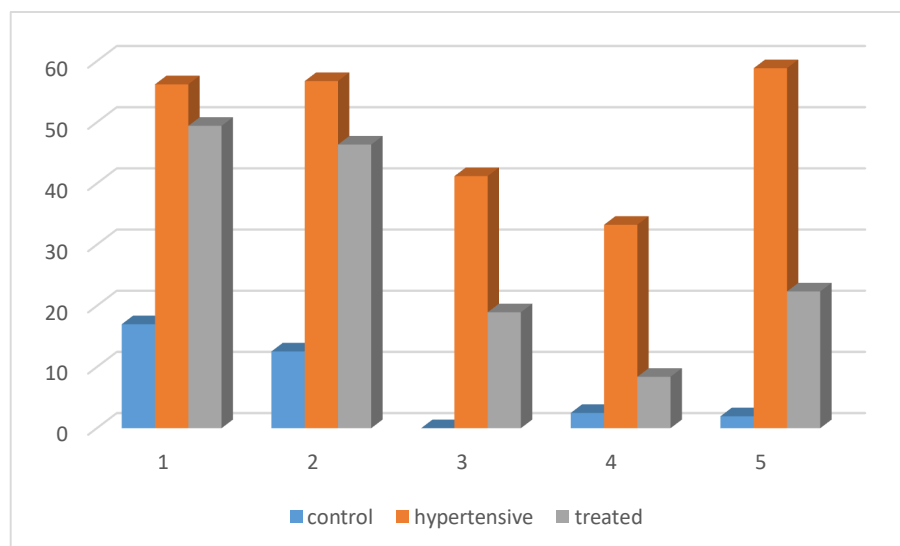


Fig 1. comparison among 3 groups

1. Syncytial knot formation
2. Cytotrophoblast proliferation
3. Basement membrane thickening
4. Fibrinoid necrosis
5. Stromal fibrosis

Discussion

This study was a quantitative study of histopathology of placentas of three groups, i.e. controlled hypertension, untreated hypertension, and treated hypertension.

The histopathology of placenta of hypertensive mothers showed a significant increase in the percentage of syncytial knot formation, cytotrophoblast proliferation, basement membrane thickening, fibrinoid necrosis, stromal fibrosis, and villous edema in comparison to control group. These results are completely consistent with previous studies by Anderson and Mackey (6) and Jones and Fox (7).

Mallik et al. (8), Masodkar et al. (9), Sodhi et al. (10), and Majumdar et al (11) also observed increased syncytial knot formation, cytotrophoblast formation, fibrinoid necrosis, and stromal fibrosis in the placentas of preeclamptic patients.

According to Fox (12), excessive syncytial knot formation is a good indicator of the degree of hypoperfusion of the villi.

The degree of cytotrophoblast hyperplasia is associated with the degree of syncytial damage. Therefore, it serves as a rough quantitative indicator of the ischemic severity to which the villi have been exposed (13).

Genset(14) also reported that an overall reduction of fetal perfusion of the placenta results in stromal fibrosis and extensive syncytial formation in generalized form.

Hypertensive pregnancies have placental lesions such as infarctions, villous fibrinoid necrosis, and villous hypermaturity that are significantly related to the severity of the hypertension. In addition, when hypertension is high, angiogenesis and vascularization of placenta are significantly impaired (15).

In mild or severe preeclampsia/eclampsia, the placenta shows significant histological evidence of ischemia, and the degree of placental involvement due to infarction is inversely proportional to the birth weight of the fetus. The fetal placental ratio increased as the severity of the disease increased, but the average body weight decreased (16).

Placental villi of hypertensive mothers taking α Methyldopa showed a significant reduction in the percentages of all the histopathological findings. No parallel data supported our study on the histopathology of placental villi of treated patients. α -Methyldopa may have specific effects on placental and/or endothelial cell function in patients with pre-eclampsia by altering angiogenic proteins. In preeclampsia, α -methyldopa can directly affect placental synthesis and/or secretory function (17).

Conclusion

Hence, it has been concluded that antihypertensive drugs were effective in controlling the symptoms of preeclampsia and minimizing the placental histopathology and also helpful in continuation of pregnancy under low uteroplacental flow without completely normalizing the placental changes.

Financial support and sponsorship

Nil

Conflicts of interest

There are no conflicts of interest

References

1. Benirshke K. Examination of the placenta. *Obstet Gynaecol* 1961; 18: 309.
2. Brosen I, Dixon HG, Robertson WB. Fetal growth retardation and the arteries of the placental bed. *Br J Obst Gynaec* 1977; 84: 656-63.
3. Fox H. The morphological basis of placental insufficiency. *J Obstet Gynaec India* 1975; 25 (4): 441-50.
4. Majumdar S, Dasgupta H, Bhattacharya K, Bhattacharya A. A study of placenta in normal and hypertensive pregnancies. *J Anat Soc India* 2005; 54(2); 34-8.
5. Falkay G, Melis K, Kovacs L. Correlation between beta and alpha adrenergic receptor concentrations in human placenta. *J Recept Res* 1994; 14(3-4): 187-95.
6. Anderson HR, Mckey DG. Electron microscopic study of the trophoblast in normal and toxemic placentas. *Am J Obst Gynaecol* 1966; 95: 1134.

7. Jones CJP, Fox H. An ultrastructural and ultrahistochemical study of the human placenta in maternal preeclampsia. *Placenta* 1980; 1: 61- 76
 8. Mirchandani JS, Mallik GB, Chitra S. Villous fibrinoid necrosis and basement membrane thickening in toxemia of pregnancy and its intrauterine growth retardation. *J Obst. Gynaecol India* 1979; 29: 1131.
 9. Masodkar AR, Kalamkar LR, Patki PS. Histopathology of placenta and its correlation with fetal outcome. *J Obst Gynaecol India* 1985; 35:294.
 10. Sodhi S, Mohan H, Rathee S. and Mohan. Placental pathology in pre-eclampsia syndrome. *Indian J Pathol Microbiol* 1990; 33: 1; 11-6.
 11. Majumdar S, Dasgupta H, Bhattacharya K, Bhattacharya A. A study of placenta in normal and hypertensive pregnancies. *J Anat Soc India* 2005; 54(2); 34-8.
 12. Fox H. The significance of villous syncytial knots in the human placenta. *J Obst Gynaecol Br Common W* 1965; 74: 28.
 13. Fox H. The villous cytotrophoblast as an index of placental ischaemia. *J Obstet Gynaecol J Br Common W* 1964; 71: 885.
 14. Genset DR. Estimating the time of death of stillbirth fetuses-II. A study of 71 stillborns. *Br J Obstet Gynaecol* 1992; 80: 585-92.
 15. Krielessi V, Papantoniou N, Papageorgiou I, Chatzipapas I, Manios E, Zakopoulos N, et al. Placental Pathology and Blood Pressure's Level in Women with Hypertensive Disorders in Pregnancy. *Obstet Gynecol Int* 2012; 2012:684083.
 16. Ezeigwe CO, Okafor CI, Eleje GU, Udigwe GO, Anyiam DC. Placental peripartum pathologies in women with preeclampsia and eclampsia. *Obstet Gynecol Int* 2018; 2018: 9462938.
- Khalil A, Muttukrishna S, Harrington K, Jauniaux E. Effect of Antihypertensive therapy with alpha methyl dopa on levels of angiogenic factors in pregnancies with hypertensive disorders. *PLOS ONE* 2008; 3(7): e2766.

Copyright © 2022 Journal of Research in Applied and Basic Medical Sciences

This is an open-access article distributed under the terms of the Creative Commons Attribution-noncommercial 4.0 International License which permits copy and redistribute the material just in noncommercial usages, provided the original work is properly cited.