



## Ultrasound for the diagnosis of bleeding in the first trimester of pregnancy

Pilli Srujana<sup>1\*</sup>, Bangaru Bhavani<sup>2</sup>, Ameenulla Hafeezuddin Shaik<sup>3</sup>

<sup>1</sup> Assistant Professor, Department of Radio Diagnosis, Kakatiya Medical College, Warangal, Telangana State, India

<sup>2</sup> Assistant Professor, Department of Radio Diagnosis, Kakatiya Medical College, Warangal, Telangana State, India

<sup>3</sup> Assistant Professor, Department of Radio Diagnosis, Kakatiya Medical College, Warangal, Telangana State, India

**\*Corresponding authors:** Pilli Srujana, **Address:** Department of Radio Diagnosis, Kakatiya Medical College, Warangal, Telangana State, India, **Email:** srujana.rad@rediffmail.com. **Tel:** 0870-2446888

### Abstract

**Background & Aims:** Abortions, ectopic pregnancy, and molar pregnancy are the common causes of bleeding during the first trimester. Current study evaluated the first trimester bleeding and prognosticate and predict the status of abnormal pregnancies using ultrasound scan.

**Materials & Methods:** In this observational study, total 100 pregnant of aged from 22 to 34 years with first-trimester vaginal bleeding were examined by Ultrasonography. Demographics, obstetric history such as age, parity, gravidity bleeding severity, ultrasonography results, and clinical diagnosis referred in categorical data and analysed using Chi-square analysis. Statistical analyses were done by SPSS ver. 24.

**Results:** Spotting in 40%, light in 28%, and heavy in 32% of the pregnant in heaviness of bleeding. 73% of pregnant reported spontaneous bleeding. Threatened abortion clinically diagnosed in 52 cases; Ultrasonography confirmed 24 pregnant as threatened abortions and aids in correctly diagnosing 8 cases that were missed on clinical examination. 24 pregnant women out of 36 threatened abortions were continued to term, with a 66 % success rate. Ultrasonography correctly diagnosed pregnant women who were threatened with abortion (n=36), incomplete abortion (n=20), missed abortion (n=8), ectopic (n=8), inevitable abortion (n=8), blighted ovum (n=4), and Hydatidiform mole (n=4). 96 out of 100 pregnant were correctly diagnosed by Ultrasound when compared to 72 out of 100 cases on the basis of clinical diagnosis with a disparity of 64%. On follow-up, six cases of threatened abortion were terminated.

**Conclusion:** Ultrasonography plays an important role in the etiological diagnosis of bleeding in the first trimester of pregnancy; in most cases, a responsible abnormality of bleeding is easily identified. Using Ultrasonography, misdiagnosis at first trimester can be avoided.

**Keywords:** Ultrasonography, First Trimester Bleeding, Accuracy, Blighted Ovum

Received 16 June 2022; accepted for publication 15 September 2022

## Introduction

Vaginal bleeding during the first trimester of pregnancy is a common obstetric problem that causes both the patient and the obstetrician anxiety and concern (1). Spotting is the most common type of bleeding caused by conceptus implantation into the endometrium. In early pregnancies, the incidence of first trimester bleeding per vaginam is estimated to be between 7 to 24%. The clinical history and pelvic examination are insufficient for determining the cause and prognosis (2, 3).

The social phenomena of increasing maternal age and heightened expectations for a normal outcome have increased obstetrician pressure, resulting in increased use of ultrasonography (4). Transvaginal and transabdominal Ultrasonography are used to assess the risk factors for first trimester bleeding, as well as to diagnose and predict the outcome of abnormal pregnancies (5). Amniotic fluid volume abnormalities can be calculated, especially in high-risk pregnancies (6-10). The diagnosis of a normal intrauterine pregnancy assists the obstetrician in managing the pregnancy and provides psychological relief to the patient.

Hence, the purpose of this study was to compare the utility of ultrasonography versus clinical examination findings in first-trimester vaginal bleeding.

## Materials & Methods

Institutional Ethics Committee approved the study protocol, and an informed consent obtained from all the study participants. Total 100 pregnant with a history of bleeding in the first trimester of pregnancy were included in the study during October 2012 and June 2014.

Pregnants with clinically suspected first trimester bleeding (< 12 completed weeks) were included in the study. All non-obstetric causes/risk factors of vaginal bleeding as well as pregnant with more than 12 weeks of gestation were excluded. Pregnants thoroughly studied about total obstetric history, clinical examination and undergone transabdominal sonography.

Ultrasonography performed with linear/sector 3.5 MHZ frequency transducer and transvaginal Ultrasonography by 5 MHZ probes (ESOATE BIOMEDICA EU5 API, GE LOGIQ  $\alpha$ -200, ALOKA SSD-4 FLEXUS). DICOM software (ESOATE) and Digital Camera images were analyzed. Transvaginal sonography was done in pregnant suspected of ectopic pregnancy. Follow-up Ultrasonography performed in pregnant with threatened abortion till delivery.

**Statistical analysis:** Demographics, obstetric history such as age, parity, gravidity bleeding severity, ultrasonography results, and clinical diagnosis referred in categorical data and analysed using Chi-square analysis. Statistical analyses were done by SPSS software version 24.0 (IBM, NY, USA).

## Results

Pregnancies ranging in age from 22 to 34 years, with gravidities ranging from one to five. 60% of the pregnant had multipara, and 34 of the pregnant were from consanguineous marriages. The average gestational age was 9 weeks, and half of the patients presented between 8 and 10 weeks of their pregnancy. The majority were housewives of 54%, followed by students of 22%. Total 73% reported spontaneous bleeding, with the remainder caused by sexual intercourse and work. Spotting occurs in 40%, light in 28%, and heavy in 32% of pregnant women. There was a statistically significant ( $p=0.002$ ) relationship between ultrasonography findings and bleeding severity. The presence of blood clots was associated with ultrasonography findings in a statistically significant way ( $p=0.035$ ). The majority of pregnant women (40%) present with 3 to 4 days of bleeding. 45% of the cases were presented with pain at their abdomen before, during, or after bleeding.

### Ultrasonography Findings:

Ultrasonography revealed that 28 (56 %) of pregnant women had a gestational sac, with 36 facing abortion. The Fetal node was visualised in 42 pregnant women, and 36 of them had fetal cardiac activity. Four pregnancies with no fetal cardiac activity were classified as unavoidable abortions, with one case classified as a

missed abortion. Of the 6 pregnant women who showed less liquor, 4 were forced to have abortions and 2 were threatened with abortions. The yolk sac was found in 24 pregnant women. Abortion was deemed a threat to all pregnant women. The placenta was observed in 12 pregnant women.

**Clinical Diagnosis vs. Ultrasonography:**

Clinically diagnosed cases revealed that only 18 of 52 suspected or threatened abortions were confirmed on sonography, with 12 cases continuing to term gestation. 10 cases of threatened abortion were misdiagnosed as incomplete abortions. 8 cases of clinically diagnosed threatened abortion turned out to be complete abortion. 4 cases of unavoidable abortion, as well as two cases of

missed abortion, Hydatidiform mole, and anembryonic gestation were misdiagnosed as threatened abortion. Only 10 of 32 clinically diagnosed cases of incomplete abortion were confirmed. Six missed and threatened abortions were misdiagnosed as incomplete abortions. Clinically, 4 cases of missed abortion and 2 cases each of inevitable abortion, ectopic pregnancy, and embryonic gestation were misdiagnosed as incomplete abortion. In two cases, the unavoidable abortion was missed, and the Hydatidiform mole was correctly diagnosed clinically. Ultrasound confirmed 8 of the 8 clinically suspected ectopic pregnancies.

Table 1. represents follow up results of clinically diagnosed pregnant.

**Table 1.** Follow up of clinically diagnosed pregnant

Diagnosis	No of cases clinically diagnosed	Follow up and results
Threatened Abortion	52	Normal pregnancy (n=24) incomplete Abortion (n=10) complete Abortion (n=8) inevitable Abortion (n=4) missed Abortion (n=2) Hydatidiform mole (n=2) anembryonic gestation (n=2)
Ectopic Gestation	8	Total 8 cases were correctly diagnosed
Incomplete Abortion	32	incomplete Abortion (n=10) threatened Abortion (n=6) complete Abortion (n=6) missed Abortion (n=4) inevitable Abortion (n=2) embryonic gestation (n=2) anembryonic gestation (n=2)
Inevitable Abortion	4	inevitable Abortion (n=2) incomplete Abortion (n=2)
Missed Abortion	2	missed Abortion (n=2)
Hydatidiform mole	2	Hydatidiform mole (n=12)

**Follow-up of Cases Diagnosed on Ultrasonography:**

Following up on sonologically diagnosed pregnant showed that out of 36 threatened abortions, 24 continued

to normal term gestation while 12 presented with miscarriage. On repeat ultrasound, 2 of the 12 pregnant women had missed abortions, 4 had incomplete

abortions, and 4 had complete spontaneous abortions. All 8 pregnant of ectopic gestation were correctly diagnosed on ultrasound. Only 10 of the 12 sonologically diagnosed complete abortion cases were correctly diagnosed, while 2 cases of ectopic pregnancy were misdiagnosed as complete abortion. 20 cases of incomplete abortion, 8 cases of inevitable abortion, 8

cases of missed abortion, 4 pregnant of Hydatidiform mole, and 4 pregnant of anembryonic gestation were all correctly diagnosed on ultrasound.

Table 2. represents association between clinical diagnosis with final diagnosis, ultrasonography diagnosis with final diagnosis, and clinical diagnosis with ultrasonography diagnosis in the studied patients.

**Table 2.** Association between clinical diagnosis with final diagnosis; ultrasonography diagnosis with final diagnosis; and clinical diagnosis with ultrasonography diagnosis.

Diagnosis	Viable pregnancy	intrauterine	Ectopic Pregnancy	Nonviable intrauterine pregnancy
<b>Association between Clinical diagnosis with Final diagnosis</b>				
True positive	30		8	2
False Positive	20		0	8
False-negative	6		2	22
True negative	42		90	38
Sensitivity	84.2		81	60
Specificity	65		100	83
PPV	58		100	81
NPV	88		97	64
Accuracy	72		98	70
<i>P value</i>	<0.0001		<0.0001	0.002
<b>Association between ultrasonography diagnosis with Final diagnosis</b>				
True positive	36		8	54
False Positive	0		0	2
False-negative	0		2	0
True negative	64		90	44
Sensitivity	100		80	100
Specificity	100		100	96
PPV	100		100	96
NPV	100		98	100
Accuracy	100		98	98
<i>P value</i>	<0.0001		<0.0001	<0.0001
<b>Association between Clinical diagnosis with ultrasonography</b>				
True positive	30		6	32
False Positive	22		2	8
False-negative	6		2	24
True negative	42		90	36
Sensitivity	84		75	57
Specificity	65		98	82
PPV	57		75	80

NPV	87	98	60
Accuracy	72	96	68
<i>P value</i>	<i>&lt;0.0001</i>	<i>&lt;0.0001</i>	<i>0.05</i>

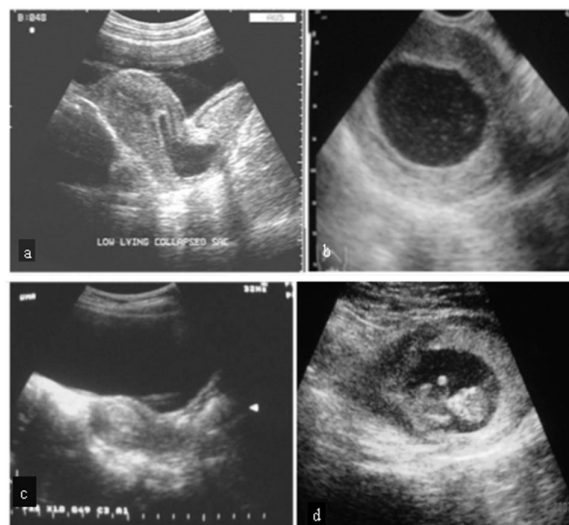
*PPV: positive predictive value; NPV:negative predictive value*

Based on clinical examination, 30 out of 100 suspected viable intrauterine gestation cases were confirmed as high false-positive cases (n=22). Of the 8 ectopic pregnancies diagnosed clinically, all were confirmed with both specificity and Positive predictive value (PPV) of 100%. The clinical diagnosis of nonviable pregnancies had little statistical correlation.

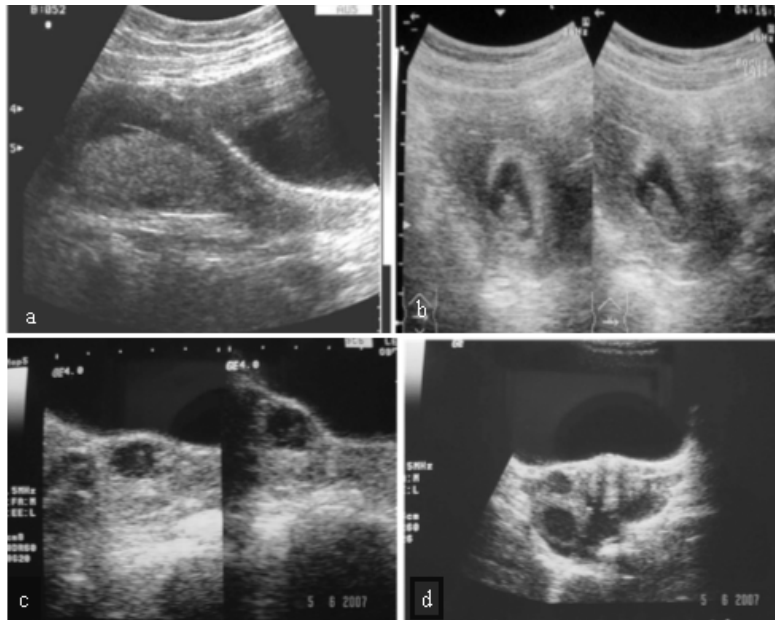
In the current study, 36 cases of viable intrauterine pregnancies were correctly diagnosed on ultrasound with zero false positives and zero false negatives, as well as 100% sensitivity, specificity, PPV, Negative predictive value (NPV), and accuracy.

80% of ectopic pregnancies were correctly diagnosed with specificity and PPV of 100%, while 2 cases were missed on sonography with sensitivity of 80%, NPV of 98%, and accuracy of 98%. The nonviable pregnancies detected by ultrasound were confirmed with 100% sensitivity and NPV, whereas two cases of false-positive complete abortion were detected with 96%

specificity, 96% PPV, and 98% accuracy. For the evaluation, ultrasound diagnosis proved to be extremely accurate (Table 2). In diagnosing viable pregnancies, our study has a sensitivity of 83, a PPV of 57, and an accuracy of 72 percent. The clinical diagnosis of ectopic pregnancy has a high specificity (98%), NPV (98%), and accuracy (96%) with a significant difference. According to this data, ultrasonography is far more accurate than clinical diagnosis. 60 of the 100 patients in our study were treated conservatively. Bed rest was administered in all cases of complete abortion. Laparotomy used to treat ectopic pregnancy cases. All incomplete abortion and anembryonic pregnancy was surgically removed. Dilatation and curettage were used to treat 2 cases of hydatidiform mole. On follow-up, 6 cases of threatened abortion were terminated, with 2 cases being complete abortions, 2 cases being missed abortions, and 2 cases with repeat bleeding, indicating incomplete abortions (Table 2, Figures 1 and 2).



**Fig 1.** a. inevitable Abortion, b. Blighted Ovum, c. Hydatidiform Mole, d. Subchorionic Bleed.



**Fig 2. a.** Retroplacental Bleed, **b.** Oligohydramnios. **c.** Ectopic Pregnancy, **d.** Ruptured Ectopic

## Discussion

The study included 100 pregnant women who had vaginal bleeding during the first trimester and were referred for an ultrasonography. The 100 pregnant women in this study ranged in ages from 22 to 34 years old, with an average age of 29. Gravity was measured on a scale of 1 to 5. This was consistent with the findings of other studies (11, 12). Most of them were housewives, and 34% of the pregnant women were of consanguineous marriages. This higher rate of housewives confirms that housewives are the most numerous in our socio-professional structure. The majority of them were multigravidas (60%). This occurrence has also been reported in other studies (2, 8). The risk of bleeding increased with a large number of gestures due to weakening dynamic changes in the uterus and cervix (13). This bleeding occurs between the implantation of the embryo in the uterus and 12th weeks of gestation, most commonly between 6 and 10 weeks. 73% of the pregnant women reported spontaneous bleeding; the remaining bleeding was caused by sexual intercourse and work. This is a delicate period of pregnancy, and bleeding can occur even if the trauma is minor. Patients who had incomplete abortions experienced the same

amount of bleeding as those who had complete abortions. In our study, as in others, the most common associated sign is pain (13,14).

Threatened abortion is the result of marginal abruption with separation of the chorion from the endometrial lining and subchorionic hemorrhage, which can lead to abortion. Our study's ultrasonographies showed that threatened abortion (24%) was the most common cause of first-trimester vaginal bleeding; 8 pregnant women with complete spontaneous abortion and the remaining continued to term gestation. Based on ultrasonography, 10% of the women in our study had incomplete abortions. Thobbi et al., identified 23.1% rate of incomplete abortion (15). Retained trophoblastic tissue causes persistent vaginal bleeding after abortion. Findings indicated heterogeneous hypoechoic material in the endometrial cavity, as well as retained trophoblastic tissue and blood clots (15). The most dangerous cause of first trimester bleeding was ectopic pregnancy bleeding in our study. Ectopic pregnancy affected 5% of the cases in our study. The rate of 5.2%, according to Belley et al., occurs when the fertilized egg is implanted outside of the uterus, such as in the Fallopian tube. The visualization of an annular adnexal

mass with/without a viable embryo was observed using ultrasonography. 8% of our cases were diagnosed as complete abortion. This is comparable to the studies done by Thobbi et al. and Coulibaly et al. of 9.1% (15, 16). The presence of myomas, the genetic abnormalities, the infectious diseases such as malaria were the main causes. On ultrasonography, uterus appears to be empty.

An anembryonic pregnancy or blighted ovum is an early failure of the embryo to develop within the gestational sac. 2% of the patients were diagnosed with blighted ovum in our study. Diariso observed 4.3% blighted ovum rate (14). The ultrasonographic finding was a gestational sac within the uterus with an irregular contour and no embryos, which could contain a yolk sac. In our study, the concordance between clinical diagnosis and ultrasonographic diagnosis was higher; only 36% of clinically diagnosed cases were confirmed on ultrasound, with a 64% disparity. When compared to Jaideep Malhotra et al. (17) and Reddirani et al. (18), the current study has a greater disparity between clinical and ultrasound diagnosis. In the current study, Ultrasound accurately diagnosed all the cases of threatened abortion, missed abortion, incomplete abortion, blighted ovum, hydatidiform mole, and inevitable abortion. According to ultrasonography findings, the most common cause of first-trimester vaginal bleeding is abortion, which is consistent with other studies. The findings of an ultrasonography show an empty bulky uterus or an intrauterine gestation sac with or without an embryo. In our study, 4% of pregnant women were diagnosed with complete abortion, which is similar to Coulibaly et al., at a rate of 9.1% (16). Sonography reveals an empty uterus. Abortion is defined as vaginal bleeding with complete expulsion of all products of conception after 20 weeks (19, 20).

In our study, 20% of the cases were classified as incomplete abortions, which is comparable to Yang et al., at a rate of 23.1% (21). Blood clots and residual trophoblastic tissue in the endometrial cavity are two sonographic findings. At 20 weeks of gestation, an incomplete abortion is defined as vaginal bleeding with partial expulsion of the products of conception (Figure 2).

The trophoblastic elements of the developing blastocyst are thought to go through proliferative changes caused by the persistence of chorionic villi from a blighted ovum, as well as from hydrated swelling (20, 21). It could be a full or partial mole. Trophoblastic hyperplasia occurs in the absence of an identifiable embryo and amniotic membrane in a complete molar pregnancy. This type of pregnancy accounts for approximately 90% of all molar pregnancies. Threatened abortions, incomplete abortion, molar pregnancy, stopped pregnancy, and ectopic pregnancy was characterized by adnexal mass, metrorrhagia, correctly diagnosed only through ultrasound, ectopic pregnancy, anembryonic pregnancy, and molar pregnancy (22).

We noticed that the patients with incomplete abortions had blood clots during bleeding. In normal viable intrauterine pregnancy, bleeding was spontaneous or induced coming from the closed cervix. Heavy bleeding occurred mainly in incomplete and complete abortions, while spotting and light bleeding occurred in threatened abortions, viable intrauterine pregnancy, and stopped pregnancies. Pelvic pain was the most frequently reported associated symptom. The bleeding was spontaneous and came from the uterus in threatened abortions, stopped pregnancies, and incomplete and complete abortions.

Threatened abortions, incomplete abortions, stopped pregnancy, molar pregnancy, and ectopic pregnancy were all characterized by metrorrhagia, pelvic pain, adnexal mass, and an open or closed cervix, and were only confirmed via ultrasound, which is the only way to diagnose ectopic pregnancy, anembryonic pregnancy, and molar pregnancy (23).

## Conclusion

Threatened abortions, incomplete abortions, stopped pregnancies, complete abortions, ectopic gestation, anembryonic gestation, and molar pregnancy are the most common causes of first trimester bleeding. Ultrasonography correctly diagnosed 96% of the cases, while clinical diagnosis diagnosed just 72 cases, with a disparity of 64%. Ultrasound is a non-invasive and

accessible method for examining the patients with first trimester bleeding with high accuracy in order to identify the actual cause of bleeding and guide clinicians in choosing the appropriate management.

**Acknowledgment:** Author acknowledged Dr. K. Suresh, Professor of Radiology of MNR Medical College, Sangareddy for his guidance.

**Source of Funding:** None

**Conflicts of Interest:** The authors declare no conflict of interest.

## References

1. Kavyashree HS, Rajeshwari K. A study on pregnancy outcome in patients with first trimester vaginal bleeding. *Int J Reprod Contracept Obstet Gynecol* 2019;8(3):820-5.
2. Gupta N, Samariya M, Choudhary D, Yadav K, Kannoujiya P. Ultrasonographic evaluation of first trimester bleeding per vaginam. *Int J Reprod Contracept Obstet Gynecol* 2016;5(9):3085-7.
3. Hasan R, Baird DD, Herring AH, Olshan AF, Funk ML, Hartmann KE. Patterns and predictors of vaginal bleeding in the first trimester of pregnancy. *Ann Epidemiol* 2010;20(7):524-31.
4. Kk S. A comparative study of ultrasonographic evaluation of vaginal bleeding in pregnancy with clinical examination. *Int J Reprod Contracept Obstet Gynecol* 2019 ;8(4):1250-4.
5. Pandya DD, Patel RV, Patel SV, Deliwala DJ, Shah PT, Patel MS. Role Of Ultrasound In First Trimester Bleeding Per Vaginam. *Natl J Integr Res Med* 2021;12(3).
6. David AL, Turnbull C, Scott R, Freeman J, Bilardo CM, Van Maarle M, Chitty LS. Diagnosis of Apert syndrome in the second-trimester using 2D and 3D ultrasound. *Prenatal Diagnosis: Published in Affiliation With the International Society for Prenatal Diagnosis* 2007;27(7):629-32.
7. Tonni G, Centini G. Three-dimensional first-trimester transvaginal diagnosis of alobar holoprosencephaly associated with omphalocele in a 46, XX fetus. *Am J Perinatol* 2006;23(01):67-70.
8. Roman AS, Monteagudo A, Timor-Tritsch I, Rebarber A. First-trimester diagnosis of sacrococcygeal teratoma: the role of three-dimensional ultrasound. *Ultrasound Obstet Gynecol* 2004;23:612.
9. Pajkrt E, Jauniaux E. First-trimester diagnosis of conjoined twins. *Prenat Diagn* 2005;25:820.
10. Gadelha PS, Da Costa AG, Mauad Filho F, El Beitune P.. Amniotic fluid volumetry by three-dimensional Ultrasonography during the first trimester of pregnancy. *Ultrasound Med Biol* 2006;32:1135.
11. Aronu ME, Okafor CO, Mbachui II, Iloraah US, Ikeako L, Okafor CI. A review of the correlation between clinical diagnosis and ultrasound diagnosis in first trimester vaginal bleeding. *Ann Med Health Sci Res* 2018;8(2):120-4.
12. Belley Priso E, Moifo B, Zeh O, Nana Njamen T, Foumane P, Nguemgne C, et al. Contribution of Emergency Ultrasonography in the Management of Bleeding during the First Trimester of Pregnancy at the Douala General Hospital. *African J Med Imaging* 2010;3:187-96.
13. Enaruna N, Anya C, Anyanwu C. Early and late pregnancy complications in women who experience first trimester vaginal bleeding at a University Hospital, Benin City, Nigeria. *J Med Biomed Res* 2020;19(1):23-32.
14. Diarisso A. First Trimester Hemorrhages at Nianankorofomba de Segou hospital. End of Study Medicine Thesis, University of Bamako, Mali, 2012:90.
15. Thobbi VA, Deshpande G, Afreen UA, Nooreen R. Ultrasonographic evaluation of first trimester vaginal bleeding. *Al Ameen J Med Sci* 2016;9(2):107-11.
16. Coulibaly N. Study of the First Trimester of Bleeding in the Gynecology and Obstetrics Department of the Reference Health Center of Commune V of BAMAKO District. End of Study Medicine Thesis, University of Bamako, Mali. 2010.
17. Malhotra J, Saxena K, Malhotra N. Ultrasound evaluation of first trimester bleeding per vaginam. *J Obstetr Gynecol India* 1987;37:341-3
18. Reddirani P, Sunita V. Ultrasound evaluation of the cause of vaginal bleeding in the first trimester of pregnancy. *J Obstet Gynecol India* 2000;50(1):54-8.



19. Boco V, Akpovi J, Takpara I, Latoundji MC, Lantokpode JC, Perrin R. Interest of Ultrasound in Metrorrhagia of the First Trimester Pregnancy. *Med Afr Noire* 1997; 44:97-100.
20. Guena MN, Alapha FZ, Kemeagne DC, Nana AN, Zeh OF, Fotsing JG. Ultrasound Study of First Trimester Bleeding. *Open J Radiol* 2019;9(1):58-68.
21. Yang J, Hartmann KE, Savitz DA, Herring AH, Dole N, Olshan AF, Thorp Jr JM. Vaginal Bleeding During Pregnancy and Preterm Birth. *Am J Epidemiol* 2004;160:118-25.
22. Singh K. Assessment of First Trimester Vaginal Bleeding Using Ultrasound Sonography. *Asian J Biomed Pharmaceutical Sci* 2016;6: 54-6.

**Copyright © 2022 Journal of Research in Applied and Basic Medical Sciences**

This is an open-access article distributed under the terms of the [Creative Commons Attribution-NonCommercial 4.0 International License](https://creativecommons.org/licenses/by-nc/4.0/) which permits copy and redistribute the material just in noncommercial usages, provided the original work is properly cited.