

See discussions, stats, and author profiles for this publication at: <https://www.researchgate.net/publication/258112686>

A 68-year-old man with Angioedema due to Enalapril

Article in *Life Science Journal* · December 2013

CITATIONS

0

READS

56

14 authors, including:



[Sajjad Ahmadi](#)

Urmia University of Medical Sciences

23 PUBLICATIONS 7 CITATIONS

[SEE PROFILE](#)



[Seyed Hesam Rahmani](#)

Urmia University of Medical Sciences

35 PUBLICATIONS 26 CITATIONS

[SEE PROFILE](#)



[Gholamreza Faridaalae](#)

Maragheh University of Medical Sciences

31 PUBLICATIONS 27 CITATIONS

[SEE PROFILE](#)



[Omid Mashrabi](#)

Tabriz University of Medical Sciences

39 PUBLICATIONS 28 CITATIONS

[SEE PROFILE](#)

Some of the authors of this publication are also working on these related projects:



Comparison of Intravenous Metoclopramide and Acetaminophen in Primary Headaches: a Randomized Controlled Trial [View project](#)

A 68-year-old man with Angioedema due to Enalapril

Sajjad Ahmadi¹, Hamidreza Morteza Baghi², Hamidreza Mehryar¹, Yousef Nouri³, Parasto Hosseini³, Seyed Hesam Rahmani^{1*}, Gholamreza Farid Aalae¹, Omid Mashrabi⁴, Mohsen Nagahi⁵, Maryam Mousavi⁶

1- Assistant Professor of Emergency Medicine, Emergency Medicine Department, Faculty of Medicine, Urmia University of Medical Sciences, Urmia, Iran.

2- Assistant Professor of Emergency Medicine, Emergency Medicine Department, Faculty of Medicine, Tabriz University of Medical Sciences, Tabriz, Iran.

3- Specialist of Emergency Medicine, Emam Khomeini Hospital, Faculty of Medicine, Urmia University of medical sciences, Urmia, Iran.

4- Resident of Internal Medicine, Internal Medicine Department, Faculty of Medicine, Tabriz University of Medical Sciences, Tabriz, Iran.

5- General Physician, Faculty of Medicine, Iran University of medical sciences, Tehran, Iran.

6- General Physician, Faculty of Medicine, Ardabil Branch, Islamic Azad University, Ardabil, Iran.

*_Corresponding author: Seyed Hesam Rahmani(hesam_ri@yahoo.com)

Abstract: A 68-year-old man presents to the emergency department with nausea, drooling, and swelling of his tongue that began 3 hours earlier. The patient reports previous episodes of swelling of his lip and tongue about 4 years ago, that have been attributed possibly to drug reaction. There is no family history of similar episodes. Physical examination reveals a swollen tongue and hypertension, drooling, flushing, and no rash, bronchospasm, or urticaria.

[Ahmadi S, Morteza Baghi H, Mehryar H, Nouri Y, Hosseini P, Rahmani SH, Farid Aalae G, Mashrabi O, Nagahi M, Mousavi M. **A 68-year-old man with Angioedema due to Enalapril.** *Life Sci J* 2013;10(11s):208-210] (ISSN:1097-8135). <http://www.lifesciencesite.com>. 36

Keywords: Angioedema, Enalapril

1. Introduction

Angioedema or Quincke's edema is the rapid swelling (edema) of the dermis, subcutaneous tissue,(1) mucosa and sub mucosal tissues. It is very similar to urticaria, but urticaria, commonly known as hives, occurs in the upper dermis(Zuraw, 2008).

Cases where angioedema progresses rapidly should be treated as a medical emergency as airway obstruction and suffocation can occur(Bork and Barnstedt, 2003).

Angioedema is classified as either acquired or hereditary. Acquired angioedema is usually caused by allergy and occurs together with other allergic symptoms and urticaria. It can also happen as a side-effect to certain medications, particularly ACE inhibitors (Bas, 2007).

Sometimes, there has been recent exposure to an allergen (e.g. peanuts), but more often the cause is either idiopathic (unknown) or only weakly correlated to allergen exposure.

HAE may also cause swelling in a variety of other locations, most commonly the limbs, genitals, neck, throat, and face. The pain associated with these swellings varies from mildly uncomfortable to agonizing pain, depending on its location and severity.

ACE inhibitors can induce angioedema (Sabroe and Black, 1997; Israili and Hall, 1992; Kostis, 2005). ACE inhibitors block the enzyme ACE so that it can no longer degrade bradykinin; thus bradykinin accumulates and causes angioedema (Sabroe and Black, 1997; Israili and Hall, 1992). This complication appears more common in African-Americans (Brown, 1996). In people with ACE inhibitor angioedema, the drug needs to be discontinued and an alternative treatment needs to be found, such as an angiotensin II receptor blocker (ARB)(Dykewicz, 2004) which has a similar mechanism but does not affect bradykinin. However, this is controversial as there are small studies that have shown that patients with ACE inhibitor angioedema can develop it with ARBs as well (Malde, 2007; Cicardi, 2004).

2. Case study

A 68-year-old man presents to the emergency department with nausea, drooling, and swelling of his tongue that began 3 hours earlier (Figure 1 and 2). The patient reports previous episodes of swelling of his lip and tongue about 4 years ago, that have been attributed possibly to drug reaction. There is no family history of similar episodes. Physical examination reveals a swollen

tongue and hypertension, drooling, flushing, and no rash, bronchospasm, or urticaria.

His vital signs include BT= 37.2, RR= 18, PR= 82 and O₂sat= 98%. His usual outpatient medication includes Enalapril from 5 years ago.

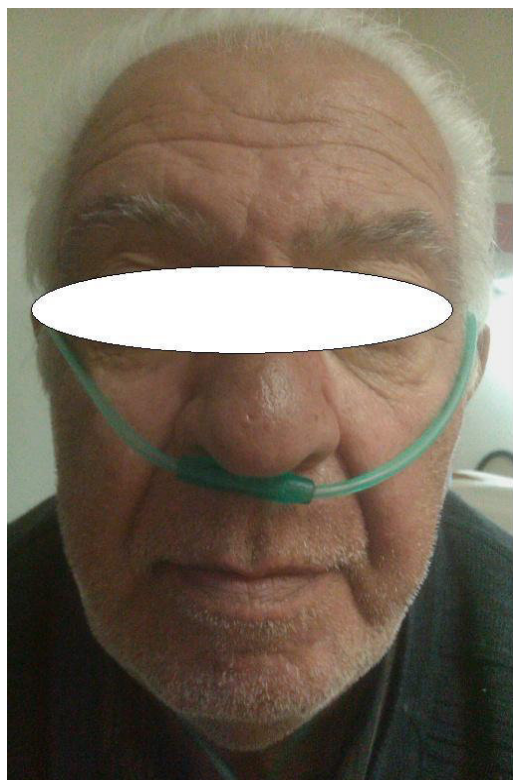

Figure 1

He has recent exposure to Indomethasine (yesterday). No improvement was noted after the parenteral administration of hydrocortisone and intramuscular chlorpheniramine before ED arrival.

In the ED after parenteral administration of labetalol hypertension was controlled and intramuscular epinephrine administered. The tongue returned to normal size after 2 hours. Treatment with Enalapril and Indomethasine was discontinued. C1 inhibitor was 0.249 (NL 0.29 _0.42).

4. Discussion

Hereditary angioedema (HAE) is a severe disease that places a heavy burden on quality of life (Bouillet, 2013).

Hereditary angioedema (HAE), caused by C1 inhibitor deficiency, is characterized by recurrent subcutaneous or sub mucosal swelling (Xu, 2013).

Angioedema occurs in 0.1% to 0.7% of patients treated with ACE inhibitors and ACE inhibitors account for 20% to 30% of all angioedema

cases presenting to emergency departments (Benson, 2013).

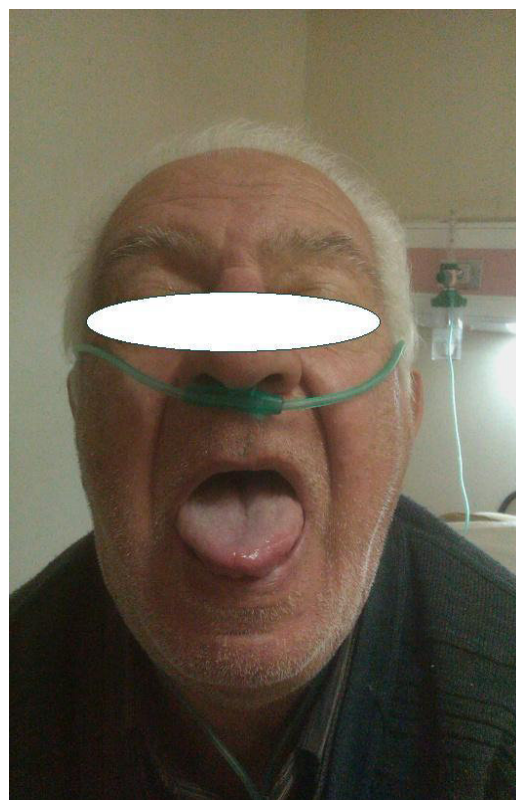


Figure 2

The most common sites of involvement are the tongue, lips, face, and throat; however, swelling can also occur in the extremities, genitalia, and viscera (Lewis, 2013).

Angiotensin-converting-enzyme inhibitors (ACEI) are one of the most prescribed medications worldwide. Angioedema is a well-recognized adverse effect of this class of medications, with a reported incidence of ACEI angioedema of up to 1.0%. Of importance to note, ACEI angioedema is a class effect and is not dose dependent (Winters, 2013).

Angiotensin-converting enzyme (ACE) inhibitors cause angioedema due to diminished degradation of bradykinin. Angiotensin receptor blockers may occasionally cause angioedema but the mechanism is unknown, and are generally considered safe, even in those who have reacted to ACE inhibitors (Joseph, 2013).

ACE inhibitor-induced gastrointestinal angioedema is a rare cause of acute abdominal complaints, but is likely underdiagnosed and should be considered in the differential diagnosis of all individuals taking ACE inhibitors with such symptoms (Benson, 2013).

Corresponding Author:

Dr. Seyed Hesam Rahmani
Emergency Medicine Department, Faculty of
Medicine, Urmia University of Medical Sciences,
Urmia, Iran.
E-mail: hesam_ri@yahoo.com

References:

- 1-Zuraw BL (2008). Clinical practice. Hereditary angioedema. *N. Engl. J. Med*; 359 (10): 1027–36.
- 2-Bork K, Barnstedt Se (2003). Laryngeal edema and death from asphyxiation after tooth extraction in four patients with hereditary angioedema. *J Am Dent Assoc*; 134 (8): 1088–94.
- 3- Bas M, Adams V, Suvorava T, Niehues T, Hoffmann TK, Kojda G (2007). Nonallergic angioedema: role of bradykinin. *Allergy*; 62 (8): 842–56.
- 4-Sabroe RA; Black AK (1997). Angiotensin-converting enzyme (ACE) inhibitors and angioedema. *British Journal of Dermatology*; 136 (2): 153–8.
- 5-Israili ZH; Hall WD (1992). Cough and angioneurotic edema associated with angiotensin-converting enzyme inhibitor therapy. A review of the literature and pathophysiology. *Annals of Internal Medicine*; 117 (3): 234–42.
- 6-Kostis JB, Kim HJ, Rusnak J, Casale T, Kaplan A, Corren J, Levy E (2005). Incidence and characteristics of angioedema associated with enalapril. *Archives of Internal Medicine*; 165 (14): 1637–42.
- 7-Brown NJ, Ray WA, Snowden M, Griffin MR (1996). Black Americans have an increased rate of angiotensin converting enzyme inhibitor-associated angioedema. *Clinical Pharmacologic Therapy*; 60 (1): 8–13. doi:10.1016/S0009-9236(96)90161-7. PMID 8689816.
- 8-Dykewicz MS (2004). Cough and angioedema from angiotensin-converting enzyme inhibitors: new insights into mechanisms and management. *Current Opinions in Allergy & Clinical Immunology*; 4 (4): 267–70. doi:10.1097/01.all.0000136759.43571.7f. PMID 15238791.
- 9-Malde B, Regalado J, Greenberger PA (2007). Investigation of angioedema associated with the use of angiotensin-converting enzyme inhibitors and angiotensin receptor blockers. *Annals of Allergy, Asthma, and Immunology*; 98 (1): 57–63. doi:10.1016/S1081-1206(10)60860-5. PMID 17225721.
- 10-Cicardi M, Zingale LC, Bergamaschini L, Agostoni A (2004). Angioedema associated with angiotensin-converting enzyme inhibitor use: outcome after switching to a different treatment. *Archives of Internal Medicine*; 164 (8): 910–3. doi:10.1001/archinte.164.8.910. PMID 15111379.
- 11-Bouillet L, Launay D, Fain O, Boccon-Gibod I, Laurent J, Martin L, Montauban V, et al(2013). Hereditary angioedema with C1 inhibitor deficiency: clinical presentation and quality of life of 193 French patients. *Ann Allergy Asthma Immunol*;111(4):290-4. doi: 10.1016/j.anai.2013.07.012. Epub 2013 Aug 6.
- 12-Xu YY, Jiang Y, Zhi YX, Yin J, Wang LL, Wen LP, et al (2013). Clinical features of hereditary angioedema in Chinese patients: New findings and differences from other populations. *Eur J Dermatol*;23(4):500-4. doi: 10.1684/ejd.2013.2105.
- 13-Benson BC, Smith C, Laczek JT(2013). Angiotensin Converting Enzyme Inhibitor-induced Gastrointestinal Angioedema: A Case Series and Literature Review. *J Clin Gastroenterol*; [Epub ahead of print]
- 14-Lewis LM (2013). Angioedema: Etiology, Pathophysiology, Current and Emerging Therapies. *J Emerg Med*; pii: S0736-4679(13)00587-8. doi: 10.1016/j.jemermed.2013.03.045. [Epub ahead of print]
- 15-Winters ME, Rosenbaum S, Vilke GM, Almazroua FY(2013). Emergency Department Management of Patients with ACE-inhibitor Angioedema. *J Emerg Med*; pii: S0736-4679(13)00599-4. doi: 10.1016/j.jemermed.2013.05.052. [Epub ahead of print]
- 16-Joseph K, Tholanikunnel TE, Kaplan AP(2013). In vitro comparison of bradykinin degradation by aliskiren, a renin inhibitor, and an inhibitor of angiotensin-converting enzyme. *J Renin Angiotensin Aldosterone Syst*; [Epub ahead of print]

10/12/2013