




Contents lists available at ScienceDirect

Asian Pacific Journal of Tropical Disease

journal homepage: www.elsevier.com/locate/apjtd



Document heading

doi:

© 2013 by the Asian Pacific Journal of Tropical Disease. All rights reserved.

Limnatis nilotica infestation in ram and kid in Dehloran city, Ilam province, west of Iran

Mahmoud Bahmani^{1*}, Maryam Rasouli², Pouya Parsaei³, Ebrahimkhalil Bahnihabib¹, Koroosh Saki¹, Fereidon Ghotbian⁴

¹Urmia University of Medical Sciences, Urmia, Iran

²Ferdowsi University of Mashhad, Mashhad, Iran

³Young Researchers Club, Shahrekord Branch, Islamic Azad University, Shahrekord, Iran

⁴Private Clinician of Dehloran City, Ilam Province, Iran

PEER REVIEW

ABSTRACT

Peer reviewer

Hassan Hassanzadazar, DVM, PhD of Food Hygiene, Food and Drug Deputy, Urmia University of Medical Science, Urmia, Iran.

Tel: +989144412026

Fax: +984413455839

E-mail: h.hassanzadazar@yahoo.com

Comments

This case report is a good report to note the vet clinicians and meat inspectors. The case being performed in order to show a case of anemia and weakness caused by *L. nilotica* infestation in kid and ram which is rarely mentioned by clinicians. It is important at the ability of vet clinicians to diagnosis of anemia causes.

(Details on Page 156)

Leech infestation can cause various clinical symptoms in human and animals. There are a few reports about this infestation in the world. In this report, we represented two cases of leech infestation of *Limnatis nilotica* in domestic kid and ram with anorexia, little respiratory disorders and restlessness in Dehloran city, Ilam province, west of Iran. Based on author's knowledge, there is no report of leech infestation on ram and kid and the present case is the first report of internal hirudiniasis of ram and kid due to *Limnatis nilotica* in literature.

KEYWORDS

Leech, *Limnatis nilotica*, Iran

1. Introduction

Leeches belong to the phylum Annelida and class Hirudinea[1–3]. They are blood sucking, hermapherodic parasites that attach themselves by their suckers to vertebrate host and suck out its blood[1]. Their length varies from 5 mm to 45 cm. Leeches can be divided into two classes depending on their biological habitat: land leeches and aquatic leeches[1,2,4].

Leeches that cause parasitic pollution in humans

are land or aquatic. Land leeches include *Haemadipsa zylanica*, *Haemadipsa sylvestris*, and *Haemadipsa picta*, while aquatic leeches include *Limnatis nilotica* (*L. nilotica*), *Myxobdella africana*, *Dinobdella ferox*, *Phytobdella catenifera*, and *Teromyzon tessulatom*[5–7]. Land leeches are common in tropical areas and aquatic leeches are reported worldwide[1,2,4]. Leeches can also be subdivided into internal and external leeches, according to their potential to infest internal or on external surfaces of the host, respectively[2].

*Corresponding author: Mahmoud Bahmani, Food and Beverages Safety Research Center, Urmia University of Medical Sciences, Urmia, Iran.

Tel: 0984412772023

Fax: 0984412787412

E-mail: mahmood.bahmani@gmail.com

Foundation Project: This study was conducted at collaboration with Urmia University of Medical Sciences, Urmia, Iran with Grant No. 32789.

Article history:

Received 12 Jan 2013

Received in revised form 15 Jan, 2nd revised form 19 Jan, 3rd revised form 22 Jan 2013

Accepted 12 Feb 2013

Available online 28 Apr 2013

Limnatis nilotica is an internal, aquatic leech that sticks to the mucous membrane of the pharynx, nasal cavity, nasopharynx and esophagus^[1,2]. Here we reported two different cases of *L. nilotica* infestation in ram and kid.

2. Case report

Two-year-old ram and 6-month kid were referred to the Dehloran veterinary clinic, Ilam province, west of Iran on June 2011 with anorexia, little respiratory disorders and severe restlessness with a history of drinking water from a spring.

On physical examination, a black object was seen on internal mucous membrane of upper lip in ram (Figure 1) and lower lip in kid (Figure 2). They were attached by drinking water from a leech-infested spring.

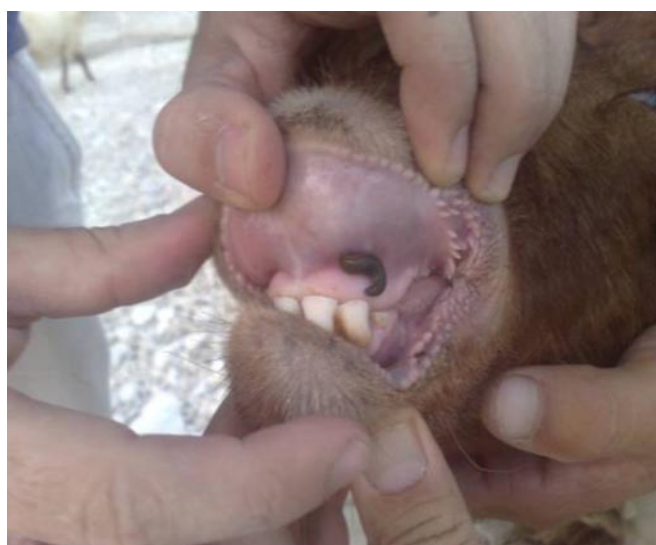

Figure 1. *L. nilotica* infestation in ram.

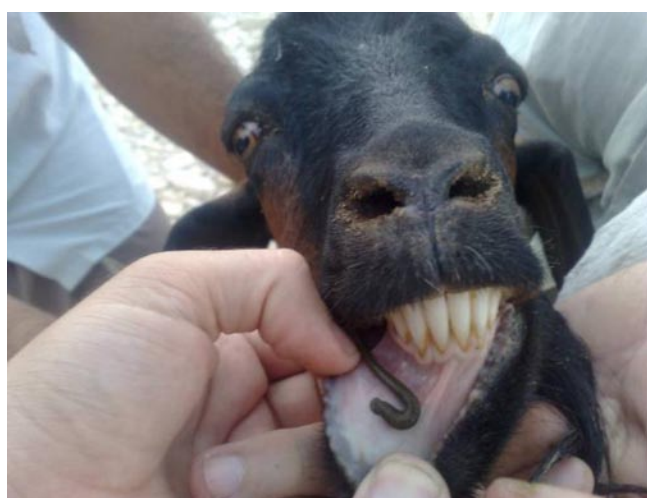


Figure 2. *L. nilotica* infestation in kid.

Black leeches were 63 mm in ram 58 mm in kid. After leeches removal, the ram and kid were comfortable under microscopic examination. Every detached leech was diagnosed as *L. nilotica*.

3. Discussion

Leeches can be useful in medicine for modern plastic surgery, drainage of periorbital and scrotal haematomas, but as parasites, they can also be dangerous and could cause problems and discomfort. Different types of leeches have been reported from different parts of human bodies^[8], but there are a few reports of different types of leeches infested animals like camel in Iraq or clinical report in a rare case of stillbirths in goat due to *L. nilotica*^[9,10]. In Iran, there are some reports of leech infested animals such as sheep, cattle, dog and donkey in Ilam province^[11,12], dog in Chahar–Mahale Bakhtiari province and cow^[13–15]. There was a case of adult ocular leech infestation that was reported by Khodabande in 2009^[16]. Ulkumen and Yilmaz have reported a case of respiratory distress and hemopytosis caused by laryngeal leech infestation in 2012^[17].

In all these cases, respiratory disorders and anemia are dominant symptoms. This report is the first one on leech infestation in kid. Leeches can suck the blood by anterior and posterior suckers. Different types of anemias depending on the duration of infestation and numbers of attached leeches can occur. They can also prevent clotting by production of a nonenzymatic secretion called hirudin^[1]. *L. nilotica* is the only species reported from clinical cases in Iran. Infested ponds, lakes and streams are the main habitat of this leech^[13]. After drinking water from the mentioned infested areas, leeches would mostly attach to the nose, nasopharynx, oropharynx, larynx and upper trachea^[13]. This infestation can be prevented by prohibiting drinking infested water by the animal owners. Therefore, the prevention and treatment of leech biting occurred in human and animals are necessary, and disinfection of water resources is an important way to prevent leech infestation^[18–26].

Conflict of interest statement

We declare that we have no conflict of interest.

Acknowledgements

This study was conducted at collaboration with Urmia University of Medical Sciences, Urmia, Iran with Grant No. 32789.

Comments

Background

Leech infestation can cause various clinical symptoms in human and animals. Based on the biological habitat, Leeches can be divided into land leeches and aquatic leeches. *L. nilotica* is a kind of aquatic leech. There are a few reports about *L. nilotica* infestation in the world.

Related reports

There are a few reports of different types of leeches infested animals. This report as a case report has an innovation in clinicians diagnosis specially in anemic animals and in animal slaughtering and meat inspection. In Iran, there are some reports of leech infested animals such as sheep, cattle, dog and donkey in Ilam province, dog in Chahar–Mahale Bakhtiari province and cow. Khodabande has reported a case of adult ocular leech infestation in 2009. Ulkumen and Yilmaz have reported a case of respiratory distress and hemopytsis caused by laryngeal leech infestation in 2012.

Peer review

This case report is a good report to note the vet clinicians and meat inspectors. The case being performed in order to show a case of anemia and weakness caused by *L. nilotica* infestation in kid and ram which is rarely mentioned by clinicians. It is important at the ability of vet clinicians to diagnosis of anemia causes.

References

- [1] Foonant S, Puntasri W, Manorot M, Niwasabutra S. A leech in the nasal cavity: case report. *Chiang Mai Med Bull* 2006; **45**(1): 27–30.
- [2] Guerrant RL, Walker DH, Weller PF. *Essentials of tropical infectious diseases*. Philadelphia: Churchill Livingstone; 2001, p. 607–608.
- [3] Stickland G. *Hunter's tropical medicine and emerging infectious disease*. 8th ed. Philadelphia: W.B. Saunders Company; 2000, p. 895.
- [4] Bilgen C, Karci B, Uluoz U. A nasopharyngeal mass: leech in the nasopharynx. *Int J Pediatr Otorhinolaryngol* 2002; **64**: 73–76.
- [5] Vera C, Blu A, Torres M. Leeches, today and yesterday present parasites. *Rev Chilena Infectol* 2005; **22**: 32–37.
- [6] Siddall ME, Budinoff RB, Borda E. Phylogenetic evaluation of systematic and biogeography of the leech Family Glossiphoniidae. *Invert Syst* 2005; **19**: 105–112.
- [7] Lewis G, Coombes A. Adult ocular leech infestation. *Eye (Lond)* 2006; **20**(3): 391–392.
- [8] Ađın H, Ayhan FY, Glfildan G, evik D, Derebaşı H. Severe anemia due to the pharyngeal leech *Limnatis nilotica* in a child. *Trkiye Parazitol Derg* 2008; **32**(3): 247–248.
- [9] Gharedaghi Y, Elmi VR, Zad MY. Clinical report a rare case of stillbirths in goat due to *Limnatis nilotica* species. *Vet Med J Isl Azad Uni Tabriz* 2010; **42**(14): 817–820.
- [10] Cheikh–Rouhou F, Besbes M, Makni F, Mchaabouni, Ayadi A. *Limnatis nilotica*, cause of severe anaemia in an infant. *Med Trop (Mars)* 2000; **60**: 100–101.
- [11] Bahmani M, Zamani P, Meshgi B, Zadeh RA. The first reported infestation in sheep at *Limnatis nilotica* in Iran. Sixth National Conference and the first Regional Congress of Parasitology and Parasitic Diseases. Karaj; 2006, p. 384.
- [12] Mehrzadi S, Jalali MHR, Bahmani M, Rahbar A. Report infestation of *Limnatis nilotica* (leech) in sheep, cattle, dogs and donkeys in the city of Dehloran. Sixth National Conference Veterinarians Clinical Sciences, Islamic Azad University of Tabriz. 2007, p. 648.
- [13] Bahmani M, Eftekhari Z, Mohsezaadeghan A, Ghotbian F, Alighazi N. Leech (*Limnatis nilotica*) causing respiratory distress in a pregnant cow in Ilam province in Iran. *Comp Clin Pathol* 2011; doi: 10.1007/s00580–011–1236–1.
- [14] Moghaddar N. Fatal hirudiniasis in a cow. *Comp Clin Pathol* 2010; doi: 10.1007/s00580–010–0969–6.
- [15] Bahmani M, Nekouei SH, Parsaei P, Saki K, Banihabib EK. Case report infestation with *Limnatis nilotica* in a Persian male dog from Shahrekord. *JMVR* 2011; **2**(6): 29–32.
- [16] Khodabande A. A case of adult ocular leech infestation. *Iranian J Ophthalm* 2009; **21**(4): 76–77.
- [17] Ulkumen B, Yilmaz S. A rare cause of respiratory distress and hemopytsis: Laryngeal leech infestation. *Pak J Med Sci* 2012; **28**(3): 543–545.
- [18] Bahmani M, Avijgan M, Hosseini SR, Qorbani M. Evaluating the anti *Limnatis nilotica* effects of tobacco methanol extract compared with succinyl choline and some other anti–parasite drugs. *Shahrekord J Med Sci* 2010; **12**(3): 53–59.
- [19] Bahmani M, Rafieian–kopaei M, Parsaei P, Mohsenzadegan A. The anti–leech effect of *Peganum harmala* L. extract and some anti–parasite drugs on *Limnatis nilotica*. *Afri J Microbiol Res* 2012; **6**: 2586–2590.
- [20] Eftekhari Z, Bahmani M, Mohsenzadegan A, Gholami–Ahangaran M, Abbasi J, Alighazi N. Evaluating the anti–leech (*Limnatis nilotica*) activity of methanolic extract of *Allium sativum* L. at compared with levamisole and metronidazole. *Comp Clin Pathol* 2011; doi: 10.1007/s00580–011–1268–6.
- [21] Farkhondeh T, Sadighara P, Bahmani E, Gholami–Ahangaran M, Moghtadaee E. The anti–parasite effect of garlet tablets on *Limnatis nilotica*. *J Herbal Drugs* 2011; **2**: 69–71
- [22] Bahmani M, Abbasi J, Mohsenzadegan A, Sadeghian S, Gholami–Ahangaran M. *Allium sativum* L.: the anti–immature leech (*Limnatis nilotica*) activity compared to Niclosomide. *Compa Clinic Pathol* 2011; doi: 10.1007/s00580–011–1380–7.
- [23] Gholami–Ahangaran M, Bahmani M, Zia–Jahrom N. *In vitro* Anti–leech effects of *Vitis vinifera* L., niclosamide and ivermectin on mature and immature forms of leech *Limnatis nilotica*. *Global Veterinaria* 2012; **8**: 229–232.
- [24] Bahmani M, Avijgan M, Gholami–Ahangaran M, Rafieian M. The comparison of anti–*Limnatis nilotica* effects of albendazole and some of the Iranian medicinal plants. *Boushehr Med Sci J* 2012; **15**: 201–206.
- [25] Bahmani M, Banihabib EKH, Saki K, Kazemi–Ghoshchi B, Heydari A, Hashemi M. Anti–leech and disinfection activities of methanolic extracts of walnut (*Juglans regida* L.) and oleander (*Nerium oleander* L.) on *Limnatis nilotica*. *World J Zool* 2012; **7**(3): 267–272.
- [26] Gholami–Ahangaran M, Bahmani M, Zia–Jahromi N. Comparative and evaluation of anti–leech (*Limnatis nilotica*) effect of olive (*Olea Europaea* L.) with Levamisole and Tiabendazole. *Asian Pac J Trop Dis* 2012; **2**(Suppl 1): S101–S103.