

## Cutaneous Metastasis of Bilateral Renal Cell Carcinoma

Fariba Abbasi,<sup>1</sup> Mansur Alizadeh,<sup>2</sup> Farahnaz Noroozina,<sup>3</sup> Amin Moradi<sup>4</sup>

### Abstract

Renal cell carcinoma (RCC) is a malignant lethal tumour with high potential of metastasis. However, metastasis from RCC to the skin is much less common. It is virtually a sign of poor prognosis.

We represent a 42 years old man with bilateral RCC of clear cell type followed by metastasis to the scalp one month later. In this case the relatively young age of the patient, bilaterality of RCC and occurrence of skin metastasis in the absence of recurrent kidney tumour are interesting.

**Keywords:** Carcinoma, Renal cell, Metastasis, Skin.

### Introduction

Renal cell carcinoma (RCC) accounts for 3% of all adult malignancies.<sup>1</sup> RCC has been well described for its tendency to metastasize, occurring in approximately one third of patients at the time of diagnosis.<sup>1,2</sup> However, metastasis from RCC to the skin is much less common.<sup>1</sup> It is usually a sign of poor prognosis.<sup>2</sup>

### Case Presentation

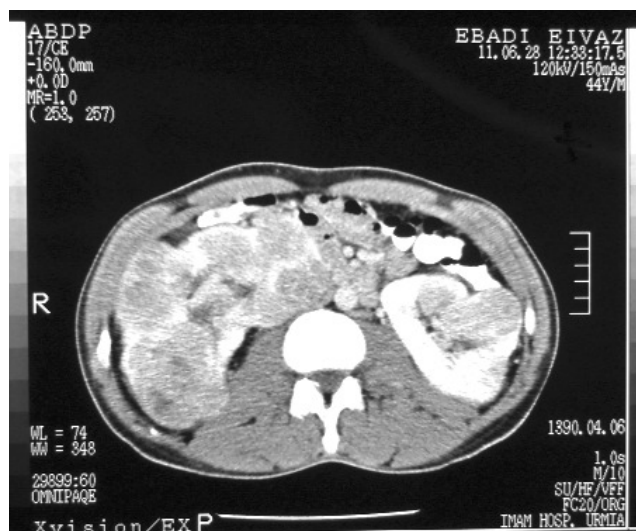
The patient was a 42 years old male, smoker and admitted with right flank pain and intermittent gross haematuria for 3 months. The routine haematology and biochemistry tests were normal. Computerized tomography scan (CT scan) revealed a heterogenous mass of 16 cm in diameter in the right kidney, multiple masses up to 3 cm in diameter in left kidney and para-aortic lymphadenopathy (Figure-1).

Although the patient was a little younger than the average common age of RCC (55-60 years) and suffered from bilateral renal cancer, no evidence of genetic syndromes was found.

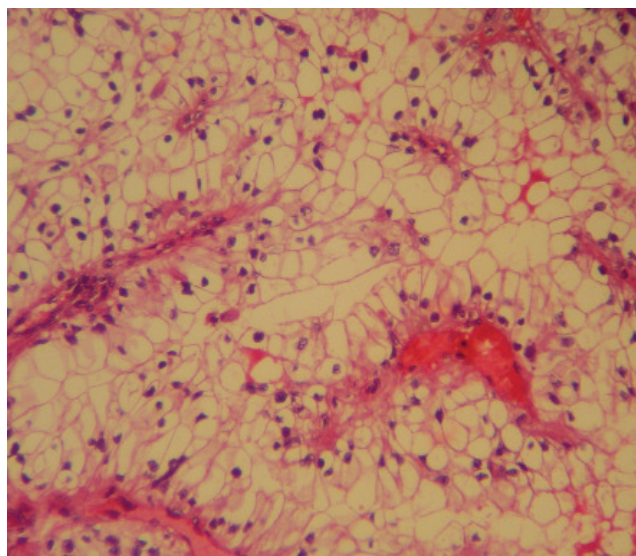
The patient was subjected to right sided nephrectomy, left sided kidney biopsy and para-aortic

.....  
<sup>1,3,4</sup>Department of Pathology, Faculty of Medicine, <sup>2</sup>Department of Urology, Faculty of Medicine, Urmia University of Medical Sciences, Urmia, Iran.

**Correspondence:** Fariba Abbasi. Email: faribaak2002@yahoo.com



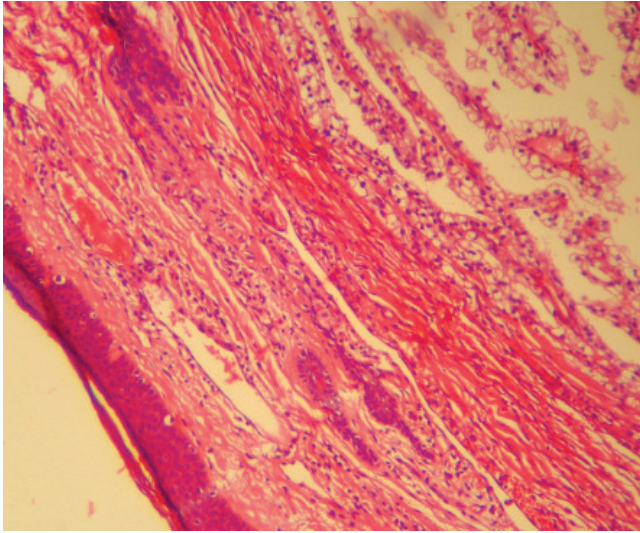
**Figure-1:** CT scan showing right tumoural kidney and multiple left sided kidney masses.



**Figure-2:** Clear cell carcinoma of kidney (X 400).

lymphadenectomy.

The resected right kidney was 18.5 × 10 × 9 cm. It was completely tumoural, except the pelvis. The tumour



**Figure-3:** Skin tissue involved by clear cell carcinoma (X 200).

was greyish - yellow and fairly soft. Ureter measured 3 cm in length and up to 0.5 cm in diameter. No capsular invasion was seen grossly.

The biopsy taken from left kidney was fairly soft and grey, and measured  $2 \times 1.5 \times 1.2$  cm.

The para-aortic lymph node was grey, and measured  $1.5 \times 1 \times 1$  cm.

Microscopic examination of the sections taken from the resected kidney stained with haematoxylin and Eosin (H & E), showed neoplastic proliferation of polygonal cells with clear cytoplasm, distinct cell borders, mildly pleomorphic nuclei with small nucleoli and rarely mitoses (Figure-2). Fuhrman nuclear grade was 2. Immunohistochemistry (IHC) staining for keratin and EMA were positive. Based on these findings, diagnosis of Clear Cell Carcinoma was confirmed. Vascular invasion was seen, but renal vein, renal capsule and ureter were intact.

Tumoural involvement with the same features was seen in biopsy from left kidney and also para- aortic lymph node.

The patient under went chemotherapy. One month later the patient was admitted with a scalp mass of  $3.5 \times 2 \times 0.5$  cm with elevated surface. On excision a well circumscribed nodule of 1.5 cm in diameter was seen. The microscopic examination of the sections taken from the nodule and stained by H&E revealed the histologic features of clear cell carcinoma (Figure-3).

No other systemic involvement was seen after a six

months period of follow up.

## Discussion

RCC is the most lethal of the urology cancers with a high tendency to metastasis.<sup>2</sup> Metastasis occurs in approximately one third of patients at the time of diagnosis.<sup>1,2</sup> As many as 40% of the other two thirds eventually will develop distant metastasis.<sup>2</sup> The most common site of distant metastasis is the lung.<sup>2</sup> Liver, bone, ipsilateral adjacent lymph node, adrenal gland and the opposite kidney are the other frequent sites of secondaries.<sup>2</sup> However, metastasis to the skin is much less common, accounting for 1% to 3% of all metastases of renal cell carcinoma.<sup>3</sup> The majority of these cases have been reported in patients with recurrent disease or with other metastases.<sup>4</sup> In our case, but no recurrent kidney tumour and also no other site of metastasis were present at the time of presentation of skin metastasis. On the other hand, metastasis of RCC to the skin account for 6% of all cutaneous metastases in males and 0.5% in females.<sup>5</sup> Supporting the previously reported indications our presented case is male, too.

The commonest site for cutaneous metastasis from RCC is the scalp and face.<sup>6</sup> Mostly, development of skin metastases takes places within six months to five years of the initial diagnosis and after performing the nephrectomy.<sup>3</sup> In this presented case, skin metastasis appeared only one month after nephrectomy. They are usually single lesions that grow rapidly, are bluish - red in color and sometimes pulsating.<sup>3</sup> Cutaneous metastasis of RCC means that the disease is widespread and has poor prognosis.<sup>2</sup> Most patients with cutaneous metastasis had at least one other site of systemic metastasis.<sup>2</sup> Brady et al reported an average interval of 12.7 months from the appearance of skin lesions to death.<sup>2</sup> Treatment of metastatic RCC consists of a combination of surgical interventions (radical nephrectomy) and angiogenesis/multikinase inhibitor.<sup>3</sup> However, treatment of single skin lesion is usually surgical except in certain cases in which radiotherapy is an option.<sup>3</sup>

Macroscopic differential diagnosis are angioma, cutaneous horn and basal cell carcinoma.<sup>3</sup> Mostly, RCC with cutaneous metastases are clear cell type, so microscopic differential diagnosis are xanthoma, xanthelasma, sebaceous tumours, balloon cell nevus, clear cell hidradenoma and other skin lesions characterized by the presence of clear cells.<sup>3</sup> The performing of IHC techniques makes it possible to

conduct differential diagnosis.<sup>3</sup> EMA, CEA, CD-10 and RCC- MA are all markers that suggest skin metastases of renal origin.<sup>3</sup>

As mentioned previously, cutaneous metastasis of RCC is a sign of poor prognosis and mostly there are other synchronous sites of systemic metastasis, so complete clinical and paraclinical examinations of all patients admitted with present or past history of RCC who suffered from skin metastasis is advisable to find any other possible site of metastasis. It should be noted that prompt diagnosis and treatment may affect the eventual outcome.

### **Acknowledgement**

We are grateful to Mr. Ali Jafari, technician of pathology for his assistance in processing and

staining the samples.

### **References**

1. Tunio MA, Rafi M, Hashmal A, Maqbool SA, Rizvi R. Renal cell carcinoma with initial presentation as erythematous skin metastasis. *J Surg Pak* 2010; 15: 159-60.
2. Aridogan IA, Satar N, Doran F, Tansug MZ. Scrotal skin metastases of renal cell carcinoma: A case report. *Acta Chir Belg* 2004; 104: 599-600.
3. Arrabal-Polo MA, Arias-Santiago SA, Aneiros-Fernandez J, Burkhardt-Perez P, Arrabal-Martin M, Naranjo-Sintes R. Cutaneous metastases in renal cell carcinoma: a case report. *Cases J* 2009; 2: 7948.
4. Porter NA, Anderson HL, AL- Dujaily S. Renal cell carcinoma presenting as a solitary cutaneous facial metastasis: case report and review of the literature. *Int Semin Surg Oncol* 2006; 3: 27.
5. Weedon D, Strutton G, Rubin AI. *Weedon's Skin Pathology*. 3rd Ed. China: Churvhil Livingstone, 2010; 932.
6. Dorairajan LN, Hemel AK, Aron M, Rajeev TP, Nair M, Seth A, Dogra PN, Gupta NP. Cutaneous metastasis in renal cell carcinoma. *Urol Int* 1999; 63: 164-7.