

Tuberculous (TB) Meningitis and Pneumonia in a Case of Hairy Cell Leukemia Treated by 2-CDA

Nasim Valizadeh,¹ Rahim Nejad Rahim,² Shahin Nateghi³

¹Department of Hematology-Medical Oncology, Urmia University of Medical Sciences, Urmia, Iran

²Department of Infectious Disease, Urmia University of Medical Sciences, Urmia, IRAN

³Medical Student, Department of Medicine, Urmia University of Medical Sciences, Urmia, IRAN

Corresponding author: Nasim Valizadeh, MD, Associated Professor of Hematology-Oncology
Department of Hematology- Oncology, Urmia University of Medical Sciences
Urmia, Iran
Tel.: +09125474755
Email:nsedaha0@gmail.com,

Abstract

Patients with lymphoproliferative disorders have cellular immune deficiency and are susceptible to typical and atypical mycobacterial infections. Hairy cell leukemia is a B-cell type lymphoproliferative disorder. 2-CDA is the choice of treatment for patients with hairy cell leukemia. It is a synthetic antineoplastic agent with immunosuppressive effects. We present development of pulmonary and meningeal TB in a case of hairy cell leukemia 8 months after treatment with 2-CDA.

Key words: Tuberculosis, Meningitis, Hairy cell leukemia

Introduction

Hairy cell leukemia (HCL) is categorized as a B lymphocyte malignancy which presents with splenomegaly, pancytopenia and bone marrow involvement by neoplastic cells. Having male to female ratio of 4/1, it represents 2% of adults' leukemia. (1, 2) Infection is the main cause of mortality and morbidity in patients with such hematologic neoplasms. (2)

Tuberculosis (TB) is a serious infection in HCL which may be induced or reactivated by factors such as defect in cell-mediated immunity, monocyte defect, administration of chemotherapy or high dose corticosteroid therapy. (3, 4)

We report a patient with hairy cell leukemia having tuberculosis meningitis and pneumonia.

Case report

A 46 y/o male a case of hairy cell leukemia since 8 months ago was admitted with agitation, loss of consciousness and cough. Diagnosis of hairy cell leukemia had been made 8 months ago because of pancytopenia and typical morphological findings in peripheral blood smear, bone marrow aspiration and bone marrow biopsy (Figures 1, 2, 3)

Flowcytometry and immunohistochemistry (IHC) for hairy cell leukemia are not available in our local laboratories. At that time he was treated with cladribine (2-CDA) 0.09 mg/kg continuous intravenous infusion over 7 days with G-CSF support. After discharge he did not have cooperation for follow up visits. His family said that he was well till 3 months ago when he developed fever, anorexia, night sweat, and cough. He was developed slowly progressive loss in level of consciousness and orientation since 4 weeks ago. Physical examination revealed: Temperature= 38.5°C, respiratory rate= 26/Min, pulse rate= 118/min, blood pressure= 120/70 mmHg, cachexia, pallor and nuchal rigidity. Brain CT scan was normal (Figure- 4). Chest X-ray showed bilateral diffuse millitary nodular pattern pattern involving both lung fields suggestive of tuberculosis (Figure- 5)

WBC= 11300/ μ L (PMN= 96%, Lymph= 2.1%, Mono= 1.2%), Hb= 15.7g/dl, Plt count= 120,000/ μ L. In peripheral blood smear, myeloid, erythroid and platelet series all were normal and we did not see any hairy cells. CSF fluid analysis showed: Pale color, reddish appearance, WBC= 260

(N= 75%, L= 25%), RBC= 10000, sugar=19 mg/dl, protein=28 mg/dl. CSF smear for gram stain and bacterial culture were reported negative but, CSF smear was positive for, bacille de Koch (BK). Results of other laboratory findings are showed in table- 1. Diagnosis of TB meningitis and pulmonary miliary TB was made in this patient with treated hairy cell leukemia and anti-tuberculosis was started.

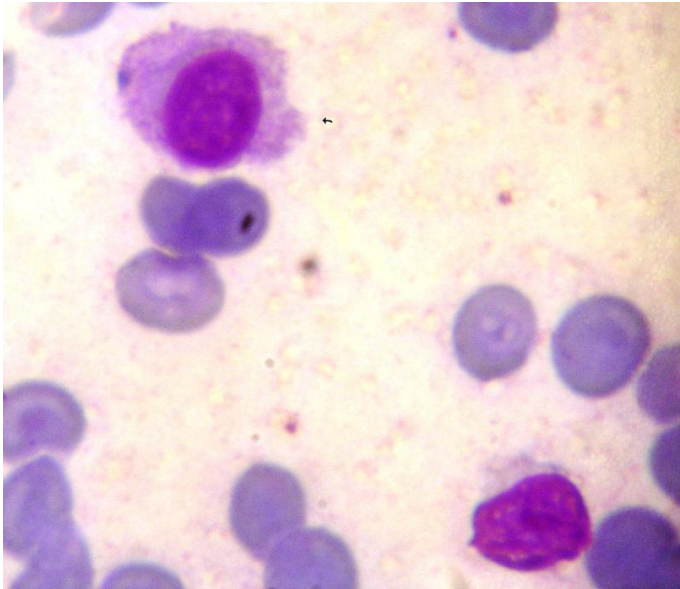


Figure- 1. Showing typical morphological findings in peripheral blood smear.

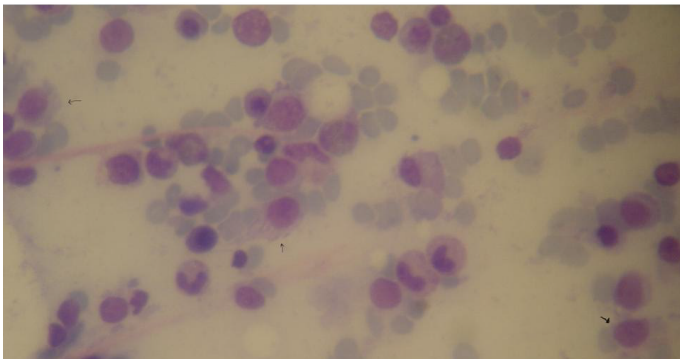


Figure- 2. Showing typical morphological findings in bone marrow aspiration.

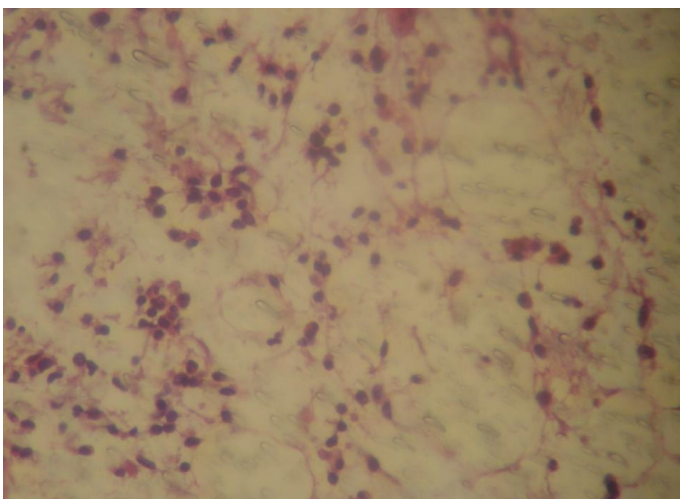


Figure- 3. Showing typical morphological findings in bone marrow biopsy.

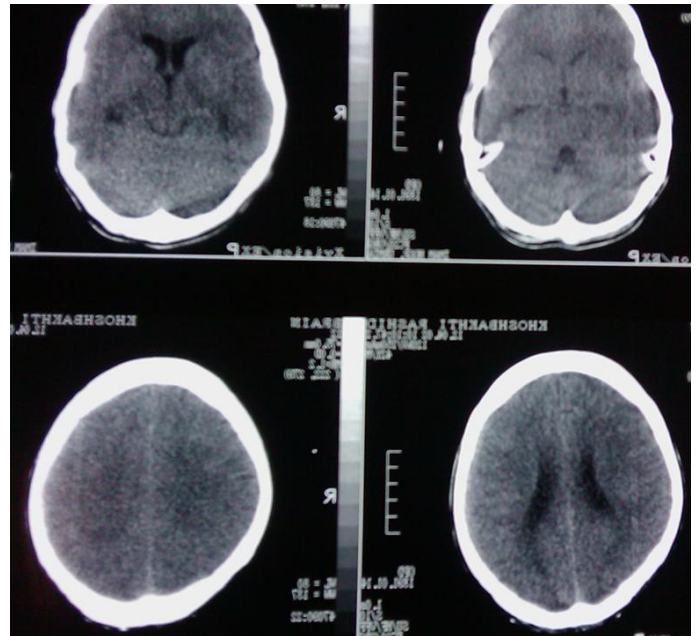


Figure- 4. Showing normal brain CT.

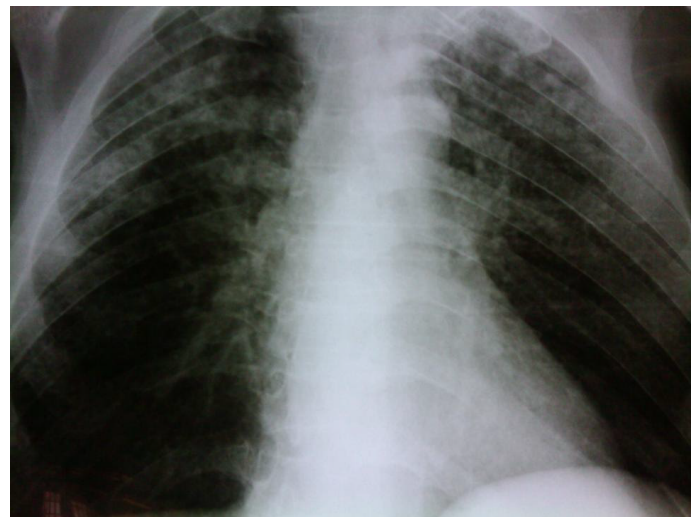


Figure- 5. Chest X-ray showed bilateral diffuse miliary nodular pattern involving both lung fields suggestive of tuberculosis.

Table- 1: Laboratory findings of patient on admission

Test	Result	Unit	Normal ranges
ESR	6	mm/hr	0- 15
PT	13	Secound	11- 13
PTT	35	Secound	26- 39
BS	168	mg/dl	80- 110
Urea	80	mg/dl	17- 43
Cr	0.74	mg/dl	0.7- 1.4
Na	141	mEq/L	136-145
K	4.6	mEq/L	3.5- 5
ANA	0.3	IU/ml	<1
Anti ds DNA	0.25	IU/ml	<0.9
AST	19	U/L	<50
ALT	28	U/L	<50
Total Bilirubin	0.58	mg/dl	0.1- 1.2
Direct Bilirubin	0.2	mg/dl	<0.2
Alkaline Phosphatase	391	U/L	80- 306
LDH	436	U/L	Up to 480

Discussion

The term "immunocompromised host" defines a patient who is at risk for life-threatening infection because of a congenital or acquired defect of the immune system.(5) Over the recent decades, the numbers of the immunocompromised hosts have increased largely, which shows increased use of immunosuppressive drugs for therapeutic and prophylactic aims.(6, 7) Tuberculosis remains a major public health problem in the world, because of poverty, overcrowding and HIV/AIDS infection. The association between tuberculosis and cancer has been showed for many years.(7) The incidence of TB may be especially high in patients with hematologic malignancies because of the T-cell immunodeficiency caused by the underlying disease and/or its treatment. Hairy cell leukemia is a rare indolent lymphoproliferative malignancy characterized by splenomegaly and pancytopenia. Patients with hairy cell leukemia are susceptible to acquired and life threatening infections particularly mycobacterial infections (8, 9). The prevalence of tuberculosis in patients with hematologic malignancies has been reported to be between 0.72% and 2.6%.(6, 10) The diagnosis of tuberculosis may be difficult due to the symptoms of tuberculosis can overlap those of the hematologic dyscrasia (such as lymphoma), and the immunodeficiency may affect the clinical symptoms of tuberculosis and mortality rate of tuberculosis in these group may be higher, because of delay in diagnosis.(11)

In presented case with definite diagnosis of Hairy cell leukemia from 8 months ago with received treatment, beginning of non-specific symptoms & signs (Fever, malaise, loss of appetite, cough and night sweat) from 3 months ago and gradually progression of CNS symptoms & sign (headache, restlessness and loss of consciousness from 4 weeks ago and in diagnostic work up milliary pattern in CXR and chest HRCT scan and abnormal CSF and CSF AFB smear+ ,disseminated tuberculosis with pulmonary and meningeal involvement was documented and anti-TB therapy was began.

Due to endemicity of tuberculosis in Iran beginning of non-specific symptom and sings such as prolonged fever, pulmonary and meningeal involvement especially with underlying hematologic malignancy, tuberculosis should be thought in differential diagnosis.

Acknowledgement

The Authors express their appreciation to Dr Ilkhanizadeh B, the associate professor of

pathology in Urmia University of Medical Sciences for outstanding pathology reports and, Dr Moradi A, the resident of pathology in Urmia University of Medical Sciences who photographed the pathology slides of this patient.

References

1. GreverMR. How I treathairy cell leukemia. *Blood* 2010; 115 (1): 21- 8.
2. Bouza E, Burgaleta C, Golde DW. Infections in hairy-cell leukemia. *Blood* 1978; 51: 851- 9.
3. Anazi KA, Jasser AM, Evans DAP. Infections caused by mycobacterium tuberculosis in patients with hematological disorders and in recipients of hematopoieticstem cell transplant. Doi: 10.1186/1476- 0711-6-16.
4. Stewart DJ, Bodey GP. Infections in Hairy Cell Leukemia (leukemic Reticuloendotheliosis). *Cancer* 1981; 47: 801- 5.
5. Donnelly JP, De Pauw BE. Infections in the Immunocomprpmised Host. In: Mandell, Douglas, and Bennetts Principles and Practice of Infectious Diseases. Sixth edition. Philadelphia. Elsevier. 2005. P. 3421-3424.
6. De PauwBE, Verweij PE. Infections in Patients with Hematologic Malignancies. Mandell, Douglas, and Bennetts Principles and Practice of Infectious Diseases. Sixth edition. Philadelphia. Elsevier. 2005. P. 3434- 3437.
7. Raviglione MC, O'Brien RJ. Tuberculosis. Fauci. Braunwald. et al. *Harrisons Principles of Internal Medicine*. 17th Edition. Mc Grow hill. P.1010-1013.
8. Wu CY, Hu HY, Pu CY, Hung N, Shen HC, Li CP, Chou YJ. Aerodigestive tract, lung and hematological cancers are risk factors for tuberculosis: an 8 year population based study. *Int Tuberc Lung Dis*. 2011; 15(1): 125- 30.
9. Chen CY, Sheng WH, Cheng A, Tsay W, Huang SY, Tang JL, Chen YC, Wang JY, Tien HF, Chang SC. Clinical characteristics and outcomes of Mycobacterium tuberculosis disease in adult patients with hematological malignancies. *BMC Infect Dis*. 2011; 11:324.
10. Stefan DC, Kruis AL, Schaaf HS, Wessels G. Tuberculosis in oncology patients. *Ann Trop Paediatr*. 2008; 28(2):111-6.
11. Omoti CE, Olu Eddo AN, Nwannadi AL. Co-existence on TB and adult haematological cancers in Benin City, Nigeria. *Trop Doct*. 2009; 39(4):205-7.